

Original Research Article

Terminal branching of internal laryngeal nerve: a cadaveric study

Vijayalakshmi Madhavapillai^{1*}, Karthik Ganesh Mohanraj²

¹Department of Anatomy, Melmaruvathur Adhiparasakthi Institute of Medical Sciences and Research, Melmaruvathur, Tamil Nadu, India

²Department of Anatomy, Saveetha Dental College and Hospitals, Saveetha Institute of Medical and Technical Sciences (SIMATS), Saveetha University, Chennai, Tamil Nadu, India.

Received: 29 July 2021

Revised: 07 August 2021

Accepted: 15 August 2021

*Correspondence:

Dr. Vijayalakshmi Madhavapillai,

E-mail: doctorvijayalakshmi38@gmail.com

Copyright: © the author(s), publisher and licensee Medip Academy. This is an open-access article distributed under the terms of the Creative Commons Attribution Non-Commercial License, which permits unrestricted non-commercial use, distribution, and reproduction in any medium, provided the original work is properly cited.

ABSTRACT

Background: Innervation of larynx is much more complicated than previously been thought. Laryngopharynx is the common gateway for many specialists like oral surgeons, ENT surgeons, anaesthetists, UGI endoscopists and bronchoscopists. The sub-mucosal neural network can be anaesthetised by topical application or injection of local anaesthetics. In this study destination of the internal laryngeal nerve and its penetration into the intrinsic muscles of larynx are analysed.

Methods: A total of 40 en bloc cadaveric specimens were investigated in the department of anatomy, Madras Medical College, Chennai and from Melmaruvathur Adhiparasakthi Institute of Medical Sciences and Research, Kanchipuram. Conventional anatomy dissection method was used in the identification of internal laryngeal branch of superior laryngeal nerve and its branches.

Results: Irrespective of the number of divisions at the point of entry into thyrohyoid membrane, 4 branches were constantly traceable. The branches were traced by 2 approaches- (A) those supplying the mucus membrane- (i) to the junction of aryepiglottic fold and lateral border of epiglottis; (ii) to the posterior surface of interarytenoideus; (iii) to the posterior surface of posterior arytenoideus; and (iv) descending to apex of the pyriform fossa behind cricothyroid junction; (B) penetration into intrinsic muscles- (i) a branch terminated after entering interarytenoideus; and (ii) another terminated after entering the posterior cricoarytenoideus muscle.

Conclusions: The knowledge of variation into branches and area of supply of internal laryngeal nerve is essential for anatomists and clinicians. It is not a nerve to be neglected as the knowledge of its branches is very much essential for the surgeons operating in this area of air and food passage.

Keywords: Laryngopharynx, Internal laryngeal nerve, Terminal branches, Intrinsic muscles of larynx, Endoscopy

INTRODUCTION

The pharynx is divided anatomically into nasopharynx, oropharynx and laryngopharynx. The laryngopharynx is more significant than other part of pharynx as it serves as common gateway for many surgical specialists such as oral surgeons, ENT surgeons, anaesthetist, upper gastrointestinal endoscopists and bronchoscopists. It becomes important to unravel the mysteries of the 'Treasure Island' the 'Pyriform Fossa'.¹ The nerve situated in close association with this region is the internal

laryngeal nerve (ILN). The ILN is the only cranial nerve that can be felt and seen through the mucosa overlying it here. The sub-mucosal network can be anaesthetised by topical application or injection of local anaesthetics.² Hence it becomes important to acquire the knowledge of its branches, their termination and its relation to intrinsic muscles of larynx. The vagus is the 10th cranial nerve which gives parasympathetic fibres to thoracic and abdominal viscera. It also innervates few skeletal muscles of larynx and pharynx. The right and left vagi nerves give rise to right and left superior laryngeal nerve respectively.

The superior laryngeal nerve in turn divides into internal and external laryngeal nerves (ILN) in the neck. The ILN supplies sensory fibres to the mucosa covering the larynx. The external laryngeal nerve supplies motor fibres to the cricothyroid muscle and also communicates with the recurrent laryngeal nerve occasionally.³

The ILN descends along with the superior laryngeal artery, pierces the thyrohyoid membrane and sends sensory branches to the laryngeal mucosa.⁴ Regarding the branches of ILN and its course, distribution and surgical implications have been studied widely and deliberated broadly for many years in the gross anatomy, microsurgical anatomy and clinical anatomy literatures.⁵ This nerve not only supplies the motor fibres to few intrinsic muscles of larynx but also contains sensory fibres which protect the lower respiratory tract by reflex cough.⁶ The injury to this nerve will produce recurrent bouts of cough and Gastro Esophageal Reflux Disorder (GERD).⁷ Vagus nerve give rise to superior laryngeal nerve which in turn gives the first branch the ILN. It takes a medial diversion with superior thyroid artery. It pierces the thyrohyoid membrane along with the laryngeal branch of superior thyroid artery.⁸ It divides into many branches not only supplying the mucosa of upper part of larynx and also the vallecula of the tongue including the pyriform fossa. It communicates with recurrent laryngeal nerve occasionally.⁹ The variations in the branching of ILN have also been reported previously in our earlier study.¹⁰

The objective of this study was to analyse the destination of internal laryngeal nerve and its penetration into the intrinsic muscles of larynx in cadaveric specimens.

METHODS

This was an observational cross-sectional cadaveric study. The study was conducted in the Institute of Anatomy, Madras Medical College, Chennai and from Melmaruvathur Adhiparasakthi Institute of Medical Sciences and Research, Tamil Nadu, India. The study was conducted during the period from September 2019 to December 2019. Total of 40 en bloc cadaveric specimens were investigated for this study. The specimens with good integrity of muscles and neurovascular structures covered with fascia in neck were included in the study. Specimens with torn muscles and nerves in the neck region, deeply dissected neck region with cut-out neck muscles and neurovascular structures related to it were excluded from this study.

Conventional dissection method was used in identification of branches of superior laryngeal nerve and specifically its internal laryngeal branch. The dissection procedure was as follows: a midline skin incision was made from chin to jugular notch and the skin flap was reflected. Platysma was reflected upwards. A transverse incision was made through the layers of deep cervical fascia above the sternum and the incision was extended 4cm superiorly along the anterior border of sternocleidomastoid muscle. This fascia

was reflected. The infrahyoid muscles were identified and the sternocleidomastoid and superior belly of omohyoid muscle were displaced laterally. The sternothyroid muscle was cut near its lower end and turned upwardly to the thyroid cartilage with its nerve supply. The attachments of the inferior constrictor muscles to the thyroid and cricoid and also to the fascial arch crossing the cricothyroid muscle were identified. This muscle was cut horizontally through fibrous arch and the divided parts of the inferior constrictor were reflected.

The internal laryngeal nerve in the thyrohyoid interval was found. Post-erosuperiorly, deep to the carotid artery the superior laryngeal branch of the vagus was traced. The slender external laryngeal nerve was followed and traced downwards deep to superior thyroid artery. The fasciae covering the thyroid gland are removed and the vessels related to it are exposed. The lower part of the thyroid gland was lifted and the lateral surfaces of trachea and oesophagus are exposed with the recurrent laryngeal nerve in the groove between them. The upper part of the thyroid gland was pulled laterally and the external branch of the superior laryngeal nerve to cricothyroid muscle was traced carefully.

The fat, lymph node and the carotid sheath from the common carotid artery and the internal jugular vein were removed. The structures present in it were separated and the vagus nerve was traced. The vagus nerve was exposed by clearing off the connective tissues covering it and the right recurrent laryngeal nerve arising from it was found as it crosses the subclavian artery. The thyrohyoid muscle was cut through and the thyrohyoid membrane was exposed with its vessels and nerves piercing it. The recurrent laryngeal nerve entering the larynx deep to the inferior constrictor muscle was traced.

Hydraulic saline injection technique and acid corrosion techniques were also used in about 5 specimens to visualize the structures clearly. Institutional Human Ethics Committee approval is not applicable for this study as this was a cadaveric study.

RESULTS

Cadaver specimen presenting deep dissection of neck displaying vagus nerve and its ILN branch with its adjacent structure is shown in Figure 1. It has been found in this study that irrespective of the number of divisions at the point of entry, 4 branches were constantly traceable. Those were found (A) supplying the mucus membrane (B) penetrating the intrinsic muscles. (A) Branches that supply the mucus membrane were found to have 4 different destinations as follows: (i) to the junction of aryepiglottic fold along lateral border of epiglottis supplying the mucosa of anterior and posterior surfaces of epiglottis and vallecula; (ii) to the posterior surface of arytenoideus supplying the mucosa over arytenoids and twigs entering the interarytenoideus muscle; (iii) to the posterior surface of posterior arytenoideus muscle, supplying the mucosa

and mucosal glands of that region. It could not be traced beyond that muscle; and (iv) descending branch to the apex of pyriform fossa behind the cricothyroid joint. slender inconstant branches were also seen in this, such as- (a) running to vallecula across the lateral glossoepiglottic fold; and (b) parallel nerve filaments reaching the junction of aryepiglottic fold with anterior and lateral surface of epiglottis, radially from the greater horn of hyoid bone; (B) Penetration into intrinsic muscles of larynx, such as: (i) a branch terminated after entering the interarytenoideus; and (ii) another terminated after entering the posterior cricoarytenoideus muscle.

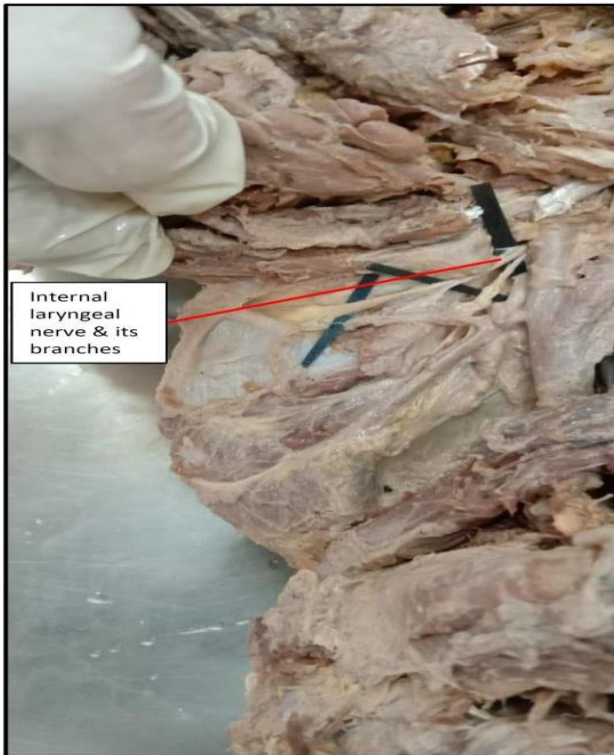


Figure 1: Cadaver specimen showing the deep dissection of neck displaying the internal laryngeal nerve and its branches in the larynx.

DISCUSSION

The details of branching of internal laryngeal nerve supplying the mucosa of pharynx and larynx is a cause of concern in treating the pathology of this area. However, the present study throws some light on the details of the branches of the nerve supplying various aspects of this area. Four groups of branches as mentioned below were observed. 1st group: supplied anterior and posterior surfaces of epiglottic vallecula. 2nd group: Supplied mucus membrane over back of arytenoid cartilage. 3rd group: supplied mucus membrane on the back of posterior cricoarytenoid. 4th group: descended down towards the apex of pyriform fossa and supplied that region- (i) inconstant branches ran cross the lateral glossoepiglottic fold; and (ii) parallel nerve filament reached the junction

of aryepiglottic fold along lateral border of epiglottis, from above the greater horn of hyoid bone.

TFM Dilworth (1921) in his observation of 33 specimen studied, mentions about 2 branches of internal laryngeal nerve A1 and A2.¹¹ His observation were summarised as: (A) group A1: divided into 4 branches of internal laryngeal nerve which is divided into four further branches- (i) supplied the mucus membrane of lateral wall of the pharynx and lateral to glossoepiglottic fold; (ii) supplied the vallecula; (iii) supplied both sides of epiglottis and vestibule; and (iv) supplied the false vocal cord and the region above it; (B) group A2: The descending division of internal laryngeal nerve divided into two branches- (i) supplied the mucus membrane and the mucus glands in the posterior surface of arytenoids cartilage; and (ii) pierced the interarytenoideus muscle and supplied the laryngeal mucus membrane deep to it.

Gray et al also mentions about an upper branch supplying the pharynx, epiglottic, vallecula and vestibule of the larynx and the lower branch supplied the aryepiglottic fold and the back of arytenoids cartilage.¹²

Montford et al described 3 groups of branches, the upper group supplying the epiglottis on the sides and anterior wall of vallecula, the middle group supplying the aryepiglottic folds and the inferior group supplying the mucus membrane up to the false vocal folds.¹³ The common innervations of pharynx, vallecula and laryngeal inlet explain its important afferent role in swallowing and cough reflex. Irregular unsmashed foreign bodies getting impacted in airway and oesophagus, in case of elderly persons with blunting of ILN sensation (as in alcoholic neuropathy) and senile degenerative changes is due to the foreign body escaping the protective reflexes in this common passage.¹⁴

In the same way the nocturnal cough due to postnasal dribbling is due to afferent from this common passage. It should not be suppressed as it may trickle down to produce persistent lower respiratory tract infection. The primary cause for the nocturnal cough should be found and eliminated rather than suppressing the afferent reflexes.¹⁵ Penetration of ILN into the intrinsic muscles of larynx has been previously revealed by Exner et al in his laryngeal dissection of new born. The intrinsic muscles are being supplied by both ILN and RLN.¹⁶ Dilworth et al mentioned that in 31 out of 33 specimen the ILN entered the interarytenoideus muscles and not the posterior cricoarytenoideus. Berlin et al and Lahey et al stated that ILN always entered interarytenoideus muscle.¹⁷ Hollinshed et al and Gray et al also revealed about the ILN entering interarytenoideus.¹⁸ Keene et al reported finding neuromuscular spindles and stretch receptors in all intrinsic muscles of human larynx.¹⁹ So, it was unclear whether those branches were motor (or) proprioceptive afferent or simply penetrated the muscle to supply the laryngeal mucosa as stated by Hollinshed (1968).

Limitations

This study was done in cadaveric specimens with a smaller number of samples obtained from South Indian population. Further branching and variation patterns of the ILN can be explored in other cadaveric specimens of different geographical regions.

CONCLUSION

It has been found that innervation of embryological fourth and sixth arch derivatives by ILN is an anatomical, functional as well as pathological syncytium. Hence, they should be considered as a single unit in hand for any intervention in this region.

Funding: No funding sources

Conflict of interest: None declared

Ethical approval: The study was approved by the Institutional Ethics Committee

REFERENCES

1. Thale A, Jungmann K, Paulsen F. Morphological studies of the optic canal. *Orbit*. 2002;21(2):131-7.
2. Melamed H, Harris MB, Awasthi D. Anatomic considerations of superior laryngeal nerve during anterior cervical spine procedures. *Spine*. 2002;27(4):83-6.
3. Ramaswamy S. A ganglion on the Internal Laryngeal Nerve – A Preliminary Report. *J Anat Soc Ind*. 1963;12:1.
4. Ambalavanar R, Purcell L, Miranda M, Evans F, Ludlow CL. Selective suppression of late laryngeal adductor responses by N-methyl-D-aspartate receptor blockade in the cat. *J Neurophysiol*. 2002;87(3):1252-62.
5. Meester TR, Skinner DB, Evans RH, Benson DW. Local nerve block anesthesia for peroral endoscopy. *Ann Thorac Surg*. 1977;24(3):278-83.
6. Durham CF, Harrison TS. The Surgical Anatomy of The Superior Laryngeal Nerve. *Surg Gynecol Obstet*. 1964;118:38-44.
7. Furlan JC, Brandao LG, Ferraz AR, Rodrigues AJ. Surgical anatomy of the extralaryngeal aspect of the superior laryngeal nerve. *Arch Otolaryngol Head Neck Surg*. 2003;129(1):79-82.
8. Gotta AW, Sullivan CA. Anaesthesia of the upper airway using topical anaesthetic and superior laryngeal nerve block. *Br J Anaesth*. 1981;53(10):1055-8.
9. Johnson J. Effect Of Superior Laryngeal Nerves On Tracheal Mucus: An Experimental Study On The Relationship. *Ann Surg*. 1935;101(1):494-9.
10. Vijayalakshmi M, Karthik GM, Thenmozhi MS. Branches of internal laryngeal nerve – A cadaveric study. *Drug Invention Today*. 2019;11(2):160-3.
11. Dilworth TF. The Nerves of the Human Larynx. *J Anat*. 1921;56(1):48-52.
12. Standring S. *Gray's Anatomy- The Anatomical Basis of Clinical Practice*. 38th ed. London: Churchill Livingstone; 2000: 423-425.
13. Monfared A, Kim D, Jaikumar S, Gorti G, Kam A. Microsurgical anatomy of the superior and recurrent laryngeal nerves. *Neurosurgery*. 2001;49(4):925-32.
14. Reed AP. Successful transoesophageal echocardiography in an unsedated critically ill patient with superior laryngeal nerve block. *Am Heart J*. 1991;122:1472-4.
15. Vogel PH. The innervation of the larynx of man and the dog. *Am J Anat*. 1952;90:427.
16. Exner FX. *Headquarters of the K. Akad. Der Wiss*. 1925;89:63.
17. Berlin DD, Lahey, FH. Dissection of recurrent and superior laryngeal nerves. *Surg Gynec Obst*. 1929;49:102.
18. Hollinshead WH. *Anatomy for Surgeons. The Head & Neck*. 1st ed. New York, NY: Hoeber-Harper; 1954: 376-379.
19. Keene MF. Muscle spindles in human laryngeal muscles. *J Anat*. 1961;95(1):25-9.

Cite this article as: Madhavapillai V, Mohanraj KG. Terminal branching of internal laryngeal nerve: a cadaveric study. *Int J Res Med Sci* 2021;9:2624-7.