

Case Report

Unani management of vesical calculus-a case report

Mohammad Shamim Khan^{1*}, Qamrul Hasan Lari²

¹Department of Unani Medicine, Government Unani Dispensary, Kota North, Rajasthan, India

²Department of Kulliyat, State Unani Medical College and Hospital, Paryagraj, Uttar Pradesh, India

Received: 05 February 2021

Accepted: 08 August 2021

*Correspondence:

Dr. Mohammad Shamim Khan,

E-mail: drshamimmd@yahoo.co.in

Copyright: © the author(s), publisher and licensee Medip Academy. This is an open-access article distributed under the terms of the Creative Commons Attribution Non-Commercial License, which permits unrestricted non-commercial use, distribution, and reproduction in any medium, provided the original work is properly cited.

ABSTRACT

Vesical calculus (*Hisat-e-Masanah*) accounts approximately 5% of all urinary tract stones. It has bimodal peaks age of incidence at 3 years in children in developing countries, and 60 years in adulthood. Despite advance technology of lithotripsy, the management of vesical calculus in children remains a challenge due to difficulty in passing of stone fragments and adverse effect of surgery. Hence alternative and safe treatment like Unani system of medicine can be adopted to avoid surgical procedure. The present paper deals with a case study in which a 10 years old male child patient suffered from a single vesical calculus was treated with Unani pharmacopeial medicine; *Qurs Kaknaj* (2 tablets), *Qurs Kushta Hajrul Yahood* (1 tablet) and *Sharbat Buzoori Motadil* (10 ml syrup) twice a day as oral administration, with the aim to evaluate the efficacy of drugs and to avoid surgery. Patient has shown excellent and significant result as 8×5 mm size of a stone flushed out at 3rd day of treatment without any operation.

Keywords: Diuretic, *Hisat-e-Masana*, Lithotriptic, Unani medicine, Vesical calculus

INTRODUCTION

Urinary bladder stone known as vesical calculus (*Hisat-e-Masanah*) accounts approximately 5% of all urinary tract stones (*Hisat-e-Majra-e-Bauliyah*).¹ It is considered as endemic in developing regions such as Southeast Asia and India.² Its prevalence is higher in hot and dry climate like mountains, desert or tropical areas. Its incidence is higher in males with a reported male: female ratio between 10:1 and 4:1.³ The age distribution has bimodal peaks of incidence at 3 years in children in developing countries, and 60 years in adulthood.^{3,4} Etiopathologically, it can be classified as primary or endemic type, secondary and migratory type.⁵ Primary vesical calculus typically occurs in children in areas with a diet deficient in animal protein, poor hydration and recurrent diarrhea.⁶ The secondary type usually occurs in adults and caused by the bladder outlet obstruction (BOO), neurogenic bladder dysfunction, chronic bacteriuria, foreign bodies including catheters, bladder diverticula

and bladder augmentation or urinary diversion.⁷ Migratory bladder stones are those who have passed from the upper urinary tract where they formed; patients are more likely to have a renal calculus history and other risk factors for nephrolithiasis.⁸ Primary and secondary bladder stones are unlikely to pass spontaneously; thus, surgical treatment of such stones is usually manifested.⁹ Despite minimally invasive technique extra corporeal shock wave lithotripsy is an easy method to treat urinary bladder stones, but in children because of difficulty in passing of stone fragments and adverse effect of surgery the management of vesical calculus remains a challenge. Hence alternative and safe treatment like Unani system of medicine can be adopted to avoid surgical procedure. The recommended line of Unani treatment for expelling out the stone includes use of plenty of fluids, *Mufattit-e-Hisat* (litholytic/lithotryptic), *Mudirr-e-Baul* (diuretic), and *Dafe'y-e-Tashannuj* (antispasmodic) potentials Unani drug.¹⁰

CASE REPORT

A 10 years old male child suffering from urinary bladder stone, visited to government Unani dispensary, Bheemganj Mandi, Kota North, department of Unani medicine Rajasthan, India, for treatment. His chief complaint was pain in suprapubic region, dysuria, and increased frequency of urine, partially retention of urine and pulling of the penis since last 4 days. His urine volume was inadequate. His blood group was O positive. He had *Damvi Mizaj* (sanguinous temperament) in nature. He was suffered from thalassemia, detected when he was just 7 months of age. Because of this inherited blood disorder, he had transfused blood fortnightly. He was preferred very salty and spicy food. He used to eat vegetable and meat, frequently fish at alternate day. He used to drink 4-6 glasses of water and 3-4 cups of tea daily. The diagnosis was confirmed by plain X-ray of abdomen for kidney, ureter, bladder (KUB). Radiological Finding was suggestive of a single stone at neck of urinary bladder.

The patient has been prescribed to take two pills of *Qurs Kaknaj*, one pill of *Qurs Kushta Hajrul Yahood*, and 10 ml of *Sharbat Buzoori Motadil* with plain water twice a day on empty stomach orally, along with plenty of fluid, and advised him to avoid oxalate containing diets like tomato, palak, chaulayi, almla, chickoo, cashew nuts, cucumber, and uric acid/purine containing diets like cauliflower, pumpkin, mushroom, brinjal. Other concomitant therapy was restricted during treatment. All prescribed Unani compound drugs are pharmacopeial, marketed from GMP certified company Hamdard and prepared according to *Bayaz-e-Kabeer* volume 2.^{11,12}

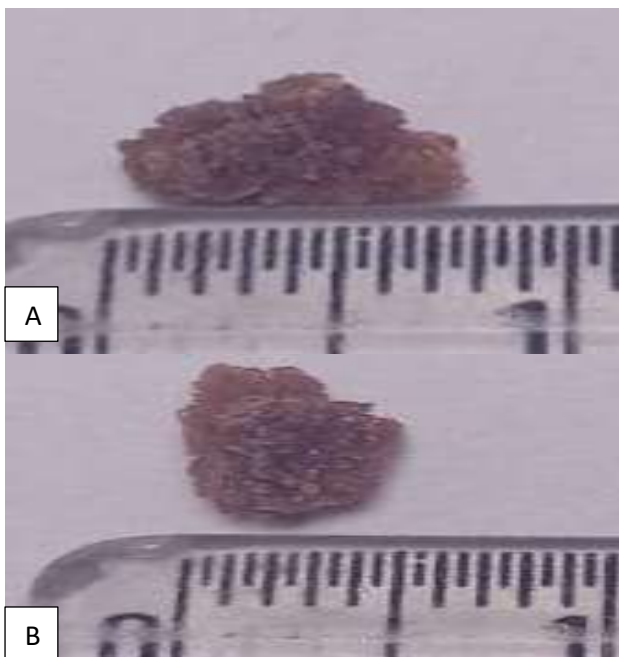


Figure 1 (A and B): Flushed out bladder stone measuring 8 mm in length. Flushed out bladder stone measuring 5 mm in width.

DISCUSSION

The clinical improvement was excellent and significant as 8×5 mm size of a single stone flushed out at 3rd day of treatment (Figure 1A and B). All Unani pharmacopeial drugs were found to be safe and effective. The possible beneficial effects of these drugs can be exhibited due to diuretic, litholytic and lithotriptic, antispasmodic, and anti-inflammatory activities in their ingredients.

Qurs Kaknaj has been described as diuretic (*Mudirr-e-baul*), litholytic (*Mufattit-e-hisat*), lithotriptic (*Mukhrij-e-hisat*), renal and urinary bladder wound healer.¹³ Its chief constituent *Habb-e-kaknaj* (*Physalis alkekengi* fruit) is commonly used since ancient times in Unani Medicine as diuretic, lithotriptic, anti-inflammatory and nephroprotective.¹⁴ It is investigated the main phytochemical constituents of *Physalisalkekengi* are alkaloids (Tropanes), flavonoids, sterols, fatty-acids and amino acids.¹⁵ The flavonoids are reported to have a role in analgesic action by targeting the prostaglandins and alkaloids are known for their ability to inhibit pain perception.¹⁶ It also possesses antispasmodic activity mainly via calcium influx blockade, partially through blocking β -adrenoceptors and nitric oxide synthesis.¹⁷

Qurs Kushata hajrul Yahood is useful as a diuretic and a lithotriptic. It is specially given in pathological conditions of the urinary tract such as retention of urine, gonorrhoea and urethral ulcer.¹³ *Hajrul Yahood Bhasma* (*Kushta*) is a rich source of magnesium hydroxide [$Mg(OH)_2$] which react with calcium oxalate stone and forms Magnesium oxalate soluble complex which helps disintegration of large calculi into the smaller particles.¹⁸ Its other component *Aab-e-Turab* (*Rafanus sativus* root juice) demonstrated for its anti-urolithiatic and diuretic activities.¹⁹

Sharbat Buzoori Moatadil mainly indicated as diuretic (*Mudirr-e-baul*).¹³ It is claimed to have an anti-urolithiatic agent. It can prevent the recurrence stone formation by forming soluble calcium compound with citric acid. It also has alkalizing effect.²⁰ Its chief ingredient *Bekh-e-Kasni* (*Cichorium intybus* root) possesses anti-inflammatory and nephroprotective activities.²¹ *Tukhm-e-kheera* (*Cucumis sativus*) shown to have anti-urolithiatic activity by hastening the process of dissolving the stones in kidney.²²

Khan et al demonstrated that *Qurs Kaknaj*, *Qurs Kushta Hajrul Yahood*, *Arq Kasni* and *Sharbat Buzoori Moatadil* orally are safe and effective in a 33 years old male patient associated with a single calculus of 16 mm at mid pole of right kidney and multiple calculi of 7-11 mm at calyces of left kidney, as patient got free from stone after 60 days of treatment.²³ In another study Khan determined that *Qurs Kaknaj*, *Kushta Hajrul Yahood*, *Jawarish Zaruni*, *Sharbat Buzoori Motadil* and *Sharbat Aloo Balu* as oral administration are safe and more effective in a 25 years

old male patient of right ureteric stone of 8 mm size, as flushed out in three broken part at 6th day of treatment.²⁴

CONCLUSION

It can be concluded that pharmacopoeial Unani compound drugs; *Qurs Kaknaj*, *Qurs Kushta Hajrul Yahood* and *Sharbat Buzoori Moatadil* are safe and highly effective in the treatment of vesical calculus (*Hisat-e-Masana*). These drugs have potential to facilitate stone expulsion faster with significant improvement in associated symptoms. Hence Unani formulations could be most useful in vesical calculus (*Hisat-e-Masana*) as medicinal treatment option to avoid surgery and its complications. Further scientific studies are required to be carried out at large sample size.

Funding: No funding sources

Conflict of interest: None declared

Ethical approval: Not required

REFERENCES

- Schwartz BF, Stoller ML. The vesical calculus. Urol Clin North Am. 2000;27(2):333-46.
- Johnson O. Vesical calculus in Ethiopian children. Ethiop Med J. 1995;33(1):31-5.
- Halstead SB. Epidemiology of bladder stone of children: precipitating events. Urolithiasis. 2016;44(2):101-8.
- Takasaki E, Suzuki T, Honda M, Imai T, Maeda S, Hosoya Y. Chemical compositions of 300 lower urinary tract calculi and associated disorders in the urinary tract. Urol Int. 1995;54(2):89-94.
- Philippou P, Moraitis K, Masood J, Junaid I, Buchholz N. The management of bladder lithiasis in the modern era of endourology. Urology. 2012;79(5):980-6.
- Lal B, Paryani JP, Memon SR. Childhood bladder stones-An endemic disease of developing countries. J Ayub Med Coll Abbottabad. 2015;27(1):17-21.
- Douenias R, Rich M, Badlani G, Mazor D, Smith A. Predisposing factors in bladder calculi: Review of 100 cases. Urology. 1991;37(3):240-3.
- Childs MA, Mynderse LA, Rangel LJ, Wilson TM, Lingeman JE, Krambeck AE. Pathogenesis of bladder calculi in the presence of urinary stasis. J Urol. 2013;189(4):1347-51.
- Turk C, Skolarikos A, Donaldson JF, Neisius A, Petrik A, Seitz C et al. Eur Urol. 2019;76(3):352-67.
- Khan MS, Lari QH, Khan MA. Unani Concept of Nephrolithiasis (*Hisat-e-Kulyah*) and Its management-An Overview. WJPMR. 2016;2(5):247-52.
- Kabeeruddin HM. Beyaz-e-Kabeer. 2nd vol. Haiderabad Decan: Hikmat Book Depo. 2004.
- Anonymous. Disease and Treatment. New Delhi: Hamdard (waqf) Laboratories (India). 2009.
- Zill-ur-Rahman HS. Kitab-ul-Murakkabat. Aligarh: Lithocolour Printers. 1980.
- Ghani MN. Khazanat-ul-Advia. 3rd vol. Lucknow: Munshi Naval Kishore. 1920.
- Sanchooli N. Antidiabetic Properties of Physalis alkekengi Extract in Alloxan-Induced Diabetic Rats. Res J Pha Biol and Chem Sci. 2011;2:168-73.
- Ibironke GF, Ajiboye KI. Studies on the anti-inflammatory and analgesic properties of *Chenopodium ambrosioides* leaf extract in rats. Int J of Pharmacol. 2007;3:111-5.
- Mohammad K, Gharib N, Maryam M, Zahra G, Naseri D. Antispasmodic effect of Physalisalkekengi fruit extract on rat uterus. Iran J Reprod Med. 2008;6(4):193-8.
- Johansson G, Backman U, Danielson BG, Fellström B, Ljunghall S, Wikström B. Effects of Magnesium Hydroxide in Renal Stone Disease. J Amer Col Nutrition. 1982;1(2):179-85.
- Vargas R, Perez RM, Perez S, Zavala MA, Perez C. Antiuroliithiatic activity of *Raphanussativus* aqueous extract on rats. J Ethnopharmacol. 1999;68(1-3):335-8.
- Aziz I, Ismail A, Zulkifle M, Ansari AH. Effects of *Sharbat Buzuri Motadil* on Citrate Excretion. Ind J Trad Knowledge. 2011;10(3):498-501.
- Shafaq N, Tabassum M. Ameliorative effect of ethanolic extract of cichoriumintybus on Cisplatin-Induced Nephrotoxicity in Rats. Pak J sci Indus Res. 2009;52(4):208-16.
- Janapareddi K, Ellandala R, Pulluru M, Dundigalla SK. Anti Urolithiatic Activity of Cucumis sativus. Int J Pharma Scree Methods. 2013;3(2):46-52.
- Khan MS, Khan W. Therapeutic Evaluation of Unani Pharmacopoeial Formulations for *Hisat-e-Kulyah* (Nephrolithiasis). Hamdard Medicus. 2017;60(1):82-6.
- Khan MS. Effect of Unani Formulations on Ureteric Calculus (*Hisat-e-Halib*)-A Case Report. EJBPS. 2019;6(1):649-52.

Cite this article as: Khan MS, Lari QH. Unani management of vesical calculus-a case report. Int J Res Med Sci 2021;9:3200-2.