

Research Article

Morphometric analysis of glenoid cavity of dry scapulae and its role in shoulder prosthesis

Md. Jawed Akhtar¹, Bipin Kumar², Nafees Fatima^{1*}, Vinod Kumar¹

¹Department of Anatomy, Indira Gandhi Institute of Medical Sciences, Patna, Bihar, India

²Department of Physiology, Lord Buddha Koshi Medical College and Hospital, Saharsa, Bihar, India

Received: 09 May 2016

Accepted: 04 June 2016

*Correspondence:

Dr. Nafees Fatima,

E-mail: anat.igims@gmail.com

Copyright: © the author(s), publisher and licensee Medip Academy. This is an open-access article distributed under the terms of the Creative Commons Attribution Non-Commercial License, which permits unrestricted non-commercial use, distribution, and reproduction in any medium, provided the original work is properly cited.

ABSTRACT

Background: The lateral angle of scapula becomes truncated and broadened and form the glenoid cavity which shows variable morphology. There is a notch present on its anterosuperior part which gives its different shape. When this glenoid notch is indistinct its shape is piriform, when it is distinct it looks like inverted comma shape and when it is absent its oval shape. The shoulder joint is one among the most commonly dislocated joints in the body. The fracture of glenoid with dislocations is very common in the trauma. The detail knowledge about variation in anatomy of glenoid cavity like different shape, size and dimensions are important during designing and fitting of glenoid component for total shoulder arthroplasty. The objective of present study was to obtain anthropometric data of scapulae and the glenoid cavity specifically the diameters and various shape of glenoid belongs to population of Bihar and compare it to findings from other races of the world.

Methods: The present study was a cross sectional study which has been carried out on 228 undamaged dry adult human scapulae in which 126 belongs to right side and 102 belongs to left side. The age and gender of the bones used in the study was not predetermined.

Results: The most common shape of glenoid cavity recorded in the present study was pear shape (50.44%) followed by inverted comma shape (35.96%). The least common shape was oval (13.6%). The mean length of scapula was observed as 135.07 ± 14.23 mm, the mean breadth of scapula was 97.55 ± 9.63 mm, the mean supero inferior glenoid diameter was 35.80 ± 3.14 mm, the mean antero posterior glenoid diameter 1 was 23.63 ± 2.50 mm, and the mean antero posterior glenoid diameter 2 was 16.17 ± 2.24 mm and mean glenoid cavity index was 66.40 ± 8.14 %. In all the above measurements bilateral differences was not statistically significant.

Conclusions: The knowledge about the different shape and dimensions of glenoid are very important during designing and fitting of glenoid component for total shoulder arthroplasty. It is also helpful during evaluation of different pathological conditions like rotator cuff disease, osteochondral defects and Bankart lesion. Since the present study is conducted on a limited number of scapulae further cadaveric, radiological and clinical studies are indicated.

Keywords: Glenoid cavity, Glenoid cavity index, Glenoid notch, Shoulder prosthesis

INTRODUCTION

Scapula a bone of shoulder girdle is among the interesting bones of our body because of variations present in it. It is a flat triangular bone that lies on the posterolateral aspect of the chest wall over the second to the seventh rib. Its lateral angle becomes truncated and

broadened that bears the glenoid cavity which articulates with the head of the humerus in the shoulder joint. The glenoid cavity which is also known as the head of the scapula is connected to the plate like body by an anatomical neck which is most distinct at its dorsal and inferior aspects. When the arm is swing by the side of the body, the glenoid cavity is directed slightly upwards,

forwards and laterally and when the arm is raised above the head level it is directed almost straight upwards.¹ The glenoid cavity shows variable morphology. There is a notch present on its anterosuperior part i.e. on the anterior glenoid rim which gives its different shape. When this glenoid notch is indistinct its shape is piriform or pear or tear drop, when it is distinct it looks like inverted comma shape and when it is absent its oval shape.^{2,3}

The long axis of the glenoid cavity i.e. its vertical diameter is the longest and it is broader below than the above. The shoulder joint is one among the most commonly dislocated joints in the body. The fractures of glenoid with dislocations are very common in the trauma. The detail knowledge about variation of glenoid cavity is important for total shoulder arthroplasty. The different anatomical parameter of the glenoid cavity relevant to prosthesis design includes shape, size, height and width.

A number of cadaveric studies have been done by different authors and reported that when the glenoid notch is distinct on its anterior margin, the glenoid labrum is often not attached to the rim of glenoid cavity at the site of the notch.² This may be a predisposing factor of anterior dislocation of the shoulder joint. Various studies have been conducted on morphometry of the glenoid cavity in different parts of our country.

But, still no data are available on morphometry of the glenoid cavity of human dried scapulae in Bihar region hence the necessity of the present study arose. Objectives of the study were to obtain anthropometric data of scapulae and the glenoid cavity specifically the diameters and various shape of glenoid belongs to population of Bihar for clinical application in joint replacement surgeries, glenohumeral instability and rotator cuff tears management and compare it to findings from other races of the world.

METHODS

The present study is a cross sectional study which has been carried out on 228 undamaged dry adult human scapulae, which were collected from the different students of the 1st year MBBS and Department of Anatomy and Department of Forensic Medicine and Toxicology of Indira Gandhi Institute of Medical Sciences, Patna Medical College, Nalanda Medical College and Lord Buddha Koshi Medical College of Bihar state of India. Out of these 228 scapulae, 126 belong to right side and 102 belong to left side. This study was conducted in January 2016.

The age and gender of the bones used in the study was not predetermined. Only fully ossified, dried, macerated and thoroughly cleaned scapulae which were complete in all respects in order to give the correct observations were included in the study while the scapulae which were damaged and those having any deformity or pathology like healed fractures were excluded from the study. All

parameters were measured by using digital vernier caliper (accuracy: 0.01mm). All measurements were taken in millimeters.

The following parameters were studied:

Nonmetric parameters

Shape of the glenoid cavity

The tracing of the shape of the glenoid cavity was taken on a white paper with the help of a lead pencil. Three types of glenoid were found on the basis of tracings drawn: (a) Pear shape (b) Inverted comma shape and (c) Oval shape.

Metric parameters

Maximum scapular length

It was measured from point A to B, which were present on the summit of superior and inferior angle respectively (Figure 1).

Maximum scapular breadth

It was measured from point C to D, which were present where the spine intersects the medial border and at the middle of the posterior border of glenoid cavity respectively (Figure 1).

Supero inferior glenoid diameter (SI)

It was measured from point E to F, which represents the maximum distance between the most prominent point of the supraglenoid tubercle to most inferior point on the glenoid margin (Figure 1).

Antero posterior glenoid diameter 1 (AP-1)

It was measured from point H to I, which represents the maximum breadth of the articular margin of the glenoid cavity which is perpendicular to the glenoid cavity height (Figure 1).

Antero posterior glenoid diameter 2 (AP-2)

It was measured from point J to K, which represents the anteroposterior diameter (breadth) of the top half of the glenoid cavity at the mid point between the superior rim and the mid equator. Point G represents the mid point of supero inferior glenoid diameter (Figure 1).

Glenoid cavity index (GCI)

It was calculated with the help of following formula

$$GCI = \frac{\text{Antero posterior glenoid diameter} \times 100\%}{\text{Supero Inferior glenoid diameter}}$$

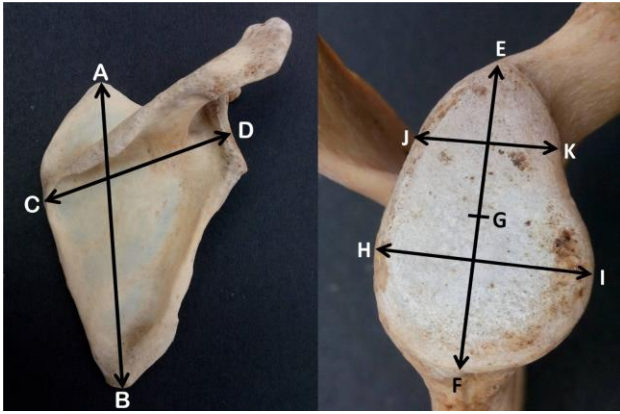


Figure 1: Different points on scapula and glenoid which were taken for measurements.

The software Graph Pad Prism version 4.03 was used for statistical analysis of the data. Continuous variables were expressed in term of mean and standard deviation while categorical variables were expressed in term of

percentage. Paired t test was used to compare the observations of right and left sided glenoid cavity. P values <0.05 were considered significant.

RESULTS

The most common shape of glenoid cavity recorded in the present study was pear shape (50.44%) followed by inverted comma shape (35.96%). The least common shape was oval (13.6%) (Table 1, Figure 2).

The mean length of scapula was observed as 135.07±14.23mm, the mean breadth of scapula was 97.55±9.63mm, the mean supero inferior glenoid diameter was 35.80±3.14mm, the mean antero posterior glenoid diameter 1 was 23.63±2.50mm, the mean antero posterior glenoid diameter 2 was 16.17±2.24mm and mean glenoid cavity index was 66.40±8.14%.

In all the above measurements bilateral differences was not statistically significant (P values >0.05) (Table 2).

Table 1: Different shapes of glenoid cavity.

Shape	Right Side	Left Side	Total
Pear	65 (51.59%)	50 (49.02%)	115 (50.44%)
Inverted comma	44 (34.92%)	38 (37.25%)	82 (35.96%)
Oval	17 (13.49%)	14 (13.73%)	31 (13.60%)
Total	126 (100%)	102 (100%)	228 (100%)

Table 2: Observations of different parameters of scapula and glenoid cavity.

Parameter	Range		Mean±SD		Total Mean±SD	T Value	P Value
	Right	Left	Right	Left			
Length of scapula	112.10 -157.79 mm	111.79 - 157.20 mm	135.70±14.3 2 mm	134.29±14.1 4 mm	135.07±14.23 mm	0.67	0.50
Breadth of scapula	79.56 - 118.20 mm	78.86 - 116.98 mm	97.97±9.07 mm	97.02±0.30 mm	97.55±9.63 mm	0.68	0.49
Supero inferior (SI) glenoid diameter	30.03 - 43.47 mm	29.50 - 41.20 mm	36.03±3.15 mm	35.52±3.12 mm	35.80±3.14 mm	0.80	0.42
AP glenoid diameter 1	18.5 - 29.22 mm	16.24 - 28.84 mm	23.67±2.53 mm	23.59±2.47 mm	23.63±2.50 mm	0.09	0.92
AP glenoid diameter 2	12.8 - 21.58 mm	11.20 - 20.85 mm	16.30±2.16 mm	16±2.34 mm	16.17±2.24 mm	0.96	0.33
Glenoid cavity index	46.93 - 89.79 %	44.71 - 89.26 %	66.13±8.67 %	66.73±7.47 %	66.40±8.14%	0.41	0.67

DISCUSSION

Many studies have been done globally by different workers on other races and groups of population about the morphometry of scapula and glenoid cavity in a variety of way like direct measurement on embalmed cadavers, direct measurement of dry scapulae,

radiographic measurements of scapulae harvested from the cadavers and radiographic measurements in the living patients etc. The present study was performed on dry human scapulae. After comparing and evaluating findings of the present study with that obtained by the various workers, several differences as well as similarities in the

measurements of the scapula and glenoid cavity were observed.

Shape of glenoid cavity

In the present study pear shaped glenoid was found in 51.59% of sample of the right side and 49.02% of the left side, which was most common type we observed and second most common type was inverted comma which was found 34.92% in right side and 37.25% in left side. Mamatha et al, Rajput et al, Gamal Hamed ESH and Sarwar et al also reported pear shaped glenoid was most common and inverted comma shaped glenoid was second most common type but Wael Amin NED and Mona Hassan MA reported comma shaped glenoid as most common and pear shaped glenoid as second commonest type in Egyptian population (Table 3).⁴⁻⁸

They also found oval shaped glenoid was least common similar to Mamatha et al, Rajput et al, Gamal Hamed ESH and Sarwar et al.⁴⁻⁷ Prescher et al reported only two types of glenoid in German population: one having a notch i.e. pear shaped in 55% cases and second without notch i.e. oval shaped in 45% cases.² While observations of Coskun et al in Turkish population were opposite to the findings of Prescher et al i.e. they found absent glenoid notch or oval shaped glenoid in 72% cases and in 28% cases glenoid notch was well expressed and glenoid cavity were classified as pear shaped.^{2,9} Gamal Hamed ESH⁶ observed 30.88% glenoid fossa were inverted comma shaped due to the presence of a distinct notch on the anterior rim this means one third of Eryptian population were prone to the Bankart lesion.

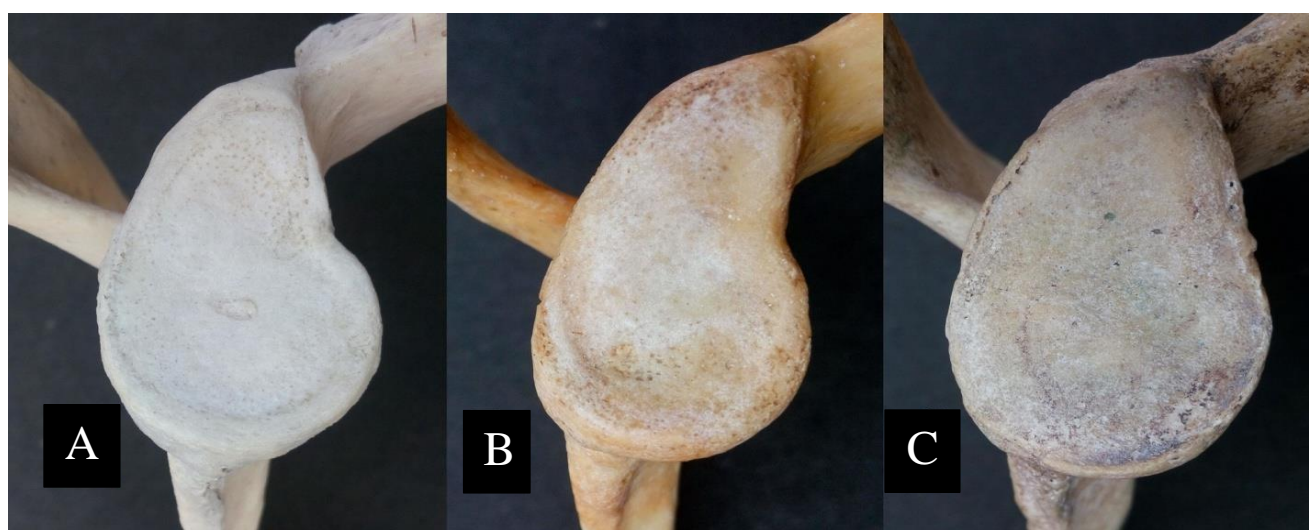


Figure 2: Different shapes of the glenoid cavity; (A: Pear shaped; B: Inverted comma shaped; C: Oval shaped).

Table 3: Comparison of incidence of different shapes of glenoid cavity.

Author	No. of specimen studied	Pear shaped (%)	Inverted comma shaped (%)	Oval shaped (%)
Mamatha et al ⁴	Right - 98	46	34	20
	Left - 104	43	33	24
Rajput et al ⁵	Right - 43	49	35	16
	Left - 57	46	39	15
Gamal Hamed ESH ⁶	Right - 38	44.74	31.58	23.68
	Left - 30	46.67	30	23.33
Wael Amin NED et al ⁸	Right - 80	35	16.25	48.75
	Left - 80	27.5	20	52.50
Sarwar et al ⁷	Right - 50	56	24	20
	Left - 50	64	20	16
Present study	Right - 126	51.59	34.92	13.49
	Left - 102	49.02	37.25	13.73

Maximum scapular length

The mean length of scapula observed in the present study was 135.07 mm with a SD of 14.23 mm which is very nearer to the values obtained by Patel et al in Gujarati population where they found a mean length of 136.03±11.49mm in male scapulae and 119.63±8.81mm in female scapulae. However our findings were quite different when compared to the studies done by Flower WH, Coskun et al, Wael Amin NED et al which were done on European, Turkish and Egyptian population respectively.⁸⁻¹¹ The mean scapular length of these regions were higher than that of our study (Table 4). These differences may be due to population variation.

Table 4: Comparison of mean scapular length by different workers.

Author	No. of specimen studied	Mean length of scapula (mm)
Flower W H ¹¹	200	155.54
Coskun et al ⁹	90	98.8±7
Patel et al ¹⁰	Male:40	136.03±11.49
	Female:22	119.63±8.81
Singal et al ¹²	162	141.7±8.9
Krishnaiah et al ¹³	50	143.27±11.44
Wael Amin NED et al ⁸	160	151.16±10.32
Present Study	228	135.07±14.23

Maximum scapular breadth

The mean breadth of scapula observed in the present study was 97.55 mm with a SD of 9.63 mm which is very nearer to the values obtained by Singal et al in Gujarati population where they found a mean breadth of 96.4±7mm.¹²

Patel et al also reported mean breadth of scapula were 93.52±4.38 mm in female scapulae. While Krishnaiah et al, Flower WH, Wael Amin NED et al reported higher value of mean breadth of the scapula (Table 5).^{8,10,11,15}

Table 5: Comparison of mean scapular breadth by different workers.

Author	No. of Specimen Studied	Mean breadth of scapula (mm)
Flower WH ¹¹	200	101.42
Singal et al ¹²	162	96.4±7
Patel et al ¹⁰	Male:40	100.67±8.51
	Female:22	93.52±4.38
Krishnaiah et al ¹³	50	105.6±5.08
Wael Amin NED et al ⁸	160	107.22±9.74
Present Study	228	97.55±9.63

Supero inferior glenoid diameter

The mean SI glenoid diameter and SD was 35.80±3.14mm with a mean and SD of 36.03±3.15mm on right side and 35.52±3.12mm on left side. The measurements of SI glenoid diameter of right side were slightly higher than left, but were statistically insignificant. The observations of Luis RF in male scapula, Kavita et al and Sarwar et al were very close to our findings while Churchill et al, Ozer et al et al Mona Hassan MA reported higher value and Mamatha et al, Rajput HB et al, Patel et al and Patil GV et al reported lower value than those obtained in the present study (Table 6).^{3-5,7,8,10,14-17}

In present study, the sex of the scapulae was not known therefore male and female bones could not be measured separately.

Table 6: Comparison of mean supero inferior glenoid diameter by different workers.

Author	No. of specimen studied	Mean SI diameter (mm)
Churchill et al ³	Male: 200	37.5±2.2
	Female: 144	32.6±1.8
Luis Rios Frutos ¹⁴	Male: 65	36.08±2.0
	Female: 38	31.7±1.7
Ozer et al ¹⁶	Male: 94	38.71±2.71
	Female: 92	33.79 ± 3.08
Mamatha et al ⁴	Right: 98	33.67±2.82
	Left: 104	33.92±2.87
Rajput HB et al ⁵	Right: 43	34.76±3.0
	Left: 57	34.43±3.21
Patel et al ¹⁰	Male: 40	34.64±3.59
	Female: 22	31.29±1.64
Kavita et al ¹⁵	Right: 67	35.2±3.0
	Left: 62	34.7±2.8
Patil GV et al ¹⁷	Right: 104	33.68±4.32
	Left: 120	32.09±4.11
Wael Amin NED et al ⁸	Right: 80	38.88±2.63
	Left: 80	39.01±2.49
Sarwar et al ⁷	Right: 50	35.22±3.26
	Left: 50	34.53±3.21
Present Study	Right: 126	36.03±3.15
	Left: 102	35.52±3.12

Antero posterior glenoid diameter 1

The mean AP glenoid diameter 1 in the present study was 23.63±2.50 mm. It was 23.67±2.53 on right side while 23.59±2.47 mm on left side. The differences of right and left side were statistically insignificant.

Churchill et al recorded mean AP glenoid diameter 1 of 23.6±1.5 mm in female scapulae which was very close to our findings.³

The findings of Mamatha et al (in both right and left side), Rajput HB et al and Patil GV et al in right sided scapula and Patel et al in male scapula were also very near to our findings and the rest workers shown in table 7 reported higher value than us.^{4,5,10,17} These differences may be due to distinct ethnic origin in demographic samples that have their own anatomical variations.

Table 7: Comparison of mean antero posterior glenoid diameter 1 by different workers.

Author	No. of specimen studied	Mean AP diameter 1 (mm)
Churchill et al ³	Male: 200	27.86±1.6
	Female: 144	23.6±1.5
Luis Rios Frutos ¹⁴	Male: 65	26.3±1.5
	Female: 38	22.31±1.4
Ozer et al ¹⁶	Male: 94	27.33±2.4
	Female: 92	22.72±1.72
Mamatha et al ⁴	Right: 98	23.35±2.04
	Left: 104	23.05±2.30
Rajput HB et al ⁵	Right: 43	23.3±3.0
	Left: 57	22.92±2.80
Patel et al ¹⁰	Male: 40	23.89±2.29
	Female: 22	22.22±2.73
Kavita et al ¹⁵	Right: 67	25.07±2.7
	Left: 62	24.9±2.0
Patil GV et al ¹⁷	Right: 104	23.29±2.34
	Left: 120	24.90±2.95
Wael Amin NED et al ⁸	Right: 80	21.33±2.49
	Left: 80	21.69±2.06
Sarwar et al ⁷	Right: 50	23.95±2.78
	Left: 50	23.64±2.37
Present Study	Right: 126	23.67±2.53
	Left: 102	23.59±2.47

Antero posterior glenoid diameter 2

The mean AP glenoid diameter 2 in the present study was 16.17±2.24mm. It was 16.30±2.16mm on right side while 16±2.34 mm on left side. These differences of right and left side were also not statistically significant. The observations of Mamatha et al, Kavita et al, Patil GV et al and Sarwar et al were near to our results.^{4,7,15,17} While Iannotti and Wael Amin NED et al reported very higher mean AP glenoid diameter 2 value in comparison to present findings which were may be due to racial differences.^{8,18} Only Rajput HB et al reported lower values than us (Table 8).⁵

Glenoid cavity index (GCI)

The mean glenoid cavity index (GCI) found in the present study was 66.40±8.14%. It was 66.13±8.67% on the left side and 66.73±7.47% on the right side. The mean cavity index of 70.37±4.08% on right side while 68.59±4.36% on left side recorded by Dhindsa et al while

Polguy et al observed combined glenoid cavity index was 72.35±5.55% in their study.^{19,20}

The mean glenoid cavity index recorded by Gamal Hamed ESH were 73.67±9.08% in right side and 76.71±8.37% in left side.⁶ The values of all the above three workers were quite higher than our observations.

Table 8: Comparison of mean antero posterior glenoid diameter 2 by different workers.

Author	No. of specimen studied	Mean AP diameter 2 (mm)
Iannotti ¹⁸	140	23±2.7
Mamatha et al ⁴	Right: 98	16.27±2.01
	Left: 104	15.77±1.96
Rajput HB et al ⁵	Right: 43	15.10±2.54
	Left: 57	13.83±2.45
Kavita et al ¹⁶	Right: 67	16.8±1.8
	Left: 62	16.3±2.0
Patil GV et al ¹⁷	Right: 104	15.74±1.75
	Left: 120	16.81±1.74
Wael Amin NED et al ⁸	Right: 80	28.31±2.38
	Left: 80	27.99±2.55
Sarwar et al ⁷	Right: 50	16.16±2.38
	Left: 50	15.34±2.17
Present Study	Right: 126	16.30±2.16
	Left: 102	16±2.34

CONCLUSION

The knowledge about the different shape and dimensions of glenoid are very important during designing and fitting of glenoid component for total shoulder arthroplasty. It is also helpful during evaluation of different pathological conditions like rotator cuff disease, osteochondral defects and Bankart lesion. The mean supero inferior glenoid diameter recorded in our study was 35.80mm, however the specimens used in the study were non arthritic which means that the average diameter in an arthritic glenoid cavity would be slightly lesser than the present value due to some bone loss and the diameter may further decrease after reaming of the glenoid.

The standard size of available smallest glenoid component in the market is 40mm which may not fit in the glenoid of our study population. This fact must be taken into consideration while designing glenoid prostheses for the population of Bihar. Since the present study is conducted on a limited number of scapulae further cadaveric, radiological and clinical studies are indicated.

ACKNOWLEDGEMENTS

Authors would like thank Prof. Dr. Arvind Prasad, Principal and HOD, Department of Forensic Medicine and Toxicology of Indira Gandhi Institute of Medical

Sciences for granting the permission to carry out the study in the department.

Funding: No funding sources

Conflict of interest: None declared

Ethical approval: Not required

REFERENCES

1. Johnson D. Pectoral Girdle, Shoulder region and Axilla. In: Standring S, Borley NR, Collins P, Crossman AR, Gatzoulis MA, Healy JC, et al, editors. Gray's Anatomy, The Anatomical Basis of Clinical Practice. 40th ed. Churchill Livingstone; 2013;791-822.
2. Prescher A, Klumpen T. The glenoid notch and its relation to the shape of the glenoid cavity of the scapula. J Anat. 1997;190:457-60.
3. Churchill RS, Brems JJ, Kotschi H. Glenoid size, inclination, and version: An anatomic study. J Shoulder Elbow Surg. 2001;10(4):327-32.
4. Mamatha T, Pai SR, Murlimanju BV, Kalthur SG, Pai MM, Kumar B. Morphometry of Glenoid Cavity. Online J Health Allied Scs. 2011;10(3):1-4.
5. Rajput HB, Vyas KK, Shroff BD. A Study of Morphological Patterns of Glenoid Cavity of Scapula. Natl J Med Res. 2012;2(4):504-7.
6. Gamal Hamed ESH. Morphometry of Glenoid fossa in Adult Egyptian Scapulae. Int J Anat Res. 2015;3(2):1138-42.
7. Sarwar MS, Diwan CV, Rahamn H, Raheman H, Moosa SM. A Morphometric study of glenoid cavity of adult human scapula. International Journal of Recent Trends in Science and Technology. 2015;15(3):486-90.
8. Wael Amin NED, Mona Hassan MA. A Morphometric Study of the Patterns and Variations of the Acromion and Glenoid Cavity of the Scapulae in Egyptian Population. Journal of Clinical and Diagnostic Research. 2015;9(8):8-11.
9. Coskun N, Karaali K, Cevikol C, Demirel BM, Sindel M. Anatomical basics and variations of the scapula in Turkish adults. Saudi Med J. 2006;27(9):1320-5.
10. Patel SM, Shah MA, Vora RK, Goda JB, Rathod SP, Shah S. Morphometric analysis of scapula to determine sexual dimorphism. Int J Med Public Health. 2013;3:207-10.
11. Flower WH, Garson JG. The scapular index as a race character in man. Journal of Anat physiol. 1879;14(1):13-7.
12. Singhal G, Rathod H, Patel A, Modi P, Prajapati S, Parmar R. A study of measurements and indices of human scapula at Jamnagar Medical College. Int J Res Med. 2013;2(1):65-8.
13. Krishnaiah M, Nagaraj S, Praveen Kumar M, Sherke AR. Study of scapular measurements and scapular indices of Andhra Pradesh region. IOSR Journal of dental and medical sciences. 2014;13(6):117-20.
14. Frutos LR. Determination of sex from the clavicle and scapula in a Guatemalan contemporary rural indigenous population. Am J Forensic Med and Pathol. 2002;23:284-8.
15. Kavita P, Jaskaran S, Geeta. Morphology of coracoids process and glenoid cavity in adult human scapulae. International Journal of Analytical, Pharmaceutical and Biomedical Sciences. 2013;2(2):19-22.
16. Ozer I, Katayama K, Sagir M, Gulec E. Sex determination using the scapula in medieval skeletons from East Anatolia. Coll Antropol. 2006;30:415-9.
17. Patil GV, Kolagi SI, Ramdurg U. Morphometrical study of scapular glenoid cavities. Global Journal of Medical Research: Orthopedics and Musculoskeletal system. 2014;14(2):9-14.
18. Iannotti JP, Gabriel JP, Schneck SL, Evans BG, Misra S. The normal glenohumeral relationships. An anatomical study of one hundred and forty shoulders. J Bone Joint Surg Am. 1992;74:491-500.
19. Dhindsa GS, Singh Z. A study of morphology of glenoid cavity. Journal of Evolution of Medical and Dental Sciences. 2014;3:7036-43.
20. Polguy M, Jedrzejewski KS, Podgorski M, Topol M. Correlation between morphometry of the suprascapular notch and anthropometric measurements of the scapula. Folia Morphol. 2011;70:109-15.

Cite this article as: Akhtar MJ, Kumar B, Fatima N, Kumar V. Morphometric analysis of glenoid cavity of dry scapulae and its role in shoulder prosthesis. Int J Res Med Sci 2016;4:2770-6.