

Case Series

Successful conservative treatment for posterior cruciate ligament ganglion cyst; a simple approach to a very rare case: a case series

Yovi Maulana, Krisna Yuarno Phatama*

Department of Orthopaedics and Traumatology, Saiful Anwar General Hospital- Brawijaya University, Malang, Indonesia

Received: 17 August 2021

Revised: 02 October 2021

Accepted: 05 October 2021

***Correspondence:**

Dr. Krisna Yuarno Phatama,

E-mail: krisnayurno@ub.ac.id

Copyright: © the author(s), publisher and licensee Medip Academy. This is an open-access article distributed under the terms of the Creative Commons Attribution Non-Commercial License, which permits unrestricted non-commercial use, distribution, and reproduction in any medium, provided the original work is properly cited.

ABSTRACT

Posterior cruciate ligament (PCL) ganglion cyst is relatively uncommon compared to anterior cruciate ligament (ACL) ganglion cyst. The combined prevalence of all cruciate ganglion cyst (anterior and posterior combined) is ranging from 0.2%-1.9%. It is usually found as an incidental finding during MRI examination. PCL ganglion cyst may be asymptomatic, or it may present as variety of knee symptoms. To the authors' knowledge, there is no consensus regarding its treatment. Previous case series suggest treatment of PCL ganglion by arthroscopic resection. However, in this case series, we present 4 cases of young patients with PCL ganglion cyst treated successfully by rest and bracing. After our series of conservative treatment, the patients reported satisfactory pain relief. This result suggests that symptomatic PCL ganglion cyst could be treated conservatively.

Keywords: Conservative treatment, PCL ganglion, Rare case

INTRODUCTION

Ganglion cyst is swelling filled with synovial fluid usually arising in the proximity of tendon, joint or ligaments. It is commonly found in the hand region, but it may occur in other anatomical regions. Intraarticular ganglion cyst on the cruciate ligament is uncommon, and it is usually found incidentally during MRI examination. More than 75% of the cases are found on the ACL.¹ The combined prevalence of all cruciate ganglion cyst (anterior and posterior combined) is ranging from 0.2%-1.9%.² This lesion could be found as a standalone lesion or found with another lesion such as meniscal or chondral lesion.³

Ganglion cyst of the PCL is uncommon and like its counterpart, it is usually found incidentally during arthroscopy or MRI. Most cases are associated with history of trauma, and the patients usually present with

pain on flexion. A recent case series concluded that arthroscopic resection may provide satisfactory outcome.⁴ There is, however, no consensus on how treat ganglion cyst of PCL. In this case series, we present 4 cases of PCL ganglion cyst successfully treated conservatively with bracing.

CASE SERIES

Case 1

An 18-year-old male presented to our clinic with right knee pain on flexion. It is exacerbated with stair climbing, running, and squatting. His physical examination was unremarkable and not specific. MRI examination revealed lobulated cystic lesion on the PCL. The patient was treated conservatively with rest and bracing for 4 weeks. He reported pain relief and symptoms alleviation.

Case 2

A 20-year-old female presented to our clinic with right knee pain. It is exacerbated with stair climbing and squatting. Her physical examination was not specific. MRI examination revealed lobulated cystic lesion on the PCL. The patient was treated conservatively with rest and bracing for 4 weeks. She reported improvement of symptoms after 4 weeks.

Case 3

A 23-year-old male recreational runner presented to our clinic with left knee pain. He complained of knee pain during running in last 2 months. His physical examination was unremarkable, and there was no sign of ligamentous or meniscal injuries. MRI examination revealed lobulated cystic lesion on the PCL. The patient was treated conservatively with rest and bracing for 4 weeks. He reported improvement of symptoms after 4 weeks, but there was residual pain. The bracing was continued for another 2 weeks, and he reported symptomatic relief.

Case 4

A 17-year-old male presented to our clinic with right knee pain. It is especially exacerbated with squatting. His physical examination was not specific for any kind of injuries. MRI examination revealed lobulated cystic lesion on the PCL. The reported symptomatic relief after 4 weeks of bracing and rest.

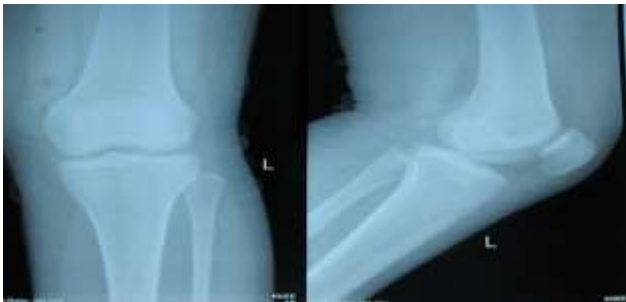

Figure 1: Knee X-ray of the patient, there is no abnormality of the bone.

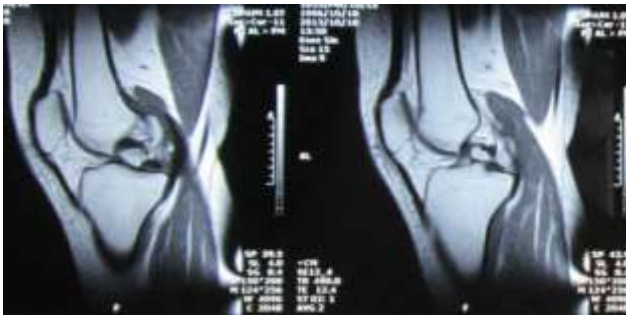


Figure 2: Sagittal MRI of the patient's knee, of soft tissue mass on the posterior aspect of the knee joint.

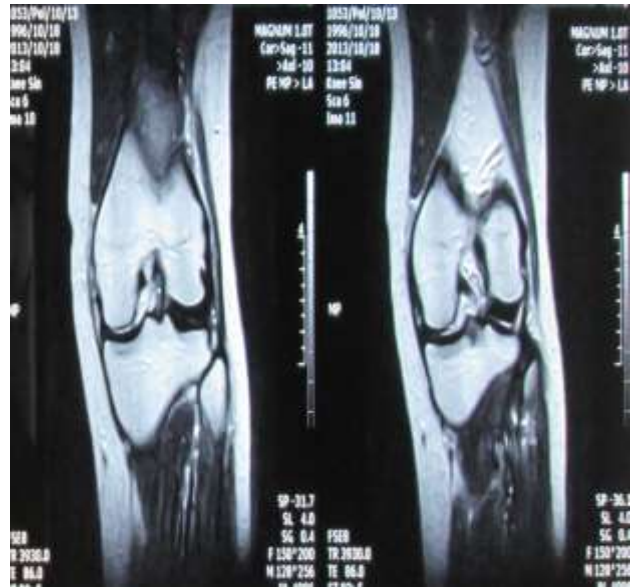

Figure 3: Coronal MRI of the patient's knee, of soft tissue mass attached to the PCL.

DISCUSSION

Ganglion cyst is a disease entity without known specific cause. Most theories suggest it occurs due to degeneration of the connective tissue. Ganglion cyst of the PCL is rare, and it is mostly an incidental finding. However, symptomatic ganglion cyst of the PCL may possibly impair a patient's quality of life.⁵

Currently, there is no standard on how to treat symptomatic PCL ganglion cyst. Most available literatures mention arthroscopic debridement of the cyst as the treatment of choice with excellent outcome.^{4,6-8} One case report mentions a PCL ganglion cyst as an incidental findings found during arthroscopic ACL reconstruction. Thus, the symptoms caused by the PCL ganglion cyst was masked by the ACL rupture. The cyst in that case was removed arthroscopically during the surgery, and after 1 year follow-up the patient reported pain-free good functional outcome.⁹

Although this entity seems benign, one study reports ganglion cyst of PCL may cause mucinous degeneration of the entire ligament. The authors opted to respect the entire ligament, and they report an excellent outcome.¹⁰

In our case series, we report good functional outcomes after conservative treatment with bracing and rest. Unfortunately, there is no literature mentioning the conservative treatment of PCL ganglion cyst.

CONCLUSION

Conservation treatment could be recommended in treating PCL ganglion cyst, resulting in good functional outcome.

ACKNOWLEDGEMENTS

The authors would like to thanks to radiology department of Persada hospital, Malang for the acquisition of data.

Funding: No funding sources

Conflict of interest: None declared

Ethical approval: Not required

REFERENCES

1. Mao Y, Dong Q, Wang Y. Ganglion cysts of the cruciate ligaments: A series of 31 cases and review of the literature. BMC Musculoskelet Disord. 2012;13:2-5.
2. Stein D, Cantlon M, Mackay B, Hoelscher C. Cysts about the knee: evaluation and management. J Am Acad Orthop Surg. 2013;21(8):469-479.
3. Shetty GM, Nha KW, Patil SP. Ganglion cysts of the posterior cruciate ligament. Knee. 2008;15(4):325-329.
4. Tie K, Wang H, Zhao X, Tan Y, Qin J, Chen L. Clinical manifestation and arthroscopic treatment of symptomatic posterior cruciate ligament cyst. J Orthop Surg Res. 2018;13(1):1-6.
5. Durante JA. Ganglion cyst on the posterior cruciate ligament: a case report. J Can Chiropr Assoc. 2009;53(4):334-8.
6. Andreozzi V, Monaco E, Conteduca F. Diagnosis and Treatment of a Symptomatic Posterior Cruciate Ganglion Cyst in a Child with Autism. Case Rep Orthop. 2019;2019:1-6.
7. Joo YB, Kim YM. Symptomatic Posterior Cruciate Ganglion Cyst Causing Impingement between Posterior Root of the Medial Meniscus and Anterior to the Posterior Cruciate Ligament. Knee Surg Relat Res. 2012;24(1):52-5.
8. Tsai T-Y, Yang Y-S, Tseng F-J. Arthroscopic excision of ganglion cysts of the posterior cruciate ligaments using posterior trans-septal portal. Arthrosc J Arthrosc Relat Surg Off Publ Arthrosc Assoc North Am Int Arthrosc Assoc. 2012;28(1):95-9.
9. Ahmed F, Ibrahim SA, Soliman A, Khirat S. Ganglion cyst of the posterior cruciate ligament. BMJ Case Rep. 2010;2010:bcr0920092263.
10. Nam D, Macaulay A, Cross M, Shindle MK, Warren RF. Posterior cruciate ligament resection for ganglion cyst and associated ligament degeneration. Am J Orthop (Belle Mead NJ). 2011;40(6):E110-4.

Cite this article as: Maulana Y, Phatama KY. Successful conservative treatment for posterior cruciate ligament ganglion cyst; a simple approach to a very rare case: a case series. Int J Res Med Sci 2021;9:3424-6.