

Research Article

Rotational malalignment after closed intramedullary nailing of femoral shaft fractures and its influence on functional outcome

Yogesh Sharma, Girish G. Mugdum, Anjan Prabhakara*

Department of Orthopaedics, Armed Forces Medical College, Pune, Maharashtra, India

Received: 11 May 2016

Accepted: 06 June 2016

*Correspondence:

Dr. Anjan Prabhakara,

E-mail: anjansmiles@gmail.com

Copyright: © the author(s), publisher and licensee Medip Academy. This is an open-access article distributed under the terms of the Creative Commons Attribution Non-Commercial License, which permits unrestricted non-commercial use, distribution, and reproduction in any medium, provided the original work is properly cited.

ABSTRACT

Background: Rotational malalignment after closed intramedullary nailing of femoral shaft fractures is one of the most common complication. Data on functional outcome of such rotational malalignment particularly in an Asian population is lacking. This cross sectional study intends to determine the prevalence of rotational malalignment occurring after intramedullary nailing of femoral shaft fractures using CT scans and also compare this with femoral malrotation detected by clinical methods. The study also aims to analyze the effect of such femoral malrotation on functional outcome.

Methods: 81 patients who underwent closed IM nailing of femoral shaft fractures were reviewed after fracture union. The rotational malalignment was measured using CT scans and clinical methods. CT based torsional deformity $>15^\circ$ were considered significant. Functional outcome was assessed using Harris hip score (HHS), lower extremity functional scale (LEFS) and WOMAC osteoarthritis index for knee.

Results: On CT 30 (37%), 24 (29.6%) and 27 (33.33%) patients had rotational malalignment of $<10^\circ$, 10° - 14° and $>15^\circ$ respectively. This was independent of the fracture location, fracture type, implant design or metallurgy. The clinical method of assessing femoral rotation was less accurate (sensitivity 18.52% and specificity of 79.63%) as compared to CT method though not statistically significant. However LEFS ($P=0.009$) and WOMAC ($P=0.033$) scores were statistically poorer in patients with true rotational malalignment ($\geq 15^\circ$). However no significant difference was noted between the groups in HHS. Patients with external and internal rotation deformities had comparable functional results.

Conclusions: In this study, true rotational malalignment ($>15^\circ$) after closed intramedullary nailing of femoral shaft fractures was found in 33.33% of patients. This is independent of fracture location, fracture type, implant design or implant metallurgy. Torsional deformities of femur $>15^\circ$ affect knee and lower limb function as a whole. External and internal rotational deformities perform equally.

Keywords: Femoral fracture, Intramedullary nailing, Rotational malalignment, CT measurement

INTRODUCTION

Femoral shaft fractures are one of the most common fractures encountered by an Orthopaedic surgeon with an average annual incidence of 21 per 100,000 and majority are young males (62%) with an average age of 38 years.¹ Closed Interlocking nailing is the treatment of choice for acute femoral shaft and subtrochanteric fractures in skeletally mature population due to multiple advantages

as compared to its counterpart of open reduction and internal fixation using plates.²⁻⁴ The advantages include a minimally invasive surgery, high union rates, preservation of fracture hematoma with rapid and early mobilization. This is considering the fact that intramedullary nail is a load sharing device.

It is a well-known fact that it is more difficult to control rotation of the fracture components with closed IM

nailing than with plate fixation.^{5,6} The incidence of rotational malalignment is the most reported complication in femoral shaft fractures managed by closed IM nailing and it varies from 8-28%.⁷⁻¹⁰ Data on functional outcome of such rotational malalignment particularly in an Asian population is lacking. Since the possible torsion of a locked femoral nail itself is too small to be the cause of rotational malalignment the deformity is established during the operation, indicating inadequate reduction of the fracture.¹¹⁻¹⁴ The rotational malalignment is detected and corrected intraoperatively by techniques like comparing the lesser trochanter profile of the uninjured limb, "cortical step sign" and diameter difference sign.¹⁵⁻¹⁸

Rotational malalignment or torsional deformity is expressed as a difference in femoral ante version between the injured and uninjured leg and loss of rotational movements. The various methods to measure rotational malalignment after femoral shaft fracture fixation are clinical method, radiography, ultrasound and CT scan evaluation. CT scan based method is most preferred as it is reliable and accurate. The most commonly used and accepted gold standard assessment using CT scans is that described by Jeanmart et al.¹⁹

The aim of the study was to determine the prevalence of rotational malalignment of femur after closed intramedullary nailing of femoral shaft fractures in an Asian population and its effect on functional outcome.

The objectives of the study were as follows;

- To determine the frequency and degree of rotational malalignment after closed intramedullary nailing of femoral shaft fractures using CT measurements.
- To compare CT measured rotational malalignment of femur with clinically measured rotational malalignment.
- To determine the relationship between the magnitude of rotational deformity and clinical outcome and also establish the relationship between the type of rotational deformity (external or internal) and clinical outcome.
- To outline the causes of rotational malalignment in closed IM nailing of femoral shaft fractures and highlight the methods of preventing it.

METHODS

Between June 2012 and June 2015 a total of 98 patients with femoral shaft fractures who were managed by closed intramedullary nailing at our institute were reviewed. Patients between 18 to 50 years of age with isolated femoral shaft fracture managed by closed antegrade intramedullary interlocking nail and reviewing after clinicoradiological evidence of fracture union were included in the study. Bilateral femoral shaft fractures, pathological fractures, previous, simultaneous or later fracture of femoral neck or intertrochanteric fracture on the same or opposite side, ipsilateral floating knee

injuries, deformity of at least one lower limb i.e. polio, major joint contractures, lower limb amputees and patients with open fracture shaft femur and with any contraindications to CT scanning like pregnancy were excluded from the study. Institutional ethical committee clearance was obtained and written informed consent was taken from all the patients. 89 patients fulfilled the inclusion and exclusion criterion. 4 patients were not willing to participate in the study, three were lost to follow-up and one had a non-union requiring a second procedure and was excluded from the study.

During surgery all patients were secured on a fracture table in supine position and fracture fixed using either a stainless steel or titanium antegrade AO femoral nail. The choice between these 2 nails depended on the preference of the operating surgeon involved. All nails were placed antegrade and were statically locked using an image intensifier. Postoperatively, all patients were started with hip, knee, and ankle range of motion exercises on postoperative day one. Partial weight bearing ambulation was allowed at 6 weeks post op and full weight bearing allowed after radiographic fracture union. At follow up, a detailed history regarding the date and mode of injury along with date of surgery was recorded. Pre-operative x-rays were reviewed to classify the fractures (AO Type A/B/C) and localize the site of fracture (Proximal/mid/distal third). Subsequent postoperative radiographs of the affected limb were reviewed for fracture union and documented. The details of the implant including the type of nail (Trochanteric entry or Piriformis entry) and implant material (Stainless steel or titanium) were recorded.

At last follow-up, a physical examination was carried out on OPD basis. The observers did not know the results of the CT measurement at the time of the clinical examination. During examination, specifically the range of internal and external rotation of hip on both the injured and uninjured sides were measured for comparison using a goniometer while the patient was lying prone with hip in 0° and knee in 90° flexion. Any shift in arc of motion towards internal or external rotation determined the clinical rotational deformity. If the internal rotation at the affected hip was more as compared to external rotation, then the deformity was considered to be an internal rotation deformity and vice versa. For CT based assessment, the scout film tomogram of the whole of femur was taken to include the areas of interest and then the axial sections of femoral neck and femoral condyles were taken. The axial section which showed the profile of femoral neck and femoral condyles the best were chosen and placed one below the other using image software (Gimp 2). One line was drawn along the posterior border of the femoral condyles and another drawn through the femoral neck. Two perpendiculars were drawn respectively to both of these lines. The angle between these two perpendicular lines defined the femoral torsion.

The difference in angle between the fractured and unaffected side determined any rotational malalignment (Figure 1A and B). To rule out any inaccuracy in the CT measurements, all CT images were measured twice by 2 observers: a radiologist, and an orthopaedic surgeon. The average of these 4 separate measurements was used in this study. A decrease or increase in the angle on the fractured side meant increased external rotation or increased internal rotation of the distal femoral fragment respectively.

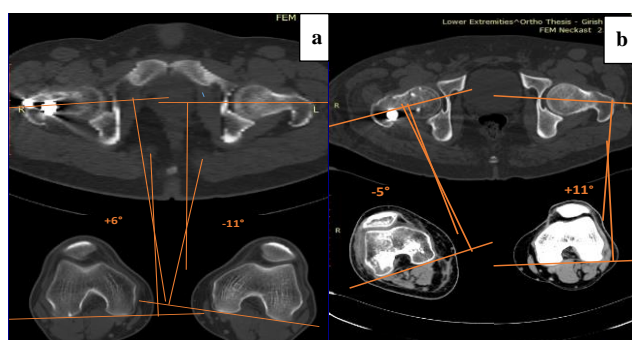


Figure 1: Two cases of measuring rotational deformity by using CT method as described by Jean mart et al; (a) has an internal rotation deformity of 17° and; (b) has an external rotation deformity of 16°.

Functional outcome in patients was assessed using Harris hip score, WOMAC knee scores and Lower Extremity Functional Scale (LEFS).

Statistical analysis

The data were analysed using the SPSS software, Version-20 (IBM). To assess difference between groups in terms of continuous variables Independent sample t-test were used. To assess association between various groups in terms of qualitative variables, Fisher exact test, X² test and Kruskal Wallis test were used. P values of 0.05 or less were considered significant.

RESULTS

Out of 81 patients 66 (81.5%) were males and 15 (18.5%) were females. The average age of the study population

was 39.1 years. The mean follow up was 22.5 months (range 14 to 36 months). On CT evaluation, 54 (66.67%) patients had rotational malalignment <15° [30 patients (37%) < 10°, 24 patients (29.6%) between 10°-14°] and 27 patients (33.33%) had a rotational malalignment >15°. Based on the location of fracture, majority were in mid shaft or isthmus region (85.2%) followed by proximal fractures (9.9%) and distal fractures (4.9%). There was no statistically significant association between CT based rotational malalignment and location of fracture (p=0.313). Depending on the fracture morphology, 53 patients (65%) with a transverse fracture were in group A, 27 patients (33.33%) with a wedge type fracture were in group B, 1 patient (1.2%) with complex fracture morphology was in group C. No statistically significant difference in the incidence of rotational malalignment was noted between the groups (p=0.346) (Table 1).

Trochanteric entry nail was used in 22 patients (27.2%) and piriformis entry nail was used in 59 patients (72.8%). A rotational malalignment of >15° was noted in 20 patients (33.89%) with piriformis entry nail and 7 patients (31.81%) with trochanteric entry nail. However there was no significant difference in the association between type of nail and rotational malalignment (p = 0.859) (Table 2). Stainless steel (SS) nails were used in 48 (59.26%) patients and titanium nails were used in 33 (40.74) patients. A rotational malalignment of >15° was noted in 17 patients (35.42%) with SS nails and 10 patients (58.82%) with titanium nails. The difference was not statistically significant (p = 0.631) (Table 2).

Out of 16 patients (19.8%) who had true rotational malalignment (≥15°) on clinical evaluation, only 5 had true rotational malalignment (≥15°) on CT scan evaluation. Meanwhile out of 65 patients (79.2%) who had rotational malalignment <15° when assessed clinically, CT evaluation revealed rotational malalignment ≥15° in 43 of them. The sensitivity of clinical method as compared to CT was 18.52% and specificity was 79.63%. As seen above, clinical method of assessing femoral rotation was not as accurate as CT based evaluation, however no statistically significant difference between the two methods could be established (p=0.413).

Table 1: CT rotational malalignment versus location and type of fracture.

Fracture location	Femoral rotation <15°	Femoral rotation ≥15°	Total	P-value
Proximal	7	1	8	0.313
Mid shaft	45	24	69	
Distal	2	2	4	
Fracture type	Femoral rotation <15°	Femoral rotation ≥15°	Total	P-value
A	37	16	53	0.346
B	17	10	27	
C	0	1	1	

Table 2: CT rotational malalignment versus type of nail.

Type of Nail	Femoral rotation <15 ⁰	Femoral rotation ≥15 ⁰	Total	P- value
Trochanteric entry	15	7	22	0.859
Piriformis entry	39	20	59	
Stainless steel	31	17	48	0.631
Titanium	23	10	33	

On functional evaluation, LEFS (P=0.009) and WOMAC knee scores (P=0.033) were poorer in the group of patients with true rotational malalignment (≥15°) as compared to those with rotational malalignment less than 15° and the difference was statistically significant. However there was no statistically significant difference

in Harris hip score between the groups (Table 3). No statistically significant difference was found between true internal and true external rotation malalignment (>15°) with respect to the functional scores viz. LEFS (P=0.382), Harris hip score (P =0.921) and WOMAC score for knee (P =0.099) (Table 3).

Table 3: Magnitude and type of CT rotational malalignment versus function.

Rotational malalignment	<15 ⁰ (n=54)		≥15 ⁰ (n=27)		P value	Internal rotation ≥15 ⁰ (n=16)		External rotation ≥15 ⁰ (n=11)		P value
	Mean	SD	Mean	SD		Mean	SD	Mean	SD	
Functional Score										
LEFS	71.31	5.065	68.07	5.342	0.009	67.31	5.375	69.19	5.344	0.382
Harris hip score	92.06	5.658	90.33	6.409	0.220	90.44	6.511	90.18	6.570	0.921
WOMAC knee score	95.26	4.135	92.67	6.557	0.033	90.94	7.550	95.18	3.816	0.099

DISCUSSION

Intramedullary (IM) nailing has become the preferred method of treatment for fractures of femur in skeletally mature population. It entails a small incision, minimum soft tissue dissection, preserves the biology, resulting in excellent healing of the fracture and a swift recovery. Interlocking bolts also provide rotational stability and maintain length thus ensuring the conditions for a prompt return to full weight bearing and union of the fracture. However the closed approach makes IM nailing a technically demanding procedure.²⁰ It is difficult to confirm an anatomical reduction while performing closed reduction, resulting in loss of rotational control in contrast to traditional fixation by a plate. Varying data on prevalence of rotational malalignment following closed IM nailing of femoral shaft fractures have been reported, but there is a paucity of data from similar studies in Asian population.

Rotational malalignment or torsional deformity of the femur is expressed as a femoral Ante Version difference between the injured and uninjured side. This rotational malalignment can be measured by clinical method, radiography, ultrasound and by CT. A poor correlation between actual femoral torsion and clinical measurements of hip rotation has been reported.⁹ Proper positioning of patient is required for a correct measurement of torsional

deformity using the X-ray technique and is often difficult because of the possible posttraumatic axial deformities and painful mobility restrictions.^{21,22} Although ultrasound is believed to be more consistent it cannot be widely used because it is predominantly observer dependent.^{8,12} Computed tomography is currently the method of choice because of its reliability and reproducibility to determine rotational malalignment.²³⁻²⁵ Ante version differences less than 10° are normal variations.^{8,26} Between 10° and 14° is a somewhat gray zone referred to as possible deformity, and 15° or more anti version difference between the affected and unaffected side is considered as a true torsional deformity.

A total of 81 (66 males and 15 females) patients with femoral shaft fractures treated by closed intramedullary nailing were included in the study. The average age was 39.1 years. Majority of the fractures were mid shaft (85.2%) and transverse (65.4%) type. The prevalence of significant rotational deformity (≥15°) by clinical method was 19.8% (16 patients) and by CT method was 33.33% (27 patients). Comparable incidences of rotational malalignment with these results are found in studies using ultrasound or CT. Jaarsma reported 28% of significant rotational malalignment in femoral shaft fractures using CT scans.⁹ The sensitivity of clinical method as compared to CT was 18.52% and specificity was 79.63%. 40.75% of the patients who had significant torsional difference on

CT evaluation were not detected by clinical method. However in spite of poor correlation between clinical and CT methods of assessing femoral rotation, a statistically significant difference between these two methods ($p=0.413$) could not be established. This was probably because of the limited sample size.

In the present study the CT based evaluation of rotational malalignment was independent of implant design ($p=0.573$) and implant material ($P = 0.546$). We expected a greater rotational malalignment in patient with SS nails as compared to titanium nails which are supposed to be less stiffer with modulus of elasticity almost half that of steel and more close to bone. However we failed to prove this probably due to inadequate number of cases.

We anticipated greater incidence of internal rotational deformity of distal fragment in proximal femoral shaft fractures and increased incidence of external rotational deformity of distal fragment in distal femoral shaft fractures owing to various muscle attachments.²⁷ However similar to the findings of Jarsmaa, we could not establish a possible relationship between fracture location ($p= 0.617$) and rotational malalignment. The rotational malalignment was also independent of fracture type/comminution ($p= 0.794$).⁹

There are no specific functional scores which have been validated for femoral shaft fractures. Hence next best alternatives like Harris Hip Score and the WOMAC knee index for osteoarthritis were used. In addition to these scores we have taken into account LEFS (lower extremity functional scale) in order to assess the function of the lower limb as a whole. It was observed that LEFS ($P=0.009$) and WOMAC ($P=0.033$) knee scores were statistically poorer in patients with true rotational malalignment ($\geq 15^\circ$). Jaarsma reported problems particularly with high demand activities like climbing stairs, running, and sports in patients with a rotational malalignment.⁹ Yildirim et al stated that patellofemoral malalignment following closed IMN could cause pain and decreased patellofemoral scores.²⁸ Ozgur consistently found patients with rotational malalignment complaining of anterior knee pain while climbing stairs and attributed it to imbalance of the patellofemoral mediolateral force secondary to a torsional deformity of the femur.^{29,30} In our study no significant difference was noted between the groups in terms of HHS probably because of the limited number of cases, short duration of follow up and absence of extreme rotational malalignment $>20^\circ$.

The previous studies have indicated that the functional scores are worse in cases of patients who have true external rotation deformity ($\geq 15^\circ$) than internal rotation deformity due to difficulty in compensation.⁹ However, this was not confirmed in our study. This may also be because the true rotational deformities (external and internal) in our study ranged between 15° and 20° without any extremes of angles.

Rotational malalignment occurs during IMN due to inadequate fracture reduction. Various techniques have been described in order to better assess and achieve rotational alignment between fracture fragments intraoperatively viz. matching the profile of lesser trochanter of the injured limb to that of the neutrally aligned uninjured limb, matching of the cortical thickness, matching of the bone diameter of the proximal and distal fragments, measuring greater trochanter head contact angle.^{16-18,31} Computer navigation is a better method of assessing rotation intraoperatively.³²

CONCLUSION

In this study, significant rotational malalignment was found in 33.33% following closed intramedullary nailing of femoral shaft fractures. The clinical method of assessing rotational malalignment of femur is inaccurate as compared to CT evaluation. Patients with rotational malalignment $>15^\circ$ are symptomatic with knee and lower limb function. Every effort must be made to prevent rotational malalignment intraoperatively. Although various techniques are available for assessing rotational alignment between fracture fragments intraoperatively, Computer assisted navigation has the least margin of error and proves to be a promising tool on the road to eradication of this problem.

ACKNOWLEDGMENTS

The authors would like to thank Col (Dr) Giriraj Singh, Senior Advisor, Department of Radiodiagnosis, Command Hospital (SC), Pune for his support in CT scans for the study.

Funding: No funding sources

Conflict of interest: None declared

Ethical approval: The study was approved by the Institutional Ethics Committee, Armed Forces Medical College, Pune, India

REFERENCES

1. Enninghorst N, McDougall D, Evans JA, Sisak K, Balogh ZJ. Population-based epidemiology of femur shaft fractures. *The journal of trauma and acute care surgery.* 2013;74(6):1516-20.
2. Tornetta P, Ritz G, Kantor A. Femoral torsion after interlocked nailing of unstable femoral fractures. *Journal of Trauma and Acute Care Surgery.* 1995;38(2):213-9.
3. Wolinsky P, Tejwani N, Richmond JH, Koval KJ, Egol K, Stephen DJ. Controversies in intramedullary nailing of femoral shaft fractures. *The Journal of Bone & Joint Surgery.* 2001;83(9):1404-15.
4. Tornetta Pr, Tiburzi D. Antegrade or retrograde reamed femoral nailing A Prospective, Randomised Trial. *Journal of Bone & Joint Surgery, British Volume.* 2000;82(5):652-4.

5. Svenningsen S, Nesse O, Finsen V, Harnes O, Benum P, editors. Intramedullary nailing versus aoplate fixation in femoral-shaft fractures. *Acta orthopaedica scandinavica*; 1986: Scandinavian University Press Po Box 2959 Toyen, Journal Division Customer Service, N-0608 Oslo, Norway.
6. Wiss DA, Fleming CH, Matta JM, Clark D. Comminuted and rotationally unstable fractures of the femur treated with an interlocking nail. *Clinical orthopaedics and related research.* 1986;212:35-47.
7. Winquist RA, Hansen ST, Clawson DK. Closed intramedullary nailing of femoral fractures. A report of five hundred and twenty cases. *The Journal of Bone & Joint Surgery.* 1984;66(4):529-39.
8. Bråten M, Terjesen T, Rossvoll I. Femoral anteversion in normal adults: ultrasound measurements in 50 men and 50 women. *Acta Orthopaedica.* 1992;63(1):29-32.
9. Jaarsma R, Pakvis D, Verdonschot N, Biert J, Van Kampen A. Rotational malalignment after intramedullary nailing of femoral fractures. *Journal of orthopaedic trauma.* 2004;18(7):403-9.
10. Salem KH, Maier D, Keppler P, Kinzl L, Gebhard F. Limb malalignment and functional outcome after antegrade versus retrograde intramedullary nailing in distal femoral fractures. *Journal of Trauma and Acute Care Surgery.* 2006;61(2):375-81.
11. Krettek C, Mannß J, Miclau T, Schandelmaier P, Linnemann I, Tscherne H. Deformation of femoral nails with intramedullary insertion. *Journal of orthopaedic research.* 1998;16(5):572-5.
12. Braten M, Terjesen T, Rossvoll I. Torsional deformity after intramedullary nailing of femoral shaft fractures. Measurement of anteversion angles in 110 patients. *Journal of Bone & Joint Surgery, (Br).* 1993;75(5):799-803.
13. Sennerich T, Sutter P, Ritter G, Zapf S. (Computerized tomography follow-up of the anteversion angle after femoral shaft fractures in the adult). *Der Unfallchirurg.* 1992;95(6):301-5.
14. Alho A, Strosmsose K, Ekeland A. Locked intramedullary nailing of femoral shaft fractures. *Journal of Trauma and Acute Care Surgery.* 1991;31(1):49-59.
15. Jaarsma R, Verdonschot N, Van der Venne R, Van Kampen A. Avoiding rotational malalignment after fractures of the femur by using the profile of the lesser trochanter: an in vitro study. *Archives of orthopaedic and trauma surgery.* 2005;125(3):184-7.
16. Kim J-J, Kim E, Kim K-Y. Predicting the rotationally neutral state of the femur by comparing the shape of the contralateral lesser trochanter. *Orthopedics.* 2001;24(11):1069.
17. Langer JS, Gardner MJ, Ricci WM. The cortical step sign as a tool for assessing and correcting rotational deformity in femoral shaft fractures. *Journal of orthopaedic trauma.* 2010;24(2):82-8.
18. Krettek C, Miclau T, Gru O, Schandelmaier P, Tscherne H. Intraoperative control of axes, rotation and length in femoral and tibial fractures technical note. *Injury.* 1998;29:29-39.
19. Jeanmart L, Baert AL, Wackenheim A. Computer Tomography of Neck, Chest, Spine and Limbs. *Atlas of Pathological Computer Tomography.* Vol 3. Springer, Berlin, Heidelberg, New York. pp 171-177.
20. Sim E, Höcker K. Locked nailing of fractures of the femur-an analysis of problems and faults in 80 cases. *Unfallchirurg.* 1992;95(12):626.
21. Dunn D, Notley B. Anteversion of the neck of the femur: A method of measurement. *Journal of Bone & Joint Surgery, (Br).* 1952;34(2):181-6.
22. Rippstein J. Zur Bestimmung der Antetorsion des Schenkelhalses mittels zweier Röntgenaufnahmen. *Z Orthop.* 1955;86:345.
23. Kuo TY, Skedros JG, Bloebaum RD. Measurement of femoral anteversion by biplane radiography and computed tomography imaging: comparison with an anatomic reference. *Investigative radiology.* 2003;38(4):221-9.
24. Wissing H, Buddenbrock B. Determining rotational errors of the femur by axial computerized tomography in comparison with clinical and conventional radiologic determination. *Unfallchirurgie.* 1993;19(3):145-57.
25. Starker M, Hanusek S, Rittmeister M, Thoma W. (Validation of computerized tomography antetorsion angle measurement of the femur). *Zeitschrift fur Orthopadie und ihre Grenzgebiete.* 1997;136(5):420-7.
26. Brouwer K, Molenaar J, Van Linge B. Rotational deformities after femoral shaft fractures in childhood: a retrospective study 27-32 years after the accident. *Acta Orthopaedica.* 1981;52(1):81-9.
27. Thoresen BO, Alho A, Ekeland A, Strømsøe K, Follerås G, Haukebø A. Interlocking intramedullary nailing in femoral shaft fractures: a report of 48 cases. *J Bone Joint Surg (Am).* 1985;67A:1313-20.
28. Yildirim AO, Aksahin E, Sakman B, Kati YA, Akti S, Dogan O, Ucaner A, Bicimoglu A. The effect of rotational deformity on patellofemoral parameters following the treatment of femoral shaft fracture. *Arch Orthop Trauma Surg.* 2013;133(5):641-8.
29. Karaman O, Ayhan E, Kesmezacar H, Seker A, Unlu MC, Aydingoz O. Rotational malalignment after closed intramedullary nailing of femoral shaft fractures and its influence on daily life. *Eur J Orthop Surg Traumatol.* 2014;24:1243-7.
30. Lee TQ, Anzel SH, Bennett KA, Pang D, Kim WC. The influence of fixed rotational deformities of the femur on the patellofemoral contact pressures in human cadaver knees. *Clin Orthop Relat Res.* 1994;302:69-74.
31. Kenaway M, Krettek C, Ettinger M, Hankemeier S, Breitmeier D, Liodakis E. The Greater Trochanter-Head Contact Method: A Cadaveric Study With a New Technique for the Intraoperative Control of Rotation of Femoral Fractures. *Journal of Orthopaedic Trauma.* 2011;25(9):549-55.

32. Kendoff D, Citak M, Gardner MJ, Gösling T, Krettek C, Hüfner T. Navigated femoral nailing using noninvasive registration of the contralateral intact femur to restore anteversion. Technique and clinical use. *J Orthop Trauma.* 2007;21:725-30.

Cite this article as: Sharma Y, Mugdum GG, Prabhakara A. Rotational malalignment after closed intramedullary nailing of femoral shaft fractures and its influence on functional outcome. *Int J Res Med Sci* 2016;4:2802-8.