

Case Report

Emergency surgical management of sub-hepatic appendicular perforation with abscess; rare presentation of a common disease: a case report

S. K. Sekendar Ali*, Narendra Nath Mukhopadhyay

Department of General Surgery, Burdwan Medical College and Hospital, West Bengal, India

Received: 18 September 2021

Accepted: 08 October 2021

***Correspondence:**

Dr. S. K. Sekendar Ali,

E-mail: smeokbein@gmail.com

Copyright: © the author(s), publisher and licensee Medip Academy. This is an open-access article distributed under the terms of the Creative Commons Attribution Non-Commercial License, which permits unrestricted non-commercial use, distribution, and reproduction in any medium, provided the original work is properly cited.

ABSTRACT

Subhepatic appendicitis is a very rare presentation that has been rarely reported, accounting for 0.01% of acute appendicitis case. It is difficult to diagnose and prime to be aware of variants, manage such challenging case in emergency setting. We present a case of 29 years male patient with subhepatic perforated appendicitis and its sequelae-abscess and peritonitis who underwent an exploratory laparotomy and appendectomy. The initial diagnosis and surgical management of such patients is challenging due to very rare and atypical presentation in emergency setting. A high level of clinical suspicion, promote decision to operate and skillful surgical approach is discussed with briefly.

Keywords: Appendicitis, Subhepatic appendix, Appendicular perforation, Malrotation caecal pole

INTRODUCTION

Appendicitis is a common presentation in the emergency department worldwide. The appendix, a vestigial organ is a small tubelike structure that belongs to the midgut of the digestive tract system. The most common location of the appendix is retrocecal (74%), followed by the pelvic (21%) region. Other's locations include sub cecal (1.5%), pre-ileal (1%), and post-ileal (0.5%) positions.¹ The site of a normally placed appendix and its classical presentation of appendicitis are well documented in the literature. However, the deviations in the anatomical position of the appendix contribute to the difficulty in diagnosing appendicitis.²⁻⁸ Subhepatic, left sided, intra-herniary, lateral pouch, mesocolic, and lumbar position are rare positions of the appendix. Subhepatic appendicitis could mimic acute cholecystitis, liver abscess, para colic abscess, D1 perforation, resulting in delayed diagnosis and appendiceal rupture.¹⁻⁷

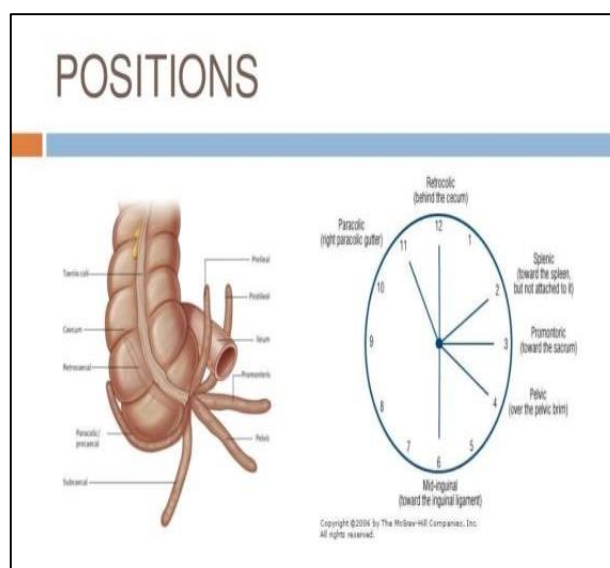


Figure 1: Positions of appendix.

We present a unique and challenging case of a 29 years old male with subhepatic perforated appendicitis with abscess and peritonitis. Diagnosis and management of this unique case are challenging. This case report will make readers aware of a rare presentation and its management. The surgical management of such case is discussed along with a brief review of the literature.

CASE REPORT

History

Our patient was a 29 years old patient, a farmer, resident of Budbud, Purba Durdwan. He presented to our emergency on 13th May 2021 with abdominal pain of 10 days duration. The pain had started in upper abdomen, progressed in intensity over the 5 days and became prominent in the right upper and lower quadrants. It was associated with fever, nausea and anorexia last 6 days and four episodes of nonbilious emesis and by mouth intolerance at home. Initially patient was treated at local hospital last 3 days after that patient referred to BMCH.

Examination

Upon presentation in emergency dept., the patient was hypotensive with blood pressure of 92/50 mmHg, tachycardic with heart rate of 116 beats/minute and febrile to 102°F and he also showed signs of dehydration, CBG was 106 mg/dl. No significant pallor and cyanosis. He was conscious, alert, and oriented with unlabored breathing and normal vesicular breath sounds. His abdomen examination showed left sided abdomen soft but rightsided upper and lower abdomen firm with tenderness and muscle guarding on palpation and also signs of peritonitis such as rebound tenderness and severe pain on percussion were present in right abdomen. No neuromusculoskeletal anomalies were observed and distal pulse were present. The patient was given two bottle boluses of ringer's lactate in the ER with a response of 106/60 mmHg blood pressure.

Investigation

Laboratory tests were performed, which showed a white blood cell count of 19.8×10^9 /L, hemoglobin of 13.6 g/dl, platelet count of 320×10^9 /L, blood urea nitrogen 29 mg/dl, and creatinine of 1.1 mg/dl, as well as a normal liver function test result and normal coagulation profile. In addition, results of hepatitis B, hepatitis C, and human immunodeficiency virus-1 and 2 testing were negative. Urine analysis showed no abnormal findings. An ultrasound sonography (USG) of the patient's abdomen showed subhepatic, subdiaphragmatic and right paracolic intraperitoneal echogenic fluid collection and also collection seen in pelvis. Liver, GB, CBD, PV and pancreas within normal limit and inability to visualize the appendix. Contrast-enhanced computed tomography (CECT) whole abdomen was not done in our setup. The patient was started on intravenous ceftriaxone 1 gm stat,

intravenous metronidazole 500 mg stat, and intravenous paracetamol 1 gm and pantoprazole 40 mg stat before patient shifted to operation room. On the basis of the USG and clinical findings and the clinical presentation, it was deemed necessary to proceed with an emergency laparotomy.

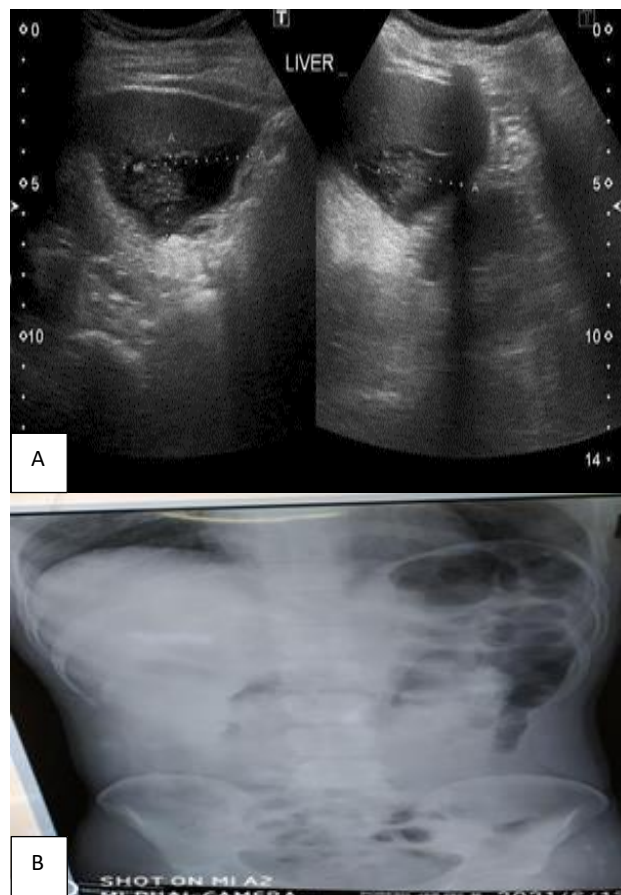


Figure 2: (A) USG Subhepatic collection and (B) str. X-ray.

The differential diagnosis included-1) subcapsular hepatic abscess, 2) acute cholecystitis, 3) paracolic abscess and 4) D1 perforation.

Surgery

Under aseptic precautions and general anesthesia, the patient was placed in a supine position. A midline laparotomy incision was made. Upon entering the peritoneal cavity foul smelling pus with intraperitoneal collection seen and then toileting, a short inflamed ascending colon and hepatic flexure adherent to liver and gallbladder seen and appendix could not be delineated at usual position, then mobilization of ascending colon after that a subhepatic healthy base but tip perforated appendix adhered to subhepatic space with a subhepatic purulent collection was noticed. Localized peritonitis was present. A pyogenic membrane was noticed under the liver and between the liver and the diaphragm. A purulent collection was also noticed in the pouch of Douglas.

After proper toileting of collection, Appendicectomy was performed. Complete hemostasis was achieved. Adequate peritoneal lavage was done with normal saline. After drainage of almost all the fluid, a right subhepatic drain were placed. Abdominal wall closure of the rectus with a polydioxanone suture and skin was closed with ethilon. The patient was extubated in stable condition. No complications occurred. The patient was started with intravenous injection piperacillin and tazobactam 4.5 gm thrice daily, IV infusion metrogyl 500 mg thrice daily, IV injection pantoprazole 40 mg once daily, inf paracetamol 1 gm thrice daily. The patient did well on postoperative day 1 (POD1) and tolerated her diet on POD3, and the drains were subsequently removed on POD4. The patient was discharged on POD5 to home in a good condition and expressed gratitude. Postoperative follow-up at 2 weeks and at 1 month, 3 months and at 6 months showed good healing and recovery of the patient.

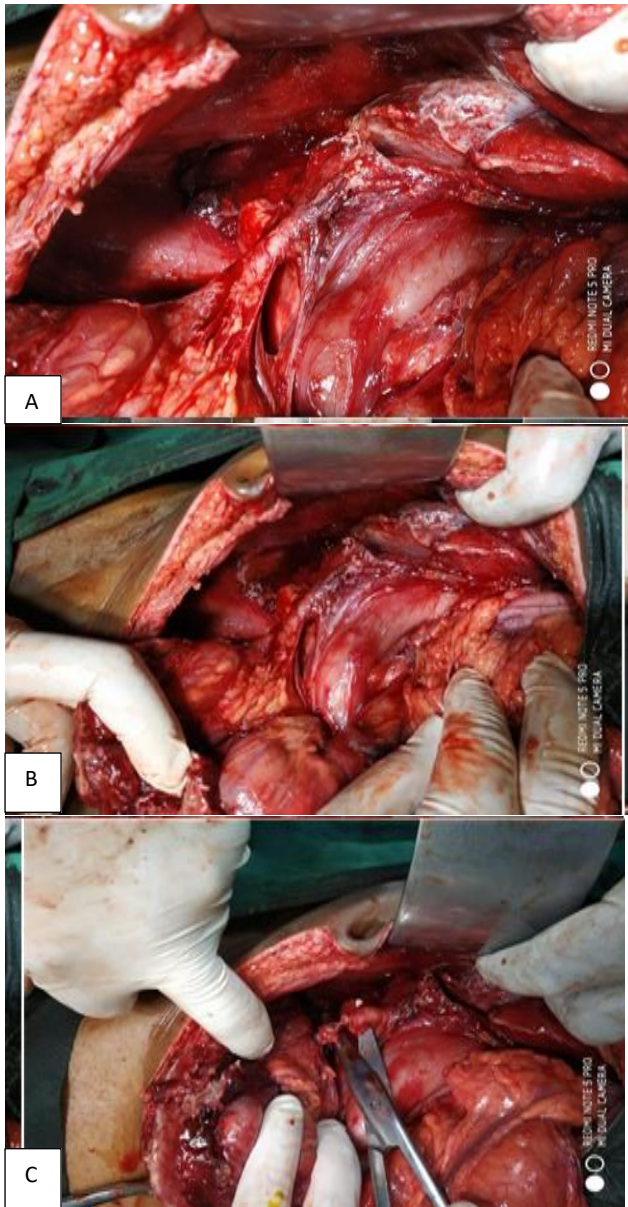


Figure 3 (A- C): Operative pictures.

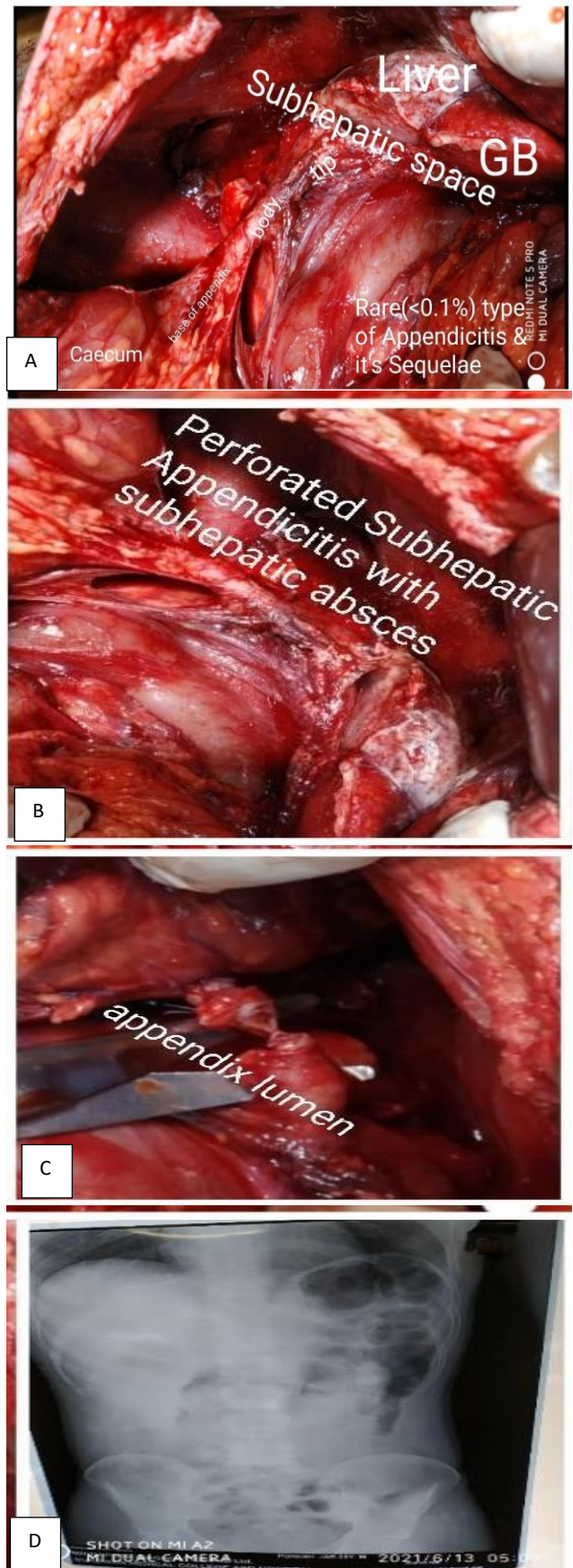


Figure 4: (A-C) Operative finding and (D) str X-ray abdomen.

DISCUSSION

We present a unique and challenging case of a middle-aged male with subhepatic perforated appendicitis and peritonitis. The case is unique in its diagnosis and management, which are challenging. This case report makes readers aware of a rare presentation and its management. The annual incidence rate of subhepatic appendicitis is approximately 0.09 per 100,000 population.² Incomplete rotation and fixation of the intestine due to a defect in fetal gut rotation results in a subhepatic cecum and appendix.⁹ This is a very rare phenomenon. The earliest review of subhepatic cecum and appendix was documented in 1863, as reported in a review by King in 1955.³ Often mimicking hepatobiliary or gastric disease clinically, resulting in a delay in diagnosis of subhepatic appendicitis.^{1,7} This results complications such as sepsis, suppuration, and perforation.² Radiologic imaging thereby is of prime importance in identifying such an anomaly. Due to the availability and ease of performing ultrasound, ultrasound may be the preferred first-line screening modality. High suspicion and caution must be maintained in atypical presentations due to reports of subhepatic appendiceal disease misdiagnosed as liver abscess or cholecystitis.^{1,2} In our patient's case, abdominal ultrasound showed subhepatic fluid collection and inability to visualize the appendix. CT of the abdomen and pelvis provides high sensitivity (100%), specificity (95%), and accuracy (98%) in identifying acute appendicitis.¹⁰ In our patient, a CT scan delineated subhepatic perforated appendicitis with a subhepatic and pelvic collection. The appendix also contained a fecalith. In a subhepatic appendix, a conventional Lanz incision in the right lower quadrant may not be suitable to remove the appendix. In our patient's case, we performed a midline laparotomy due to the subhepatic location of appendix and the possibility of retrocecal, dense adhesions or fibrosis and perforation, which would make a laparoscopic approach an unsafe option, in addition to the fact that open access would provide better tactile input and direct access to appendix. Laparoscopy could also be an option in patients who are clinically stable and not peritonitis in a similar situation for its versatility and diagnostic and therapeutic ability.⁷

CONCLUSION

In conclusion, subhepatic appendicitis is a unique and rare presentation, making its diagnosis and management challenging. Surgeons must be cognizant of this atypical presentation and how patients can present late due to considering other possible nonsurgical causes such as gastritis or biliary colic. Surgeons must also be aware of the various discussed surgical modalities.

Funding: No funding sources

Conflict of interest: None declared

Ethical approval: Not required

REFERENCES

1. Singh S, Jha AK, Sharma N, Mishra TS. A case of right upper abdominal pain misdiagnosed on computerized tomography. *Malays J Med Sci.* 2014;21(4):66-8.
2. Palanivelu C, Rangarajan M, John SJ, Senthilkumar R, Madhankumar MV. Laparoscopic appendectomy for appendicitis in uncommon situations: the advantages of a tailored approach. *Singapore Med J.* 2007;48(8):737-40.
3. King A. Subhepatic appendicitis. *AMA Arch Surg.* 1955;71(2):265-7.
4. Isreb S, Holtham S. Incidental finding of an anterior sub-hepatic appendix during laparoscopic cholecystectomy. *BMJ Case Rep.* 2010;2010:bcr0420102883.
5. Montes-Tapia F, Quiroga-Garza A, Abrego-Moya V. Primary torsion of the vermiform appendix and undescended cecum treated by video-assisted transumbilical appendectomy. *J Laparoendosc Adv Surg Tech A.* 2009;19(6):839-41.
6. Galván-Montaña A, Flores-Nava G, de Lourdes Suárez-Roa M, Salazar-Herrera MC, Lavalle-Villalobos A. Subhepatic appendicitis with subdiaphragmatic abscess in a pediatric patient without intestinal malrotation: case report. *Cir Cir.* 2010;78(1):79-81.
7. Rappaport WD, Warneke JA. Subhepatic appendicitis. *Am Fam Physician.* 1989;39(6):146-8.
8. Kim S, Lim HK, Lee JY, Lee J, Kim MJ, Lee SJ. Ascending retrocecal appendicitis: clinical and computed tomographic findings. *J Comput Assist Tomogr.* 2006;30(5):772-6.
9. Nayak SB, George BM, Mishra S, Surendran S, Shetty P, Shetty SD. Sessile ileum, subhepatic cecum, and uncinata appendix that might lead to a diagnostic dilemma. *Anat Cell Biol.* 2013;46(4):296-8.
10. Chalazonitis AN, Tzovara I, Sammouti E, Ptohis N, Sotiropoulou E, Protopapa E et al. CT in appendicitis. *Diagn Interv Radiol.* 2008;14(1):19-2.

Cite this article as: Ali SKS, Mukhopadhyay NN. Emergency surgical management of sub-hepatic appendicular perforation with abscess: rare presentation of a common disease: a case report. *Int J Res Med Sci* 2021;9:3478-81.