

Case Report

Chronic myeloid leukemia on imatinib with recurrent sub-dural haemorrhage

Ambati Bhavani*, Palanki Satya Dattatreya, Vinukonda Shyamala

Department of Medical Oncology, Omega Hospitals, Hyderabad, Telangana, India

Received: 27 September 2021

Accepted: 02 November 2021

*Correspondence:

Dr. Ambati Bhavani,

E-mail: bhavanireddy.mbbs@gmail.com

Copyright: © the author(s), publisher and licensee Medip Academy. This is an open-access article distributed under the terms of the Creative Commons Attribution Non-Commercial License, which permits unrestricted non-commercial use, distribution, and reproduction in any medium, provided the original work is properly cited.

ABSTRACT

Imatinib is an FDA approved first-line treatment for Philadelphia-positive CML. It is a selective tyrosine kinase inhibitor specifically targeting BCR-ABL, c-KIT, PDGFRA. It has been reported with low incidence of adverse effects and high tolerability, with haemorrhagic events being a rare complication. We report here a case of 51-year-old female patient with chronic myeloid leukemia who was on high dose imatinib experienced recurrent sub-dural haemorrhage. This case report emphasizes on the need to consider Sub dural haemorrhage as an unusual cause of headache associated with vomiting in a patient taking high dose of imatinib.

Keywords: Chronic myeloid leukemia, Imatinib, Subdural hemorrhage

INTRODUCTION

Chronic myeloid leukaemia is a myeloproliferative disease caused due to over production of granulocytes by myeloid progenitor cells. Philadelphia chromosome is an abnormal chromosome which is a genetic hallmark of CML caused due to translocation of (9:22) which contains BCR-ABL fusion gene.¹ Imatinib is used to treat CML, gastro-intestinal stromal tumours, Dermatofibrosarcoma protuberans and other malignancies. In CML it inhibits synthesis of abnormal tyrosine kinase protein production by BCR-ABL gene. This drug has revolutionised the treatment of CML with low incidence of minor side effects like nausea, vomiting, diarrhoea, weight gain, edema and haemorrhagic episodes. Imatinib is now the standard initial treatment of CML.² We report here a case of recurrent subdural haemorrhage in a 51-year-old female patient diagnosed with CML treated on high dosage of imatinib.

CASE REPORT

A 51-year-old female patient presented with chief complaints of generalised weakness and pigmentation of

the skin. On evaluation, complete blood picture showed haemoglobin: 9.8 mg/dl, Total white blood cell counts 2, 92,000 and platelet count: 5.1 lakh. She was further evaluated with bone marrow aspiration and biopsy which confirmed chronic myeloid leukemia in January 2016. Karyotyping showed Philadelphia chromosome positive. She was initially started on imatinib of dose 400 mg once daily and hydroxyurea 500 mg thrice daily. The patient had complete haematological response after 1 month and tolerated Imatinib with no side effects. Real time quantitative polymerase chain reaction (RQ PCR) of BCR ABL was done which showed 24.83%, 2.86%, 0.646% and 0.082% at 3, 6, 9 and 12 months respectively after starting imatinib. The patient was on an ongoing treatment of Imatinib and the blood counts were maintained within normal limits. After 18 months of beginning Imatinib RQ PCR value of 0.104% (increased) was obtained, and the dosage was increased to 600 mg once daily. Subsequently after 3 months RQ PCR value of 0.007% (decreased) was obtained. Later after 3 months RQ PCR BCR ABL increased to 0.029% and Imatinib dose was further increased to 800mg once daily. Further when RQ PCR BCR ABL was done it was less than detectable limits, so the patient was ongoing with

imatinib 800 mg per day. After 15 months of high dose imatinib, the patient presented with complaints of headache associated with vomiting, without any history of trauma. She was diagnosed with subdural haemorrhage on CT brain. A complete blood count was done at that time which were within normal limits. So, the patient underwent right frontoparietal craniotomy to evacuate the haemorrhage. Post-operative period was uneventful. The patient was continuing on imatinib 800 mg per day. Further after 20 months of first episode of subdural haemorrhage, she experienced a second episode of spontaneous subdural haemorrhage as shown in figure 1. She then underwent left frontotemporal craniotomy and evacuation of SDH. Post operatively she had low platelet count (<50,000). The patient received single donor platelet transfusion, following which her platelet count improved. Bone marrow aspiration and biopsy showed evidence of remission in a known case of Chronic myeloid leukemia. The patient was evaluated for several other blood work up such as; D dimer: 5870 (elevated), FDP: 20 (elevated), fibrinogen: 320 (normal), COOMBs test (Direct and indirect): Negative, platelet aggregation studies: Normal, alpha-2 plasmin inhibitor: 120% (Normal: 80-140%), coagulation profile: Normal which was done 6 months ago. Currently her RQ PCR BCR ABL is 0.387% which is increased compared to 0.058%. Hence, she is started on bosutinib to prevent the progression of CML.

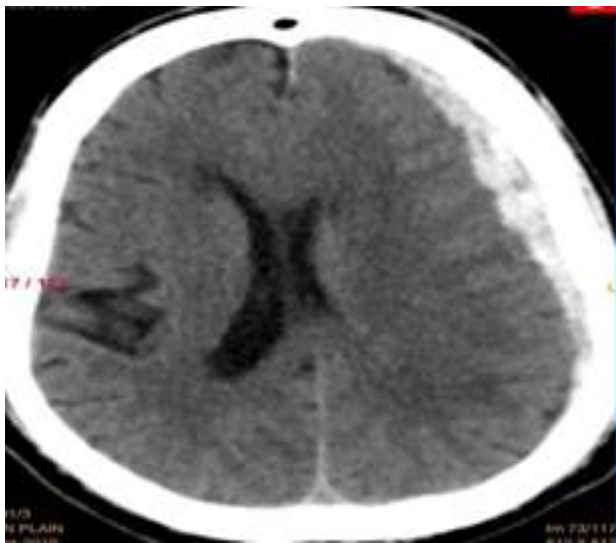


Figure 1: Subdural haemorrhage on left side.

DISCUSSION

The annual incidence of chronic subdural hematoma has been reported to be 1-15 cases per 1,00,000 population.³ Recent studies have shown higher incidence, probably due to better imaging techniques. The data indicates that in patients treated with imatinib, SDH occurs in 5% of those in blastcrisis, 1% in accelerated phase, and 0.6% in the chronic phase.⁴

Our patient was in the chronic phase of CML. She developed a spontaneous SDH twice after long term administration of Imatinib high dosage (800 mg), unaccompanied with any disturbances in the platelet aggregation studies or alpha-2 plasmin inhibitor or thrombocytopenia. Bleeding without thrombocytopenia is less frequent with tyrosine kinase inhibitors. It has been reported that 7 out of 121 advanced CML patients treated with imatinib, initially at 600 mg/day were diagnosed with non-traumatic subdural haemorrhage.⁵ All the patients who developed subdural haemorrhage were within 1-42 weeks after starting the therapy. In our patient, subdural haemorrhage first developed 60 weeks after increasing the imatinib dose to 800 mg daily. Although, there is no definite evidence that only high dose Imatinib is associated with the development of major hemorrhagic events.

It has been reported that marked but reversible inhibition of platelet aggregation may contribute to the cause of bleeding diathesis in these patients.⁶ But the platelet aggregation studies in our patient were as follows; collagen Aggregation: 81.09% (normal: 75-93), epinephrine aggregation: 72.57% (normal: 67-88), ADP aggregation: 91.04% (67-97), arachidonate aggregation: 86.40% (normal: 72-94), ristocetin aggregation: 99.30% (normal: 73-104). These platelet aggregation studies were done 1 week after the 2nd episode of chronic subdural haemorrhage which were all within normal limits with no abnormality detected.

Decreased levels of alpha 2-plasmin inhibitor in Philadelphia chromosome-positive lymphoblastic leukemia patients who had suffered hemorrhagic episodes while on Imatinib dose of 400mg/day were reported.⁷ Studies showed that there will be development of clinical bleeding due to abnormal fibrinogenolysis when Alpha-2 PI levels fall below 60% of normal, and heterozygous patients with alpha 2-PI deficiency exhibit hemorrhagic diathesis after events such as trauma, surgery and dental extractions.⁸⁻¹⁰ However in our patient alpha-2 plasmin inhibitor level was 120% (Normal: 80-140%), which was checked 2 weeks after the SDH.

CONCLUSION

Our case report describes the occurrence of chronic subdural haemorrhage in a CML patient treated with Imatinib 800 mg/day with no coagulation abnormalities, with no history of any recent trauma, thrombocytopenia, or on any anticoagulation medication. This suggests that the subdural haemorrhage may be caused by imatinib due to unknown mechanism. It produces haemostatic abnormalities independent of thrombocytopenia. There is a need of additional investigations and studies to establish the mechanism of subdural haemorrhage in these patients.

Funding: No funding sources

Conflict of interest: None declared

Ethical approval: Not required

REFERENCES

1. Nash I. Chronic myeloid leukemia. *N Engl J Med.* 1999;341:765.
2. O'Brien SG, Guilhot F, Larson RA. Imatinib compared with interferon and low-dose cytarabine for newly diagnosed chronic-phase chronic myeloid leukemia. *N Engl J Med.* 2003;348:994-1004.
3. Chen JC, Levy ML. Causes, epidemiology, and risk factors of chronic subdural hematoma. *Neurosurg Clin North Am.* 2000;11(3):399-406.
4. Druker BJ, Sawyers CL, Capdeville R, Ford JM, Baccarani M, Goldman JM. Chronic myelogenous leukemia. *ASH Education Program Book.* 2001;2001(1):87-112.
5. Song KW, Rifkind J, Al-Beirouti B. Subdural hematomas during CML therapy with imatinib mesylate. *Leuk Lymphoma.* 2004;45:1633-6.
6. Quintás-Cardama A, Han X, Kantarjian H, Cortes J. Tyrosine kinase inhibitor-induced platelet dysfunction in patients with chronic myeloid leukemia. *Blood.* 2009;114:261-3.
7. Matsue K, Aoki T, Odawara J, Kimura S, Yamakura M, Takeuchi M. Haemorrhagic complications associated with reduced alpha2-plasmin inhibitor during imatinib use in a patient with Philadelphia chromosome-positive acute lymphoblastic leukaemia. *Leuk Res.* 2009;33:867-9.
8. Okajima K, Kohno I, Tsuruta J, Okabe H, Takatsuki K, Binder BR. Direct evidence for systemic fibrinogenolysis in a patient with metastatic prostatic cancer. *Thromb Res.* 1992;66:717-27.
9. Kluft C, Vellenga E, Brommer EJ, Wijngaards G. A familial hemorrhagic diathesis in a Dutch family: an inherited deficiency of alpha 2-antiplasmin. *Blood.* 1982;59:1169-80.
10. Favier R, Aoki N, de Moerloose P. Congenital alpha (2)-plasmin inhibitor deficiencies: a review. *Br J Haematol.* 2001;114:4-10.

Cite this article as: Bhavani A, Dattatreya PS, Shyamala V. Chronic myeloid leukemia on imatinib with recurrent sub-dural haemorrhage. *Int J Res Med Sci* 2021;9:3726-8.