

Original Research Article

Functional outcome of AO type C distal humerus fractures treated with internal fixation using olecranon osteotomy in a tertiary care hospital

Simranpreet Singh, Mudasser Arif*, Sanjeev Gupta

Department of Orthopaedics, Government Medical College, Jammu, India

Received: 29 September 2021

Revised: 01 October 2021

Accepted: 02 October 2021

*Correspondence:

Dr. Mudasser Arif,

E-mail: simransingh2681@gmail.com

Copyright: © the author(s), publisher and licensee Medip Academy. This is an open-access article distributed under the terms of the Creative Commons Attribution Non-Commercial License, which permits unrestricted non-commercial use, distribution, and reproduction in any medium, provided the original work is properly cited.

ABSTRACT

Background: Distal humerus fractures are commonly encountered in the orthopedic emergency. The goals in the treatment of these fractures are aimed at perfect anatomical reduction which could be obtained by open reduction and internal fixation.

Methods: A prospective cohort study was conducted from July 2019 to December 2020 in Government Medical College, Jammu on 35 patients with AO type C distal humerus fractures. Functional outcomes were recorded and evaluated at end of 6 months using mayo elbow performance score (MEPS) score. 3 patients were lost in the follow up and were not included in the study.

Results: 32 patients in the age group 20-65 years were included in the study with a mean age of 42.5 years. Males outnumbered females in ratio of 3:1. Patients undergoing olecranon osteotomy for fixation of distal humerus fractures had mean elbow flexion (121 ± 8.3), loss of elbow extension (10.3 ± 4.2). The functional outcome was made using MEPS score with a mean of 84 ± 8.4 at final follow up.

Conclusions: In this study we concluded that olecranon osteotomy approach provided better outcome. Intraarticular distal humerus fractures was better visualized with olecranon osteotomy approach and allowed early mobilization.

Keywords: AO type C distal humerus, Internal fixation, Olecranon osteotomy

INTRODUCTION

Distal humerus fractures common in elderly with osteoporotic bone and in adults with high energy trauma. Generally, incidence of distal humerus fractures 2%.^{1,2} Most of the fractures were AO type C, occurred in women, type C fractures are relatively more as compared to type A and B.⁴ Still the treatment option of choice is open reduction and internal fixation. The approaches affect the reduction and functional outcome.

Approaches to distal humerus include triceps sparing, splitting, triceps reflecting and olecranon osteotomy approaches.^{5,6}

The objective of the present study is to evaluate clinically and radiologically the type of injury and to analyze the results of using olecranon osteotomy approach while treating distal humerus fractures AO type C.

METHODS

A prospective cohort study was conducted in Government Medical College, Jammu from July 2019 to December 2020 after seeking approval from institutional ethics committee (IEC). The patients were followed up for a period of 6 months post-surgery. Statistical analysis done using statistical package for the social sciences (SPSS) and Epi-info.

Source and method of collection

Out of the 32 patients, 24 were females and 8 were males with mean age of 42.5 years. Mode of injury being 17 patients had road traffic accidents and 15 from self-fall. According to AO classification.⁴ There were 11 cases of type C1, 2 cases of type C3, and 9 cases of type C3.

Inclusion and exclusion criteria

Patients in the age group 20-65 years, who were willing to participate in the study, without any co-morbidities were included in the study. Patients greater than 65 years of age with significant osteoporosis, with associated injuries like head injury, other long bone fractures Patients having comorbidities like hypertension and type 2 diabetes mellitus were excluded from the study. Signed informed consent had been taken from all patients.

Surgical technique

Patients operated with 1st to 3rd day of injury averaging 2 days. All patients' undergone operative treatment under general anesthesia and some under brachial plexus block with tourniquet application. All patient's undergone open reduction and internal fixation according to AO principles. The exposure for distal humerus was obtained by a chevron osteotomy (Figure 1).¹⁶

First the inter condylar segment is reduced temporarily with k wires and articular surface reconstructed using 4 mm cc screws passed from lateral to medially and the inter condylar segment reduced to distal metaphysis using 3.5 system distal humerus locking plate applied in 90 90 fashion both medially and dorsolateral (Figure 2).^{7,8} Whole procedure has been approached by intra articular chevron olecranon osteotomy. Olecranon osteotomy was fixed with tension band wiring in all cases (Figure 3).⁹

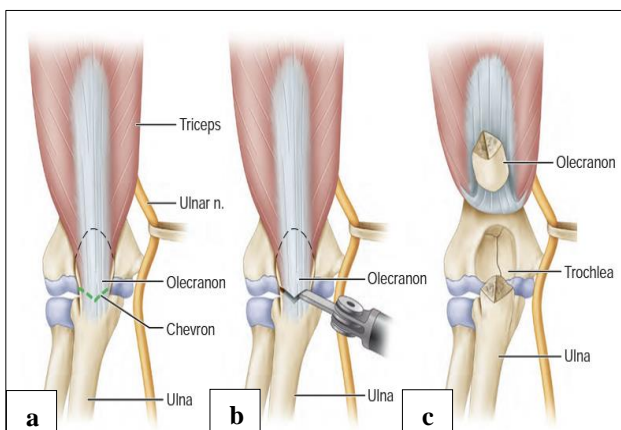


Figure 1: Olecranon osteotomy approach (a) olecranon is marked in shape of V or chevron, (b) oscillating saw is used for osteotomy, and (c) osteotomized fragment is elevated proximally and ulnar nerve is isolated.¹⁶

Postoperative rehabilitation

Above elbow splint in 90-degree elbow flexion has been applied to patients for 2 weeks. Skin sutures were removed on post-operative day (POD) 14. After 2 weeks splint was removed and there by active and passive mobilization started. The patients were followed up for 6 months both clinically and radio logically. The mayo elbow performance score (MEPS) was used as an objective measure of outcome.¹⁰

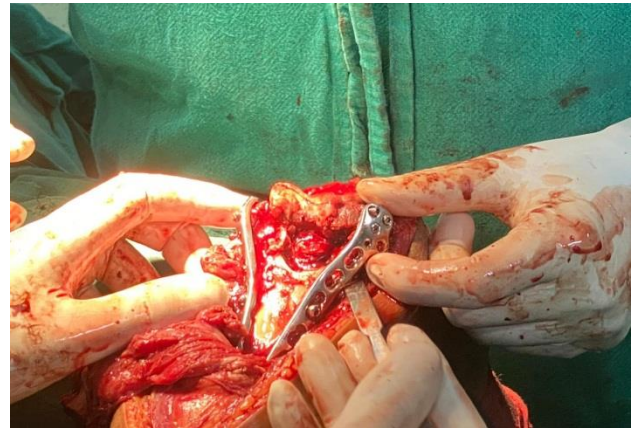

Figure 2: Dual plating in one of the patients medially and dorsolateral.

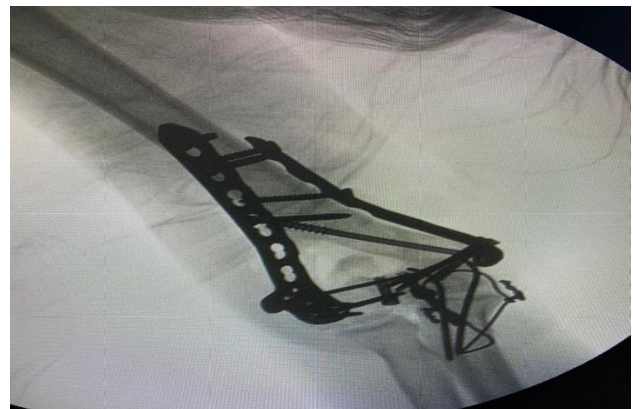

Figure 3: Post op fixation with dual plate using olecranon osteotomy approach and fixed using TBW.

RESULTS

This was a prospective study done on 32 patients in GMC Jammu from July 2019 to December 2020. During this study, bimalleolar fractures were more commonly seen in males (24 patients, 75%) than females (8 patients, 25%) as depicted in Figure 4. Right elbow (18 patients, 56.25%) was more commonly injured as compared to left one (14 patients, 43.75%).

In our study group we had 3 patients (14.58%) in age group of 20-30 years, 6 patients (20.83%) in age group of 31-40 years, 16 patients (33.33%) in age group of 41-50 years, 7 patients (22.91%) in age group of 51-65 years shown in

Table 1. The mean age of patients in this study was 42.5 years. Primarily, mode of injury was road traffic accident (25 patients, 78.12%) followed by fall (5 patients, 15.66%), remaining cases sustained injury due to fall of heavy object over elbow (2 patients, 6.25%). The patients were followed up for mean time of 24 month (range 16-32 months) in both the groups. Radiological evidence of union was found in all patients with mean time of 16 weeks duration. There was 1 report of superficial wound infection which was treated with debridement and secondary closure. The results according to mayo elbow performance scoring was excellent in 14 patients, good in 15 patients, fair in 2 patients and poor in one patient, with mean mayo score of 84 ± 8.4 (Figure 5).

The mean elbow flexion was found to be 121 ± 8.3 and the limitation of elbow extension were 10.3 ± 4.2 .

Table 1: Age wise distribution of patients.

Age distribution (in years)	Number of patients	Percentage
20-30	3	9.40
31-40	6	18.75
41-50	16	50
51-65	7	21.85
Total	32	

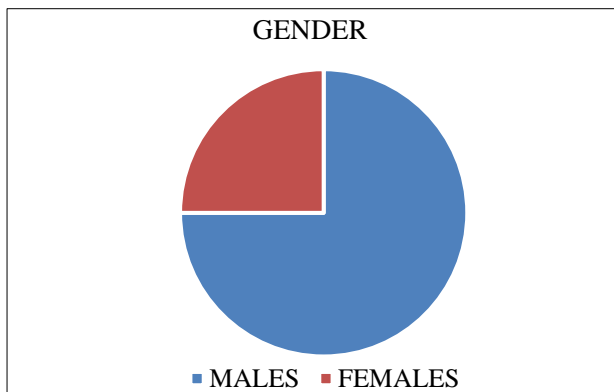


Figure 4: Gender distribution.

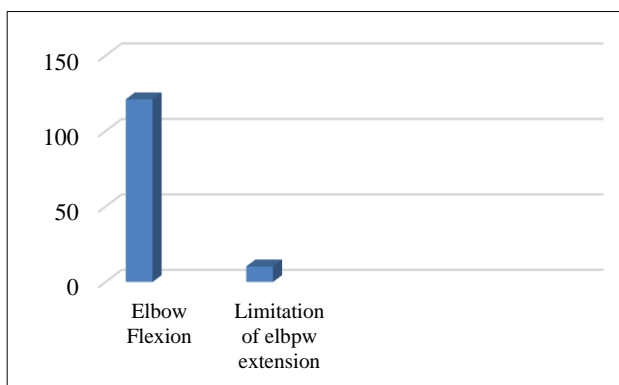


Figure 5: The mean MAYO score at the end of 6 months.

DISCUSSION

In this study we did fixation with olecranon osteotomy in treatment of type C distal humerus and evaluated according to functional score by MAYO scoring system. We found significantly better functional outcome in patients with olecranon osteotomy.

The functional outcome following distal humerus fracture depends on restoration of joint congruency, stable fixation and early mobilization.¹¹ The surgical approach plays an important role in restoration of joint congruency, stable fixation. The approaches available are triceps splitting, triceps sparing, triceps reflecting and olecranon osteotomy approach. In this study we used olecranon osteotomy approach for exposing distal humerus. In this study we used chevron osteotomy in order to minimize nonunion risk in olecranon osteotomy and tension band wiring was used for fixing back. Another approach commonly used is Campbell's triceps splitting approach.^{12,13} The disadvantage of triceps sparing approach is inadequate exposure of articular surface, stable articular reduction gives good functional outcome.^{14,15} The functional outcome of these distal humerus fracture is worse with increasing number of fragments.

In this study all patients underwent double plating in 90° fashion. In spite of type of fracture pattern and implant type, postoperative rehabilitation was main factor affecting functional outcome. With olecranon osteotomy elbow range of motion was started at 2 weeks postoperatively. Hence early range of motion main factor in deciding functional outcome.

In this study range of motion evaluated at 6 months post operatively which resulted in mean elbow flexion of (121 ± 8.3) and mean limitation of elbow extension of 10.3 ± 4.2 .

Limitations

Sample size taken for study was small and a future study with a larger sample size is desired. Males outnumbered females, so groups were not comparable on basis of gender.

CONCLUSION

In this study we concluded that olecranon osteotomy approach provided better outcome and exposure for distal humerus fractures. Intraarticular distal humerus fractures was better visualized with olecranon osteotomy approach and allowed early mobilization. Hence, fixation of distal humerus fracture using olecranon osteotomy approach is a good option to attain optimal functional outcome.

Funding: No funding sources

Conflict of interest: None declared

Ethical approval: The study was approved by the Institutional Ethics Committee

REFERENCES

- Charissoux JL, Vergnenegre G, Pelissier M, Fabre T, Mansat P. Epidemiology of distal humerus fractures in the elderly. *Orthop Traumatol Surg Res.* 2013;99(7):765-9.
- Morrey BF. Fractures of the distal humerus. Role of elbow replacement. *Orthop Clin North Am.* 2000;31(1):145-54.
- Varecka TF, Myeroff C. Distal Humerus Fractures in the Elderly Population. *J Am Acad Orthop Surg.* 2017;25(10):673-83.
- Dey Hazra R-O, Lill H, Jensen G, Imrecke J, Ellwein A. Fracture-pattern-related therapy concepts in distal humeral fractures. *Frakturspezifische Therapiekonzepte der distalen Humerus fraktur. Obere Extrem.* 2018;13(1):23-32.
- Sharma S, John R, Dhillon MS, Kishore K. Surgical approaches for open reduction and internal fixation of intra-articular distal humerus fractures in adults: A systematic review and meta-analysis. *Injury.* 2018;49(8):1381-91.
- Wilkinson JM, Stanley D. Posterior surgical approaches to the elbow: A comparative anatomic study. *J Shoulder Elb Surg.* 2001;10(4):380-2.
- Stoffel K, Cunneen S, Morgan R, Nicholls R, Stachowiak G. Comparative stability of perpendicular versus parallel double-locking plating systems in osteoporotic comminuted distal humerus fractures. *J Orthop Res.* 2008;26(6):778-84.
- Sarkhel S, Bhattacharyya S, Mukherjee S. Condylar orientation plating in comminuted intraarticular fractures of adult distal humerus. *Indian J Orthop.* 2015;49(5):523-8.
- Ali AA, Atkinson HD, Buckley S, Matar HE, Garlick NI. Surgical interventions for treating fractures of the olecranon in adults. *Cochrane Database Syst Rev.* 2012;10.
- The Mayo Clinic Performance Index for the Elbow. *J Orthopaed Trauma.* 2006;20(8):127.
- Bégué T. Articular fractures of the distal humerus. *Orthop Traumatol Surg Res.* 2014;100:55-63.
- Wagener ML, Dezillie M, Hoendervangers Y, Eygendaal D. Clinical results of the re-fixation of a Chevron olecranon osteotomy using an intramedullary cancellous screw and suture tension band. *Strateg Trauma Limb Reconstr.* 2015;10(1):1.
- Schildhauer TA, Nork SE, Mills WJ, Henley MB. Extensor mechanism-sparing paratricipital posterior approach to the distal humerus. *J Orthop Trauma.* 2003;17(5):374-8.
- Islam SU, Glover AW, Waseem M. Challenges and Solutions in Management of Distal Humerus Fractures. *Open Orthop J.* 2017;11:1292-307.
- O'driscoll SW. Optimizing stability in distal humeral fracture fixation. *J Shoulder Elbow Surg.* 2005;14(1):186-94.
- Canale ST, Beaty JH. *Campbell's Operative Orthopaedics*, 12th edition. Philadelphia: Mosby. 2013;2869.

Cite this article as: Singh S, Arif M, Gupta S. Functional outcome of AO type C distal humerus fractures treated with internal fixation using olecranon osteotomy in a tertiary care hospital. *Int J Res Med Sci* 2021;9:3298-301.