

Original Research Article

Evaluation of the short-term outcome of unilateral urethral mobilization for the management of bulbar urethral stricture

Kartik Chandra Ghosh^{1*}, Prodyut Kumar Saha², Masud Ahmed³,
Farhad Mahmud⁴, Uttam Karmaker²

¹Department of Urology Bangabandhu Sheikh Mujib Medical University (BSMMU), Dhaka, Bangladesh

²Department of Urology, Dhaka Medical College, Dhaka, Bangladesh

³Department of Urology, Mugda Medical College, Dhaka, Bangladesh

⁴Department of Pathology, Colonel Malek Medical College, Manikganj, Bangladesh

Received: 30 October 2021

Revised: 22 November 2021

Accepted: 23 November 2021

*Correspondence:

Dr. Kartik Chandra Ghosh,

E-mail: kariul@hotmail.com

Copyright: © the author(s), publisher and licensee Medip Academy. This is an open-access article distributed under the terms of the Creative Commons Attribution Non-Commercial License, which permits unrestricted non-commercial use, distribution, and reproduction in any medium, provided the original work is properly cited.

ABSTRACT

Background: In modern urology, successful male urethral reconstruction poses a continuing challenge.

Methods: It was a quasi-experimental study conducted in the department of urology, Dhaka medical college hospital, Dhaka, Bangladesh between January 2010 to December 2011. 35 patients having bulbar urethral strictures admitted in the department were study participants. All the participants underwent unilateral urethral mobilization, for buccal mucosa graft urethroplasty and followed up at least six months. RGU and MCU was done when peak flow was <15 ml /sec in uroflowmetry. Urethroscopy was done at 3rd and 6th month. The statistics used to analyze the data were descriptive statistics, and the tests done were student's t-test, chi-square test, ANOVA, and Fisher exact test.

Results: The length of strictures was observed ≤3 cm among 31% (n=11) and >3 cm among 69% (n=24) patients. As the immediate postoperative outcome among the participants, we found the mean peak urinary flow rate (Q_{max}), 15.3±1.2 and voided urine volume (ml), 328.8±50. Finally, as the postoperative outcome after 6 months among the participants, we found the mean peak urinary flow rate (Q_{max}), 24.2±2.9; voided urine volume (ml), 330.8±50.1 and PVR (ml), 11.6±3.3. In this study, some potential complications were bleeding and wound infection which were found among 11.43% and 17.14% patients respectively.

Conclusions: Considering the satisfactory outcomes and lower complications unilateral urethral mobilization procedure can be considered as an effective treatment method for the management of bulbar urethral stricture.

Keywords: Outcome, Buccal mucosal graft, Unilateral, Urethral mobilization

INTRODUCTION

Numerous surgical techniques have been described to repair bulbar urethral strictures according to the stricture length and location. In Bangladesh, in every year, for the management of bulbar urethral stricture, urologists applied different methods of urethral mobilization for buccal mucosal graft urethroplasty. Recently, some urologists in different countries noticed long-term good

outcome of unilateral urethral mobilization for the management of buccal mucosal graft urethroplasty. The term 'urethral stricture' refers to scarring process involving the spongy erectile tissues of the corpus spongiosum causing spongio-fibrosis that is composed of dense collagen and fibroblasts. As these scars contract, narrowing occurs of the lumen of the urethra which restricts urine flow and causes dilatation of the proximal urethra. Further obstruction may cause secondary complications in the urinary tract like; urethritis,

prostatitis, periurethral abscess, urethra-cutaneous fistula, hypertrophied bladder muscle, and secondary bladder stones. Finally, chronic urinary stasis due to severe stricture causes hydronephrosis, and even patient may present with renal failure.^{1,2} Urethral reconstruction with excision of the stricture segment and end-to-end anastomosis is successful in more than 95% of patients with a stricture of up to 2 cm in length in proximal bulbar urethra. Patients with long anterior urethral stricture (>2 cm) is suitable for dorsal or ventral onlay graft urethroplasty because end-to-end urethroplasty in such cases cause postoperative chordee formation.^{3,4} Continuous efforts are made in different centers over the last 50 years to fine out an ideal procedure of management with maximum benefits and even in one stage urethroplasty.^{5,6} Buccal mucosa is familiar to reconstructive urologists, and is the most preferred graft for reconstruction of long bulbar urethral stricture, but placement of a graft either ventrally, dorsally or laterally is still controversial.⁷ Dorsal onlay graft has obvious advantages over the ventral onlay graft urethroplasty.⁸ Dorsal placement of buccal graft on the corporal bodies provides the advantages of mechanical support, vascular supply leading to neo-vascularization, maintenance of caliber of a reconstructed urethra and decreased incidence of graft necrosis, urethra-cutaneous fistula, saccule formation which are commonly seen in ventral onlay grafts urethroplasty.⁹ In the dorsal onlay graft urethroplasty, the bulbar urethra is mobilized circumferentially and rotated 180 degrees and opened along its dorsal surface.¹⁰ Recently, a surgical technique is described to preserve the vascular supply on one side of the bulbo-spongiosum muscle, the central tendon of the perineum, and the perineal nerves using a dorsolateral onlay urethroplasty by unilateral urethral mobilization, so ischemia, nerve damage to the bulbo-spongiosum muscle, and the perineal nerves can be avoided and improve the success rate.^{10,11} The main objective of the present study was to evaluate the short-term outcome of unilateral urethral mobilization for the management of bulbar urethral stricture.

Objective

Objective of the study was to evaluate the short-term outcome of unilateral urethral mobilization for the management of bulbar urethral stricture.

METHODS

The present quasi-experimental study was conducted in the department of urology, Dhaka medical college hospital, Dhaka, Bangladesh during the period from January 2010 to December 2011. In total 35 patients having bulbar urethral strictures admitted in the above department were selected as study participants. All the participants were undergoing unilateral urethral mobilization, for buccal mucosa graft urethroplasty. Urethroscopy was done at 3rd and 6th month post-operatively. A written informed consent was taken before

the interview. The respondents had every right to quit the interview at any time before or once the interview had started. It was made sure to the respondents that his name or information provided by him should be kept strictly confidential and will be used for the study purpose only. Informed consent was confidentiality of respondents was maintained; Information obtained during the research work was not used for any other purpose except research. All interview questionnaires were checked for completeness and correctness before date entry. All the data were processed, analyzed and disseminated by Microsoft-office and SPSS version 13 programs as per need.

Inclusion criteria

Patients having primary and recurrent bulbar urethral stricture and stricture length 2 cm to 6 cm were included in the study.

Exclusion criteria

Strictures at posterior and distal penile urethra and patients having urethral malignancy were excluded from the study.

RESULTS

In total 35 patients underwent unilateral urethral mobilization, having bulbar urethral strictures were evaluated regarding the short-term outcome in this study. The mean age of the participants was 37.4±8.2 years. The majority of the participants were from ≥30 years age groups. In this study, in analyzing the baseline findings among the participants we observed, urinary tract infection was found among 21 participants which was 45.7%. Besides these, the mean length of stricture (cm), peak urinary flow rate (Q_{max}), voided urine volume (ml) and PVR (ml) were found 3.6±0.8, 7.8±1.5, 210.5±61.8 and 57.4±6.2 respectively. Among all the participants, the length of strictures was observed ≤ 3 cm among 31% (n=11) and >3 cm among 69% (n=24) patients. As the immediate postoperative outcome among the participants, we found the mean peak urinary flow rate (Q_{max}), 15.3±1.2 and voided urine volume (ml), 328.8 ± 50. On the other hand, as the postoperative outcome after 3 months among the participants, we found the mean peak urinary flow rate (Q_{max}), 21.2±1.2 and voided urine volume (ml), 331.8±25.1. Finally, as the postoperative outcome after 6 months among the participants, we found the mean peak urinary flow rate (Q_{max}), 24.2±2.9; voided urine volume (ml), 330.8±50.1 and PVR (ml), 11.6±3.3. In this study, some potential complications were bleeding and wound infection which were found among the 11.43% and 17.14% patients respectively. Besides these, urethra-cutaneous fistula, recurrence of stricture and optical instrumentation were found among 2.86%, 8.57% as well as the-another 8.57% patients respectively.

Table 1: Age distribution of the participants, (n=35).

| Age (years) | N | Percentages (%) |
|-------------|----------|-----------------|
| <30 | 6 | 17.14 |
| 30-40 | 15 | 42.86 |
| ≥40 | 14 | 40.00 |
| Mean ± SD | 37.4±8.2 | |

Table 2: Baseline findings among the participants, (n=35).

| Baseline findings | Mean value |
|--|------------|
| Length of stricture (cm) | 3.6±0.8 |
| Peak urinary flow rate (Q _{max}) | 7.8±1.5 |
| Voided urine volume (ml) | 210.5±61.8 |
| PVR (ml) | 57.4±6.2 |
| Urinary tract infection | 21 (45.7) |

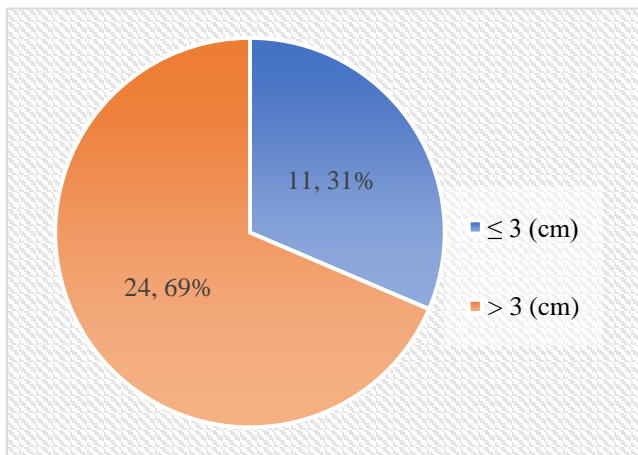


Figure 1: Length of stricture among the participants, (n=35).

Table 3: Immediate postoperative outcome among the participants, (n=35).

| Immediate outcome | Mean value |
|--|------------|
| Peak urinary flow rate (Q _{max}) | 15.3±1.2 |
| Voided urine volume (ml) | 328.8±50.1 |

Table 4: Post-operative outcome after 3 months among the participants, (n=35).

| Outcome | Mean value |
|--|------------|
| Peak urinary flow rate (Q _{max}) | 21.2±1.2 |
| Voided urine volume (ml) | 331.8±25.1 |

Table 5: Post-operative outcome after 6 months among the participants, (n=35).

| Outcome | Mean value |
|--|------------|
| Peak urinary flow rate (Q _{max}) | 24.2±2.9 |
| Voided urine volume (ml) | 330.8±50.1 |
| PVR (ml) | 11.6±3.3 |

Table 6: Complications encountered by the patients, (n=35).

| Complications | N | Percentages (%) |
|---------------------------|---|-----------------|
| Bleeding | 4 | 11.43 |
| Wound infection | 6 | 17.14 |
| Urethro-cutaneous fistula | 1 | 2.86 |
| Recurrence of stricture | 3 | 8.57 |
| Optical instrumentation | 3 | 8.57 |

DISCUSSION

The present quasi-experimental study was conducted in the department of urology, Dhaka medical college hospital, Dhaka between January 2010 to December 2011. In this current study, the mean age of the participants was 37.4±8.2 years. The majority of the participants were from ≥30 years age groups. The age of the patients corresponds with the study of Barbagli et al.¹² In different international series of substitution urethroplasty of anterior urethral stricture, the patients were selected with a stricture length of >2 cm at bulbar part.^{13,14} In this study, the mean length of stricture (cm), peak urinary flow rate (Q_{max}), voided urine volume (ml) and PVR (ml) were found 3.6±0.8, 7.8±1.5, 210.5±61.8 and 57.4±6.2 respectively. Among all the participants, the length of strictures was observed ≤3 cm among 31% (n=11) and >3 cm among 69% (n=24) patients. In this study, as the immediate postoperative outcome among the participants, we found the mean peak urinary flow rate (Q_{max}), 15.3±1.2 and voided urine volume (ml), 328.8±50.1. On the other hand, as the postoperative outcome after 3 months among the participants, we found the mean peak urinary flow rate (Q_{max}), 21.2±1.2 and voided urine volume (ml), 331.8±25.1. Finally, as the postoperative outcome after 6 months among the participants, we found the mean peak urinary flow rate (Q_{max}), 24.2±2.9; voided urine volume (ml), 330.8±50.1 and PVR (ml), 11.6±3.3. In this study, some potential complications were bleeding and wound infection which were found among 11.43% and 17.14% patients respectively. In the series of Palmintiri et al using unilateral urethral mobilization, post operative peak urinary flow of successful patients was 31.02 ml/s versus the preoperative average peak urinary flow of 7.64 ml/s.¹⁵ Another study reported peak flow rate ranged between 18-29 ml/sec (mean 21) after successful operation of bulbar urethral stricture using circumferential urethral mobilization.¹⁶ Besides these, in this study, urethrocutaneous fistula, recurrence of stricture and optical instrumentation were found among 2.86%, 8.57% and another 8.57% patients respectively. One study reported 11% of recurrent stricture of dorsal onlay buccal mucosa graft urethroplasty of bulbar urethral stricture.¹⁷ In the present study, success rate of unilateral urethral mobilization was found 91.4%.

Limitations

This was a single centered study with a small sized sample and short-term follow up. Long-term follow up is needed to get an inference for a successful outcome.

CONCLUSION

The short-term outcome of unilateral urethral mobilization for the management of buccal mucosal graft urethroplasty of bulbar urethral stricture was satisfactory. Considering the satisfactory outcomes and lower complications unilateral urethral mobilization procedure can be considered as an effective treatment method for the management buccal mucosal graft urethroplasty of bulbar urethral stricture.

Recommendations

To get long-term expected outcome of this procedure, we would like to recommend for conducting more studies in several places by different urologists with larger sized samples and long-term follow up.

Funding: No funding sources

Conflict of interest: None declared

Ethical approval: The study was approved by the Institutional Ethics Committee

REFERENCES

1. Jordan GH, Schlossberg SM. Surgery of the penis and urethra. Campbell's-Walsh Urology, 9th eds, Saunders, Philadelphia. 2007.
2. McAninch, JW. Disorders of the penis and male urethra. Smith's general urology. 17th eds, McGraw-Hill Co, Philadelphia, New York. 2008.
3. Gupta NP, Ansari MS, Dogra PN, Tandon S. Dorsal buccal mucosal graft urethroplasty by a ventral sagittal urethrotomy and minimal access perineal approach for anterior urethral stricture. BJU Int. 2004;93:1287-90.
4. Mangera A, Patterson JM, Chapple CR. A Systematic Review of Graft Augmentation Urethroplasty Techniques for the Treatment of Anterior Urethral Strictures. Euro Asso Urol. 2011;59:797-814.
5. Barbagli G, Palminteri E, Guazzo G, Canti CA. Bulbar urethroplasty using the dorsal approach: Current techniques. Int Braz J Urol. 2003;29:155-61.
6. Barbagli G, Stefani SD, Sighinolfi MC, Annino F, Micali S, Bianchi G. Bulbar urethroplasty with dorsal onlay buccal mucosal graft and fibrin glue. Eur Urol. 2006;50:467-74.
7. Bhargava S, Chapple CR. Buccal mucosal urethroplasty: is it the new gold standard. BJU Int. 2004;93:1191-3.
8. Barbagli G, Stefani SD, Annino F, Carne CD, Bianchi G. Muscle- and nerve-sparing bulbar urethroplasty: a new technique. Eur Urol. 2008;54:335-43.
9. Bhargava S, Chapple CR, Bullock AJ, Layton C, Macneil S. Tissue-engineered buccal mucosa for substitution urethroplasty. BJU Int. 2004;93:807-11.
10. Chaudhary R, Jain N, Singh K, Singh HB, Chaudhary R, Biswas R. Dorsolateral onlay urethroplasty for pan anterior urethral stricture by a unilateral urethral mobilisation approach. BMJ case rep. 2011;10:1-7.
11. Kulkarni SB, Kulkarni JS, Kirpekar DV. A new technique of urethroplasty for balanitis xerotica obliterans. J Urol. 2003;163(1):352-57.
12. Barbagli G, Guazzoni G, Lazzeri M. One-stage bulbar urethroplasty: retrospective analysis of the results in 375 patients. Eur Urol. 2008;53:828-33.
13. Peterson CA, Webster GD. Management of urethral stricture disease: developing options for surgical intervention. BJU Int. 2004;94:971-76.
14. Dubey D, Kumar A, Mandhanim A, Srivastava A, Kapoor R, Bhandari M. 'Buccal mucosal urethroplasty: a versatile technique for all urethral segments. BJU Int. 2005;95:625-9.
15. Palminteri E, Manzoni G, Berdondini E. Combined dorsal plus ventral double buccal mucosa graft in bulbar urethral reconstruction. Eur Urol. 2008;53:81-90.
16. Barbagli G, Palminteri E, Lazzeri M, Guazzoni G. One-stage circumferential buccal mucosa graft urethroplasty for bulbous stricture repair. Urology. 2003;61:452-5.
17. Andrich DE, Mundy AR. Substitution urethroplasty with buccal mucosal-free grafts. J Urol. 2001;165:1131-4.

Cite this article as: Ghosh KC, Saha PK, Ahmed M, Mahmud F, Karmaker U. Evaluation of the short-term outcome of unilateral urethral mobilization for the management of bulbar urethral stricture. Int J Res Med Sci 2021;9:3506-9.