

## Research Article

# Glial heterotopia in head and neck, single center experience of 5 cases

**Ramyapriyadarshini Arikeri, Kumudachalam Pindicura\*, Vivekanand Namala, Ravikumar Penta, Ramakrishna Suggula, Sreedhar Reddy Dandala, Shankar Tati**

Department of Pathology, Government ENT Hospital, Hyderabad, India

**Received:** 27 May 2016

**Accepted:** 17 June 2016

**\*Correspondence:**

Dr. Kumudachalam Pindicura,

E-mail: [drpkumuda@rediffmail.com](mailto:drpkumuda@rediffmail.com)

**Copyright:** © the author(s), publisher and licensee Medip Academy. This is an open-access article distributed under the terms of the Creative Commons Attribution Non-Commercial License, which permits unrestricted non-commercial use, distribution, and reproduction in any medium, provided the original work is properly cited.

### ABSTRACT

**Background:** Heterotopic neuroglial tissue is defined as a mass composed of mature brain tissue isolated from the cranial cavity or spinal canal. The nose and the naso-pharynx are the most common sites of location. Heterotopic masses of neuroglial tissue involving non-midline structures, specifically the middle ear region, are exceptional. In this study, we present four cases of Nasal Glial Heterotopia and a single case of glial heterotopia of the middle ear from the institute. Aim and objective of the study was to study clinicopathological aspects of four cases of nasal glial heterotopia and a rare case of glial heterotopia involving the middle ear.

**Methods:** Neuroglial heterotopias in the head and neck region between 2008 and 2016 were evaluated. Clinical and radiological findings of these cases were analysed. Histopathological examination was the mainstay of diagnosis and Immuno-expression of glial fibrillary acid protein was done for confirmation in few cases.

**Results:** Five cases of glial heterotopias of head and neck were diagnosed during the study period. 4 cases of glial heterotopia of the nasal cavity and one case of glial heterotopia involving the right middle ear, was present in this study.

**Conclusions:** Glial Heterotopias of head and neck are more common in the nasal cavity. Middle ear Glial heterotopias are very rare. Clinical and radiological findings along with histopathology and immuno-histochemistry are essential in diagnosing these lesions.

**Keywords:** Glial heterotopia, Nasal cavity, Middle ear, Head and neck

### INTRODUCTION

Heterotopic neuroglial tissue is defined as a mass composed of mature brain tissue isolated from the cranial cavity or spinal canal. Initial description of glial heterotopias over the dorsal surface of the cervical spinal cord was in 1907.<sup>1</sup> The nose and the naso-pharynx are the most common sites of location.<sup>2</sup> Even if its occurrence is more frequent in midline structures, it can also be found in the non-midline structure rarely such as the middle ear.<sup>3</sup> Because of the rarity of these lesions, it is very important to differentiate them from the more frequent encephalocoeles by looking for any cerebral connection in order to avoid the post-operative risk of recurrent infections.<sup>3</sup> In this study, they have evaluated

clinicopathological aspects of four cases of nasal glial heterotopia and a single case of non-midline glial heterotopia of the middle ear.

### METHODS

The study was conducted in a tertiary care center for Head and Neck diseases and all the cases reported as neuroglial heterotopias in the head and neck region between 2008 and 2016 were evaluated. Clinical details submitted along with the case were considered. CT scan was done in all the cases. Histopathological examination was done for diagnosis and Immunohistochemistry with antibodies to glial fibrillary acid protein was done in few cases.

**RESULTS**

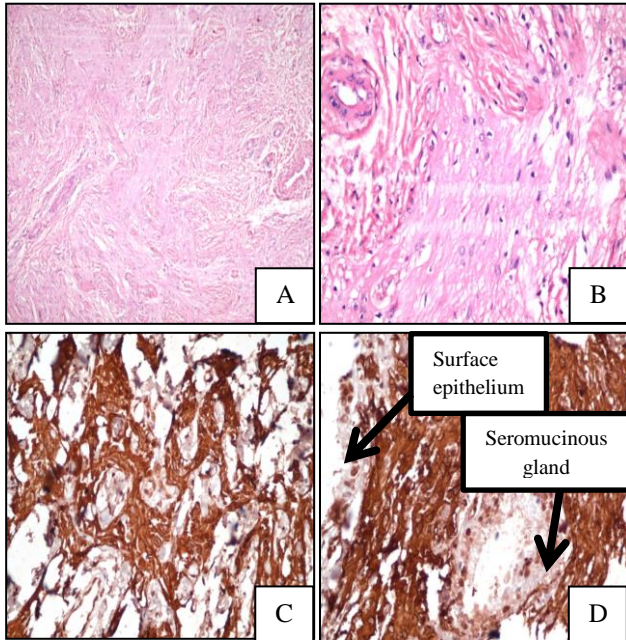
Five cases of glial heterotopias of head and neck were diagnosed during the study period. 4 lesions out of 5 cases involved the nasal cavity and one case involved the middle ear. The of glial heterotopia of the glial heterotopia of the nasal cavity lesions occurred with age range 11 months to 8 years with a male to female ratio of 1:1. The nasal glial heterotopia presented with obstructive

symptoms due to mass in the nasal cavity and external nose. There was no history of trauma and CSF leak in these cases. CT scan of nasal cavity and brain, revealed mass attached to the medial wall of the septum and roof. There was no skull defect on radiological examination. One out of 5 cases that occurred in Right middle ear had clinical diagnosis as CSOM. CT scan revealed erosion of tegmen with features suggestive of right mastoiditis and otitis media (Table 1).

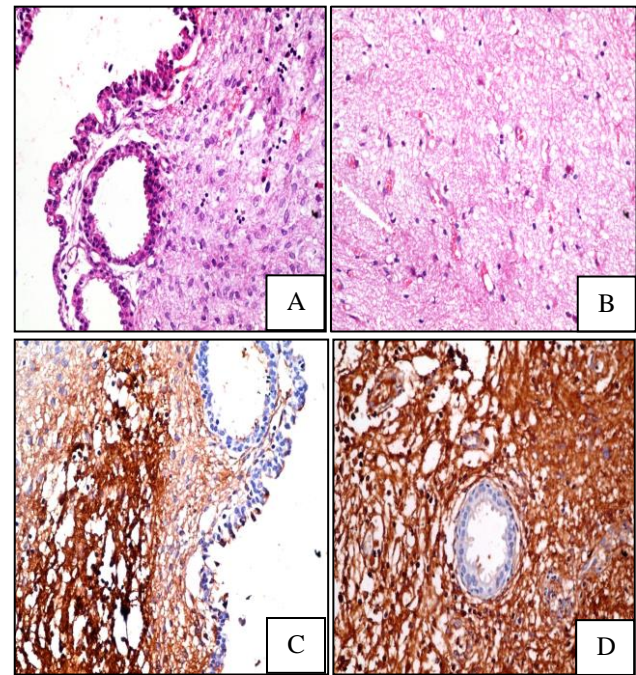
**Table1: Clinical and radiological findings.**

Age	Sex	Site	Connection to CNS
11 Months	Male	Right nasal cavity	No
11 Months	Male	Right nasal cavity	No
3 Years	Female	Right nasal cavity	No
8 Years	Female	Left nasal cavity	No
20 Years	Male	Right middle ear	No

On gross, nasal gliomas appeared as a smooth globular - polypoidal to irregular grayish masses. The largest lesion among the 4 nasal glioma cases measured 2x1cm. Cut Section was solid, homogenous, pearly white. Middle ear glial heterotopia was received as multiple soft tissue bits, largest measuring 0.5cm.



**Figure 1: Nasal Glial heterotopia A, B: H&E sections showing lesion composed of astrocytes and neuroglial fibers associated with a fibrous and vascularized connective tissue. C: IHC- confirmation of neuroglial origin by the presence of glial fibrillary acidic protein (GFAP) immunoreactivity in neuroglial tissue. D. Absence of GFAP immunoreactivity in surface epithelium and subepithelial gland.**



**Figure 2: Glial heterotopia-Middle ear. A: H&E showing intact ciliated columnar surface epithelium and submucosal cellular proliferation B: H&E showing loose fibrillary neuroglial tissue. C: IHC- presence of glial fibrillary acidic protein (GFAP) immunoreactivity. D: GFAP negative immunoreactivity in the seromucinous glands.**

On microscopy all the nasal glial heterotopia lesions revealed surface epithelium and subepithelial islands and sheets of neuroglial tissue composed of astrocytes in loose fibrillary matrix (Neuropil). Vascular channels and fibrous tissue was also present intervening the glial tissue. IHC-GFAP showed diffuse intense cytoplasmic

positivity, even in the areas of fibrous component in H&E stained section (Figure 1).

The case of glial heterotopia of middle ear on microscopy, showed ciliated columnar, surface epithelium with foci of squamous metaplasia. There was subepithelial loose fibrillary neuroglial tissue, collagenous fibro-connective tissue and adjacent seromucinous glands. Immunohistochemistry with GFAP was positive in the lesional area, confirming the diagnosis (Figure 2).

## DISCUSSION

Heterotopic neuroglial tissue is defined as a mass composed of mature brain tissue isolated from the cranial cavity or spinal canal. Most reported examples involve midline structures, including the nose and nasopharynx (so-called nasal glioma) as well as the oropharynx, palate, lips, tongue, and tonsils. Lesions involving non-midline structures, and specifically, the middle ear region, are often not recognized and may be misdiagnosed as neoplasms such as teratomas (when adjacent non-neural tissues are present), gliomas, meningiomas, or schwannomas.<sup>1</sup>

The pathogenesis of these lesions is uncertain. Various hypotheses have been postulated. These include: (a) A sequestered encephalocele; (b) Separation of primitive embryonic neural tissue from the main portion of the developing brain due to change in timing of fusion of chondrocranium; (c) Displacement of isolated pluripotential cells during early embryogenesis with potential for differentiation to mature neural tissue; and (d) Entrapment of abnormal glial cells from the olfactory bulbs.<sup>4</sup> One commonly accepted theory is that heterotopic neural tissue is a variant of encephalocele in which the central nervous system connection has been absorbed or become vestigial.<sup>1,5</sup>

These lesions may be classified based on their location and possible pathogenic mechanisms as follows: a) intra-paranchymal CNS lesions; b) dural and lepto-meningeal lesions; c) intracranial extra-cerebral lesions; d) distal lesions thought to result from a previous pregnancy; e) midline "nasal gliomas," thought to originate as encephaloceles; and f) non-midline lesions of the head and neck.<sup>1</sup>

Nasal Glial Heterotopias (NGH) are congenital tumours of the midline frontonasal space arising from a normal neuroectodermal tissue entrapped during the closure of the anterior neuropore.<sup>6</sup> Approximately 250 cases have been reported, but only a few adult cases are known. Regarding the location, 60% of the masses were located extranasally, 30% were intranasal, and 10% were both. In our study, all the nasal glial heterotopias cases occurred in the nasal cavity. In the intranasal type, most of the patients presented with symptoms of nasal obstruction and sinusitis. Other signs and symptoms included nasal

drainage, meningitis, and visual loss. There was some asymptomatic cases.<sup>7</sup>

Nasal glial heterotopia is frequently diagnosed in newborn infants, however, it may rarely be found in adults.<sup>8</sup> However, in this clinical series the most common age was 11 months, with no gender predilection. Although these can be found at all ages, they are generally diagnosed at birth or in early childhood. There is a rare case at an advanced age of the patient 81 years, who reported that obstructive symptoms had arisen only two years earlier, in literature.<sup>9</sup>

Histologically, nasal glial heterotopia is characterized by varying proportions of neurons and glia, and few showing gemistocytic astrocytes. There are varying degrees of fibrosis, frequently associated with inflammation. Large amounts of fibrotic tissue can undermine the glial tissue in H&E sections or glial tissue may mimic fibrotic tissue, as in one of our cases. However, immunohistochemistry with GFAP can be used to identify the Neuroglial tissue. Calcifications and ependymal-type cystic degeneration was also occasionally seen.<sup>8</sup>

Heterotopic brain tissue is very uncommon in the middle ear and mastoid. The most frequently reported choristoma of the middle ear is salivary gland tissue; heterotopic brain or glial tissues are very rare in this region.<sup>10</sup> Only 8 Neuroglial Heterotopia of the middle ear have been described in the literature till 2007.<sup>3</sup> Unlike their midline counterparts, most middle ear region neuroglial heterotopias are diagnosed in adult patients.<sup>1</sup> Similar to the literature, middle ear glial heterotopia was diagnosed in an adult patient.

Extra nasal sites of glial heterotopia, though rare are described in scalp, orbit, lip, tongue, palate, pharynx, submandibular region, middle ear, maxilla, neck and overlying spine as well as in the lungs, skin, uterine cervix and endometrium and other soft tissues.<sup>11</sup> In present case, patient presented with Right ear otitis media and mastoiditis. Cases presenting with mass lesion, tinnitus and hearing loss are also reported in the literature.<sup>10</sup>

In the middle ear and mastoid region, most previously reported cases describe an association with previous trauma, surgery, or infectious or inflammatory processes. Histologically, these lesions are composed of neurons and glial tissue, with some associated chronic inflammation and gliosis. Lesions involving the middle ear region, are often not recognized and may be misdiagnosed as neoplasms such as teratomas (when adjacent non-neural tissues are present), gliomas, meningiomas, or schwannomas.<sup>1</sup>

The differential diagnosis of Glial Heterotopia includes encephaloceles, hemangiomas, dermoid or epidermoid cysts, as well as malignant tumors such as rhabdomyosarcoma.<sup>12</sup> Radiographic assessment of

Nasopharyngeal glial heterotopia is best performed using CT complemented by MRI. Multiplanar images with multidetector CT scan delineate the location of the mass and its relationship to the skull base. Magnetic resonance characteristics of glial heterotopia resemble normal brain tissue in all pulse sequences. Cystic elements might be present and represent cerebrospinal fluid-like fluid-filled spaces.<sup>13</sup>

The treatment of choice is complete surgical excision. Surgery establishes the diagnosis by demonstrating an intact dura, prevent ascending infections and malignant transformation and achieve functional improvement.<sup>14</sup> Recurrences have been reported only in 4–10% of cases and they have been treated by re-excision.<sup>8,15</sup>

## CONCLUSION

Glial Heterotopias of head and neck are rare. Glial Heterotopias of the nasal cavity occur in infants and younger children thus have early clinical presentation. Middle Ear Glial Heterotopias are very rare, have late clinical presentation i.e adults. Histopathology and Immunohistochemistry with GFAP confirms the diagnosis.

## ACKNOWLEDGEMENTS

Authors would like to acknowledge technical staff, Mr. Rajender and Mrs. Krishnaveni for their help.

*Funding: No funding sources*

*Conflict of interest: None declared*

*Ethical approval: Not required*

## REFERENCES

- Gyure KA, Thompson LDR, Morrison AL. A Clinicopathological Study of 15 Patients with neuroglial heterotopias and encephaloceles of the Middle Ear and Mastoid Region. *Laryngoscope.* 2000;110:1731-5.
- Dadaci M, Bayram FC, Ince B, Bilgen F. Glial heterotopia of the lip: A rare presentation. *Indian J Plast Surg.* 2016;49:112-5.
- Farneti P, Balbi M, Foschini MP. Neuroglial choristoma of the middle ear. *ACTA otorhinolaryngologica italic.* 2007;27:94-7.
- Mahalik SK, Lyngdoh TS, Menon P, Sodhi KS, Vashishta RK, Kanojia RP, et al. Glial heterotopia of maxilla: A clinical surprise. *J Indian Assoc Pediatr Surg.* 2011;16:58-60.
- Kallman JE, Loevner LA, Yousem DM, Chalian AA, Lanza DC, Li Jin, et al. Heterotopic brain in the Pterygopalatine fossa. *Am J Neuroradiol.* 1997;18:176-9.
- Surda P, Hobson J. A Rare Case of Nasal Glial Heterotopia Presenting as Sphenchoanal Polyp. *International Journal of Otolaryngology and Head and Neck Surgery.* 2015;04(2). Article ID:54342,3 pages.
- Hagiwara A, Nagai N, Ogawa Y, Suzuki M. A Case of Nasal Glial Heterotopia in an Adult. *Case Reports in Otolaryngology.* Volume 2014, Article ID 354672, 4 pages.
- Penner CR, DDS, Thompson LRD. Nasal Glial Heterotopia: A Clinicopathologic and Immuno phenotypic Analysis of 10 Cases With a Review of the Literature. *Annals of Diagnostic Pathology.* 2003;7(6):354-9.
- Altissimi G, Ascani S, Falcetti S, Cazzato C, Acta Bravi I. Central nervous system tissue heterotopias of the nose:case report and review of literature.” *Acta Otorhinolaryngologica Italica.* 2009;29(4):218-21.
- Uz MZU, Lu SA, Terzi S, Etit D. Glial heterotopia of the middle ear. *The Journal of Laryngology and Otolaryngology.* 2006; E4:1 of 2.
- Mahalik SK, Lyngdoh TS, Menon P, Sodhi KS, Vashishta RK, Kanojia RP, et al. Glial heterotopia of maxilla: A clinical surprise. *J Indian Assoc Pediatr Surg.* 2011;16:58-60.
- Guez JJP, Bernabeu-Wittel J. Nasal Glial Heterotopia (Nasal Glioma) *J Pediatr.* 2010;156:688.
- Xian J, Austin J. Computed Tomographic and Magnetic Resonance Imaging Findings in the Midline Nasopharyngeal Glial Heterotopia. *Radiol.* 2015;2(2):1015.
- Plontke SKR, Preyer S, Pressler H, Mundinger PM, Plinkert PK. Glial lesion of the infratemporal fossa presenting as a soft tissue middle ear mass - rudimentary encephalocele or neural crest remnant?. *International journal of pediatric otorhinolaryngology.* 2000; 56:141-7.
- Ramadass T, Narayanan N, Rao P, Parameswaran A. Glial Heterotopia in ENT-Two Case Reports and Review of Literature. *Indian J Otolaryngol Head Neck Surg.* 2011;63(4):407-10.

**Cite this article as:** Arikeri R, Pindicura K, Namala V, Penta R, Suggula R, Dandala SR, et al. Glial heterotopia in head and neck, single center experience of 5 cases. *Int J Res Med Sci* 2016;4:3009-12.