

## Case Report

# Primary malignant melanoma of the nose: an unusual presentation

Yashita Gupta<sup>1\*</sup>, Mohd. Jafar Memon<sup>2</sup>, Renuka Gahine<sup>3</sup>

<sup>1</sup>Department of Pathology and Laboratory Medicine, Senior Resident, AIIMS, Raipur, Chhattisgarh, India

<sup>2</sup>Department of Pathology, Assistant Professor, Pt. J.N.M. Medical College, Raipur, Chhattisgarh, India

<sup>3</sup>Department of Pathology, Professor and Head, Government Medical College, Rajnandgaon, Chhattisgarh, India

**Received:** 26 May 2016

**Accepted:** 15 June 2016

### \*Correspondence:

Dr. Yashita Gupta,

E-mail: [yashigupta@gmail.com](mailto:yashigupta@gmail.com)

**Copyright:** © the author(s), publisher and licensee Medip Academy. This is an open-access article distributed under the terms of the Creative Commons Attribution Non-Commercial License, which permits unrestricted non-commercial use, distribution, and reproduction in any medium, provided the original work is properly cited.

### ABSTRACT

Mucosal malignant melanoma of the nasal cavity and paranasal sinuses is a rare entity. It is an unusual cause of nasal obstruction and epistaxis seen especially in elderly. We report the case of a primary nasal malignant melanoma in a 32 year old woman who presented with the history of epistaxis for 1 month. In our knowledge, this is the first case of primary nasal malignant melanoma to be reported in this age group.

**Keywords:** Mucosal malignant melanoma, Elderly, Age

### INTRODUCTION

Primary malignant melanoma of the sinonasal tract (SNT) constitutes approximately 1% of all melanomas. In the material reviewed by Friedmann and Osborn in the Institute of Laryngology and Otolaryngology in London, melanomas represented 5% of all SNT tumors and were the second most common malignancy (23%) in that region. The nasal cavity is more frequently affected than the paranasal sinuses.<sup>1</sup>

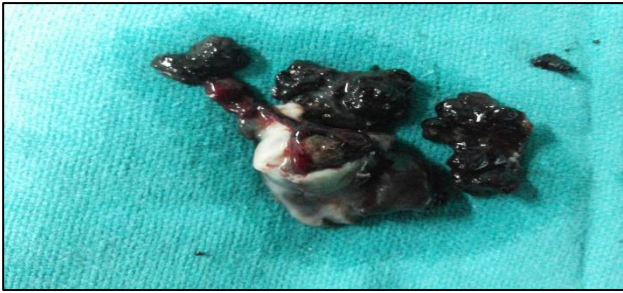There is no sex or race predilection, and 80% of the patients are older than 50 years of age with median age in the seventh decade. Symptoms at presentation are nonspecific and are related to the location of the tumor; they include nasal obstruction, epistaxis, facial pain, and sometimes melanorrhea or black mucus discharge. Symptoms may be present for a few weeks, several months, or even several years.<sup>1</sup> The overall prognosis for SNT melanoma is poor, with a 5-year survival ranging from 17% to 47%. Recurrences are common, with a poor prognosis associated with advanced stage, obstructive symptoms, tumor  $\geq 3$  cm, mixed anatomic sites of involvement, undifferentiated histology, high mitotic index, and vascular invasion. Matrix metalloproteinase

(MMP) expression is associated with patient outcome (MMP14 expression associated with poor prognosis). Wide local excision is the treatment of choice, with radiation providing only palliation.<sup>2</sup>

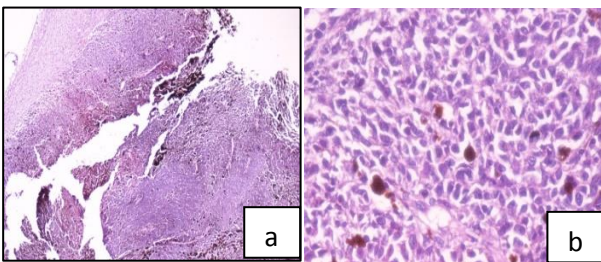
### CASE REPORT

A 32-year-old female patient attended the outpatient clinic of ENT department with complaint of swelling in the left nasal cavity causing obstruction and gradually increasing in size since 6 months. Few episodes of left side epistaxis have also occurred over the period of 1 month. On clinical examination, the irregular reddish pink mass with brownish discoloration at places was seen filling up the whole of left nasal cavity. There was no regional lymphadenopathy. There was no pigmented lesion elsewhere on skin surface.

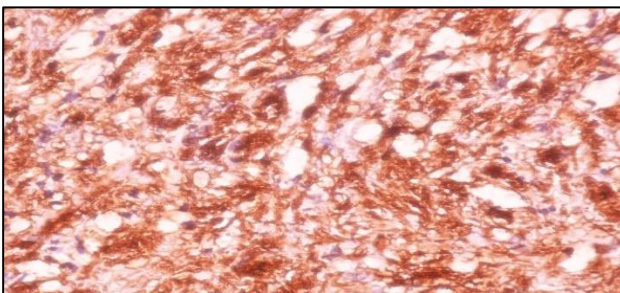
Chest X-ray and indirect laryngoscopy findings were normal. CT scan of the paranasal sinuses showed a soft tissue mass in left nasal cavity involving the ethmoid sinuses and maxillary antrum with bony remodeling. No evidence of direct orbital involvement, regional lymphnodes or any distant organ. No erosion of nasal septum and mass was limited to left side only.



**Figure 1: Gross photograph showing grey white to brownish black soft, friable polypoidal mass.**



**Figure 2a and b: Microphotograph (4x, 40x H and E) showing oval to spindle tumor cells arranged in solid fascicular and whorled pattern with brownish melanin pigment in between, mucosal infiltration is present.**



**Figure 3: Microphotograph showing tumor cells positive for HMB 45.**

Wide local excision of the mass was done. The specimen was sent for histopathology. Grossly, the mass was friable, soft in consistency with black pigmentation evident at most of the places (Figure 1). On histopathology, tumor cells were oval to spindle shaped growing in solid fascicles and whorled pattern along with brownish melanin pigmentation seen in between the cells. Mucosal infiltration was seen. (Figure 2a and 2b). On immunohistochemistry, tumor cells were positive for S-100 and HMB 45 (Figure 3). Thus, the definitive diagnosis of mucosal malignant melanoma was given. However, further investigations showed no regional or distant metastasis.

## DISCUSSION

All case reports published in the literatures so far are illustrate mucosal malignant melanoma more prevalent

among elderly population and one of the important cause of epistaxis which requires monitoring. However, our case reported in 32 year old female points towards early occurrence of this lesion.

These are tumors of uncertain etiology and they have no established risk factors or prophylactic measures.<sup>3</sup> Notwithstanding, rare entities such as the nasal mucosal melanoma are usually diagnosed already in advanced stages because they grow inside a cavity or because they were insistently treated based on examinations such as the facial X-Ray, considered to be too simple in the investigation of nasal obstruction and epistaxis.<sup>4</sup>

The natural course of malignant melanomas is marked by early local recurrences, extensions and frequent metastasis to lymph nodes and viscera, making it one of the most dangerous forms of nasal and paranasal sinus tumors.<sup>5</sup> Surgery is the initial mainstay of therapy, coupled with radiation and/or chemotherapy. Surgical resection of mucosal melanoma is usually unrewarding, by the nature of the location of the tumour.<sup>6</sup> Radiotherapy is the most common adjuvant therapy postoperatively, and early intervention was reported to lead to better local control and longer disease-free survival.<sup>7</sup>

## CONCLUSION

Aggressive behaviour and poor prognosis of mucosal malignant melanoma emphasise on early detection of these lesions which may permit possible adequate local control of the primary tumor. Previously all studies and case reports emphasize on more attention to be paid to patients, especially the elderly, with nonspecific symptoms of unilateral nasal obstruction, blood-tinged sputum, and epistaxis. However, our case of 32 year old female illustrates a diagnostic dilemma and call for clinical suspicion and extensive diagnostic work-up of all nasal masses and non-specific symptoms irrespective of age of the patient.

*Funding: No funding sources*

*Conflict of interest: None declared*

*Ethical approval: Not required*

## REFERENCES

1. Gnepp D. Diagnostic surgical pathology of the head and neck. Philadelphia, PA: Saunders/Elsevier; 2009.
2. Thompson L. Head and neck Pathology: Foundation in diagnostic pathology. Philadelphia, PA: Saunders/Elsevier; 2013.
3. Peralez MAR, Mendoza MAG, Marle JFS. Melanoma maligno de las mucosas. Anales de la Otorrino Mex. 1992;153-6.
4. Person OC, Nishimoto ES, Okada EF, Hamasaki SF et al. Primary Malignant Melanoma of Nasal Mucosa. International Archives of Otorhinolaryngology. 2005;9(1).

5. Batsakis JG. Pathology of tumors of the nasal cavity and paranasal sinuses and neck cancer. Philadelphia: WB Saunders Company; 1999.
6. Thompson LD, Wieneke JA, Miettinen M. Sinonasal tract and nasopharyngeal melanomas: a clinicopathologic study of 115 cases with a proposed staging system. *Am J Surg Pathol.* 2003;27:594-611.
7. Nakashima JP, Viegas CM, Fassizoli AL, Rodrigues M. Postoperative adjuvant radiation therapy in the

treatment of primary head and neck mucosal melanomas. *ORL J Otorhinolaryngol Relat Spec.* 2008;70:344-51.

**Cite this article as:** Gupta Y, Memon MJ, Gahine R. Primary malignant melanoma of the nose: an unusual presentation. *Int J Res Med Sci* 2016;4: 3061-3.