

## Case Report

# Suture less 3D mesh repair of sliding inguinal hernia: a case report

Abhijit Bagul, Qurratulain Chougale\*, Meena Kumar, Nandkishore,  
Naseem Khan, Sridevi Murali

Department of General Surgery, D Y Patil Medical College and Hospital, Navi Mumbai, Maharashtra, India

**Received:** 10 May 2016

**Revised:** 21 May 2016

**Accepted:** 03 June 2016

**\*Correspondence:**

Dr. Qurratulain Chougale,

E-mail: [qchougale@gmail.com](mailto:qchougale@gmail.com)

**Copyright:** © the author(s), publisher and licensee Medip Academy. This is an open-access article distributed under the terms of the Creative Commons Attribution Non-Commercial License, which permits unrestricted non-commercial use, distribution, and reproduction in any medium, provided the original work is properly cited.

### ABSTRACT

Sliding hernias involving the urinary bladder are rare, almost exclusively seen in men. As a result of slipping of the posterior parietal peritoneum on the underlying retroperitoneal structures, the posterior wall of the sac is not formed of the peritoneum alone, but by a portion of the bladder on either side. This case report presents the case of a 54 year old male patient with Right groin swelling since two years, gradually increasing in size with complaints of pain at the site of the swelling prior to voiding and also, an increase in the size of the swelling on retaining urine for a long duration. Based on clinical and radiological findings patient was diagnosed with Sliding inguinal hernia with bladder component, and underwent Open suture less 3D Mesh repair, with replacement of the bladder in the retroperitoneal space. The aim of this case report is to highlight the successful surgical management of a rare sliding hernia involving the urinary bladder using suture less 3D mesh repair.

**Keywords:** Sliding hernia, 3D Mesh, Inguinal, Suture less

### INTRODUCTION

Sliding inguinal hernias present with various symptoms and these are usually direct inguinal hernias containing various abdominal viscera. Case reports and series have been published earlier with various organs and rare organs being part of the hernia.

Urinary bladder is a known content of sliding hernias.<sup>1</sup> Large sliding inguinal hernias involving the urinary bladder are rare.<sup>2</sup> The urinary bladder is involved in 1-3% of inguinal hernias.<sup>3</sup> This case report highlights the successful surgical management of a rare sliding hernia with bladder content using suture less 3D Mesh repair.

The 3D mesh contains plug and patch components which has got a dynamic coil recoil action that adjusts to the dynamics of the canal, hence avoiding scar plate formation which can irritate the surrounding nerves and

give rise to chronic pain, unlike in conventional mesh repair.<sup>4</sup>

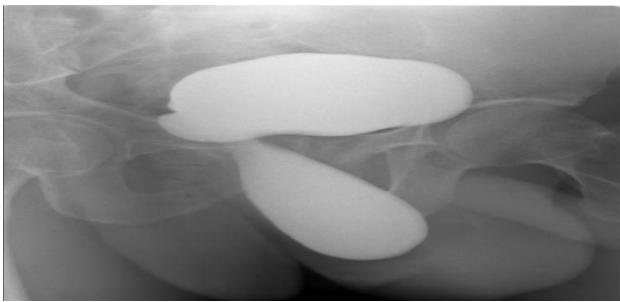
### CASE REPORT

A 54 year old male patient presented to the outpatients department with right groin swelling since two years, gradually increasing in size with complaints of pain at the site of the swelling prior to voiding and also, an increase in the size of the swelling on retaining urine for a long duration. He did not give any history of lifting heavy weights, fever, cough, vomiting, burning micturition or constipation. General physical examination and systemic examinations were within normal limits. Abdominal examination was normal with good bowel sounds.

On local examination, hernia was right sided, complete and direct inguinoscrotal, easily reducible, non-

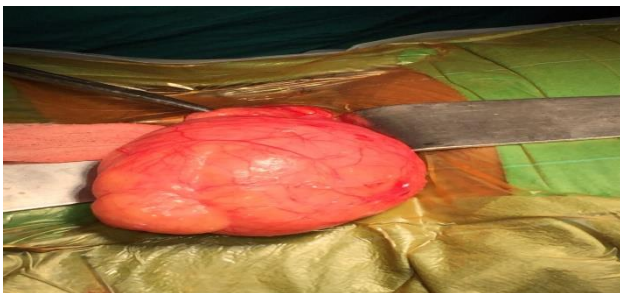tenderness. An ultrasonogram (USG) was requested in order to rule out benign prostatic hypertrophy considering the age of the patient. USG showed herniation of the right supero-lateral aspect of the dome of the bladder along with peritoneum into the right inguinal canal measuring 6.9x2.1x5.2= 41cc. On post void study there was no significant reduction of the volume of the herniated portion of the urinary bladder. Prostate appeared normal.

A retrograde cystogram was performed using water soluble contrast. It showed part of the urinary bladder in the pelvis and part in the hernia sac extending upto the base of the scrotum (Figure 1). Routine investigations including complete hemogram and urine analysis were normal. The patient was posted for an elective Right inguinal hernia 3D mesh repair under spinal anesthesia.



**Figure 1: Retrograde cystogram.**

A right groin transverse incision was taken. Content of the direct sac was identified as the urinary bladder (Figure 2). Bladder was reduced and 3D mesh placed after creating a plane in the pre peritoneal space. Postoperative period was uneventful.



**Figure 2: Intra-operative photograph as the hernia sac is delivered out intact.**

## DISCUSSION

Inguinal hernias may have unusual sac contents. Various abdominal organs such as the appendix, colon, small bowel, ovary, fallopian tubes and the urinary bladder have been described as contents of sliding inguinal hernias.<sup>5</sup>

The urinary bladder is involved in 1-3% of inguinal hernias.<sup>3</sup> Herniation of the bladder is often asymptomatic and only a small percentage of them are diagnosed pre-

operatively.<sup>6,7</sup> Most of them are associated with direct hernias.<sup>7</sup> However, a patient with incarcerated bladder diverticula in an indirect sac has been documented.<sup>7</sup> Urinary bladder hernia requires special attention because of high risk of iatrogenic bladder injury during inguinal dissection. Male sex, obstructive urinary symptoms, older age group and obesity are some of the risk factors.<sup>5</sup> Patients with complaints of voiding dysfunction should undergo diagnostic work up such as ultrasonogram, cystoscopy, endovenous urography, retrograde and voiding cystourethrography, urodynamic studies and computed tomography.<sup>8</sup>

Inguinal hernia repair is one of the commonest operations in surgical practice. However, when a surgeon encounters unusual contents it could pose a difficulty in its management.<sup>5</sup> Inguinal hernia repair remains controversial, despite advances in technique and materials.

Conventional implants are typically static and do not move in concert with groin's motility. Inguinal hernia repair with mesh fixation on dynamic groin structure are not tension free, and associated with tissue tearing, bleeding, hematoma, and nerve entrapment- all which might contribute to mesh dislocation.<sup>4</sup> Another important issue in prosthetic hernia repair is related to poor quality of tissue ingrowth within conventional flat meshes and plugs.<sup>9</sup> The ingrowth of this kind of stiff fibrotic scar (scar plate) leads to mesh shrinkage and to the reduction of the mesh surface area. This is considered a significant cause of recurrence and discomfort.<sup>9</sup>

The 3D mesh contains plug and patch components which has got a dynamic coil recoil action that adjusts to the dynamics of the canal, hence avoiding scar plate formation.<sup>4</sup> This case report highlights the repair of a rare sliding inguinal hernia with urinary bladder as content using the 3D mesh suture less repair which has not been reported in literature before. The patient was followed up post operatively for 6 months and found to have no complaints. The use of the 3D mesh construction prepare the way for a short hospital stay, smooth recovery and a swift return to normal activity.<sup>10</sup>

*Funding: No funding sources*

*Conflict of interest: None declared*

*Ethical approval: Not required*

## REFERENCES

1. Mahadevappa B, Suresh SC, Natarajan K, Thomas J. Cystogram with dumbbell shaped urinary bladder in a sliding inguinal hernia. J Radiol Case Rep. 2009;3(2):7-9.
2. Bjurlin MA, Delaurentis DA, Jordan MD, Richter HM 3<sup>rd</sup>. Clinical and radiographic findings of a sliding inguinoscrotal hernia containing the urinary bladder. Hernia. 2010;14(6):635-8.

3. Farber SB, Hertzenu Y. Massive bladder hernia: Ultrasonographic imaging in two cases. *British Journal of Urology.* 1998;81:482-3.
4. Amato G, Agrusa A, Romano G. Fixation free inguinal hernia repair using a dynamic self-retaining implant. *Surg Technol Int.* 2012;22:107-12.
5. Gurer A, Ozdogan M, Ozlem N, Yildirim A, Kulacoglu H, Aydin R. Uncommon content in groin hernia sac. *Hernia.* 2006;10(2):152-5.
6. Oruc MT, Akbulut Z, Ozozan O, Coskun F. Urological findings in Inguinal hernia: A Case Report and Review of the Literature. *Hernia.* 2004;8(1):76-9.
7. Gomella LG, Spires SM, Burton JM, Ram MD, Flanigan RC. The Surgical Implications of Herniation of the Urinary Bladder. *Archives of Surgery.* 1985;120(8):964-8.
8. Juan Escudaro JU, Ramos de Campos M, Ordone Dominguez F, Febauel Deltoro M, Serrano de la Cruz, Torrijos F, et al. Inguinoscrotal bladder hernias. *Arch Esp Urol.* 2007;60(3):231-6.
9. Amato G, Romano G, Agrusa A, Cocorullo G, Gulotta G, Goetze T. Dynamic inguinal hernia repair with a 3d fixation free and motion compliant implant: a clinical study. *Surg Technol Int.* 2014;24:155-65.
10. Dabić D, Cerović S, Azanjač B, Marić B, Kostić I. Prolene hernia system, ultraro hernia system and 3D patch devices in the treatment of inguinal, femoral, umbilical and small incisional hernias in outpatient surgery. *Acta Chir Iugosl.* 2010;57(2):49-54.

**Cite this article as:** Bagul A, Chougale Q, Kumar M, Nandkishore, Khan N, Murali S. Suture less 3D mesh repair of sliding inguinal hernia: a case report. *Int J Res Med Sci* 2016;4:3068-70.