

## Case Series

# Topical clobetasol propionate 0.025%: a therapeutic dermatologic asset

Deepak Singhal<sup>1</sup>, Revathi Deivasigamani<sup>2</sup>, Bhavik A. Bhavsar<sup>3</sup>, Lakshmi Sitara Ganiseti<sup>4</sup>,  
Purshotam R. Menghani<sup>5</sup>, Imran Majid<sup>6</sup>, Naveen Kumar Kukkadapu<sup>7\*</sup>, Gillella Srinivasulu<sup>8</sup>,  
Sneha Amol<sup>9</sup>, Rani Sudhir Shah<sup>10</sup>, Mashkooor Ahmed Wani<sup>11</sup>

<sup>1</sup>Department of Dermatology, Sai Skin Clinic, New Delhi, India

<sup>2</sup>Department of Dermatology, Revathi Hospital, Salem, Tamil Nadu, India

<sup>3</sup>Department of Dermatology, Lavanya Clinic, Ahmedabad, Gujarat, India

<sup>4</sup>Department of Dermatology, Sitara Advanced Skin and Hair Clinic, Hyderabad, India

<sup>5</sup>Department of Dermatology, Dr Menghani's Skin Clinic and LASER Center, Rajasthan, India

<sup>6</sup>Department of Dermatology, Body Shop, Srinagar, Jammu and Kashmir, India

<sup>7</sup>Department of Dermatology, Govt Hospital, Karimnagar, Andhra Pradesh, India

<sup>8</sup>Department of Dermatology, Skin and Cosmetology Centre, Vijayawada, Andhra Pradesh, India

<sup>9</sup>Department of Dermatology, Dr Zope Skin and Health Clinic, Ratnagiri, Maharashtra, India

<sup>10</sup>Department of Dermatology, Dr Rani S Skin Care Clinic, Surat, Gujarat, India

<sup>11</sup>Department of Dermatology, Shah Multi Speciality Clinic, Jammu, Jammu and Kashmir, India

**Received:** 14 July 2022

**Accepted:** 29 July 2022

### \*Correspondence:

Dr. Naveen Kumar Kukkadapu,

E-mail: naveen56@gmail.com

**Copyright:** © the author(s), publisher and licensee Medip Academy. This is an open-access article distributed under the terms of the Creative Commons Attribution Non-Commercial License, which permits unrestricted non-commercial use, distribution, and reproduction in any medium, provided the original work is properly cited.

## ABSTRACT

Over several decades, topical corticosteroids (TCs) have been used in the treatment of various dermatoses such as psoriasis, contact dermatitis, and eczema, among others. The TCs act by reducing inflammation and irritation after topical application. The therapeutic effect of TCs is bestowed through their diverse biologic properties such as anti-inflammatory, antiproliferative, vasoconstrictive, and antimetabolic activity, and its role in the reduction of lymphocyte reactivity, modulation of Langerhans cell expression, cellular and lysosomal membrane stabilization, reduction of recruitment of neutrophils and monocytes, reduction of mast cell density and reactivity, and sensitization of immunoglobulin E. Clobetasol propionate (CP) 0.025% is a class I TC available as a cream formulation. The cream formulation contains half the concentration of conventional CP (0.025%), without the loss of therapeutic potency. The lack of additives such as penetration enhancers (propylene glycol) further prevents cutaneous microbiome alteration. This comprehensive case series covers the potent efficacy and safety of Impoyz™ (CP) Cream 0.025% in the management of various dermatological disorders.

**Keywords:** CP 0.025%, Plaque psoriasis, TCs, Psoriasis

## INTRODUCTION

Topical corticosteroids (TCs) have played a vital role in the management of several dermatological disorders over several decades.<sup>1</sup> Low-potency corticosteroids are recommended for the treatment of dermatoses in infants and children, especially on the face, groin, and axillary areas. However, in adults, mid- and high-potency

corticosteroids are recommended for use in all other areas. Super-potent corticosteroids are reserved for cutaneous or stubborn plaques or lesions on the soles, palms, and scalp.<sup>2</sup> CP 0.05% emollient cream is known for its super-high potency; however, it is associated with increased systemic absorption, thus imposing a high risk of side-effects like suppression of the hypothalamic-pituitary-adrenal (HPA) axis, even at a low dose of 2

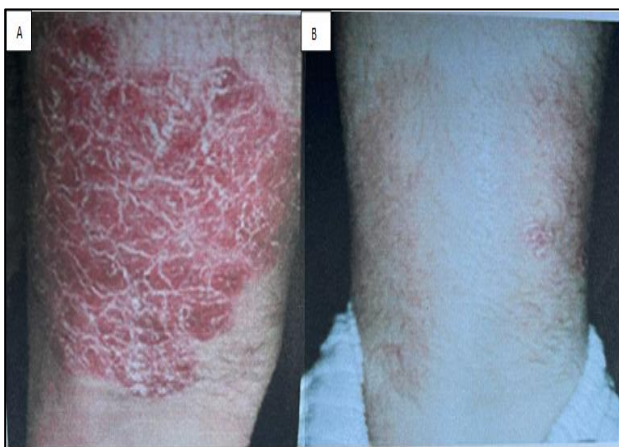
gm/day. This systemic side-effect limits the use of the therapeutic to small, confined areas for a maximum of 2 weeks. Thus, the development of improved formulations containing half the concentration of conventional CP (0.025%) without compromising on the therapeutic potential and safety will cater to the unmet needs.<sup>3</sup> The success or failure of a TC is largely impacted by vehicle formulation and patient preference, along with its potency and anticipated efficacy. CP 0.025% is class I TC developed as a cream formulation without propylene glycol, ethanol, and a sorbitol-based emulsifier like sorbitan sesquioleate, which is a contact allergen and a common component in several TC formulations, including the CP 0.05% ointment.<sup>1</sup>

The present case series discusses the clinical experience, expert opinion, efficacy, and safety of CP 0.025% for treating multiple dermatoses.

## CASE SERIES

### *Case 1: Treatment of itchy lesions in legs with Impoyz™ (clobetasol propionate) cream 0.025%: a case study*

A 43-year-old male presented with mildly itchy and scaly lesions on the legs and on and off bilateral arthritis for the past 3 years. He had hypertension and a family history of psoriasis. There was no associated occupational risk. The vitals and systemic findings of the patient were normal, and he had no psychological and social sequelae. The lesions were approximately 5×5 cm in size with some inflammation. The center of the lesion was non-atrophic, and the skin had a papular rash (Figure 1 A). The patient was diagnosed with plaque psoriasis and was prescribed Impoyz™ (CP) cream 0.025% to be applied twice daily. The patient also advised to improve overall self-care for better management of indication.



**Figure 1 (A and B): Pretreatment image of the lesions and post-treatment image of the lesions.**

At a follow-up visit after 14 days, a reduction was observed in scaling, plaque elevation, and flares or relapses. Erythema and itching were absent (Figure 1 B).

Overall, the severity of the disease had significantly reduced after treatment with Impoyz™ (CP) cream 0.025%.

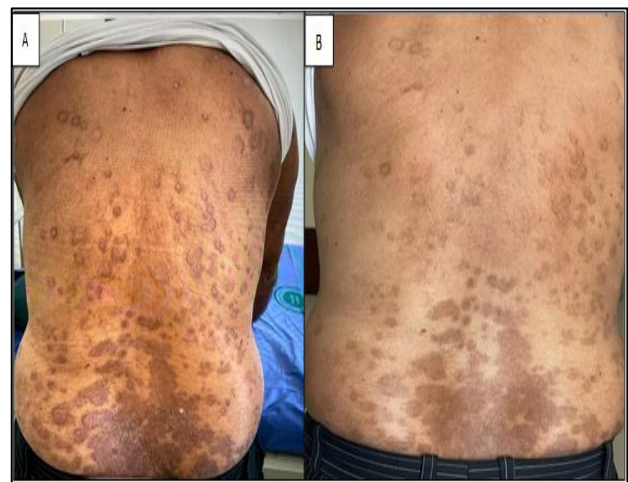
### *Expert opinion*

Impoyz™ (CP) cream 0.025% demonstrates excellent results with superior efficacy and safety profile. The cream provided high patient satisfaction and helped to build confidence in patients. It can be used as a first-line topical therapy.

### *Case 2: Efficacy of Impoyz™ (CP) cream 0.025% in plaque psoriasis*

A 45-year-old male presented with dry and scaly brown patches on the back and both the hands. He had hypertension and obesity; however, no significant family history was reported. The patient had psychological and social sequelae, but his vitals and systemic findings were unremarkable. The lesions were 4x6 cm in size, surrounded by inflammation. The skin had a vesicular and urticarial rash and was itchy and scaly. More than 30% of the body surface area was covered with lesions (Figure 2 A). The patient was diagnosed with plaque psoriasis and was prescribed a topical application of Impoyz™ (CP) cream 0.025% for 15 days. Patient also advised to bathe twice daily to improve personal hygiene.

At a follow-up visit after 15 days, a 70% and 90% reduction were observed in scaling and plaque elevation, respectively. Erythema and itching had completely resolved (Figure 2 B). Flares and relapses had also decreased. Overall, severity of diseased patches reduced after treatment with Impoyz™ (CP) cream 0.025%.



**Figure 2 (A and B): Pre-treatment image of the lesions and post-treatment image of the lesions.**

### *Expert opinion*

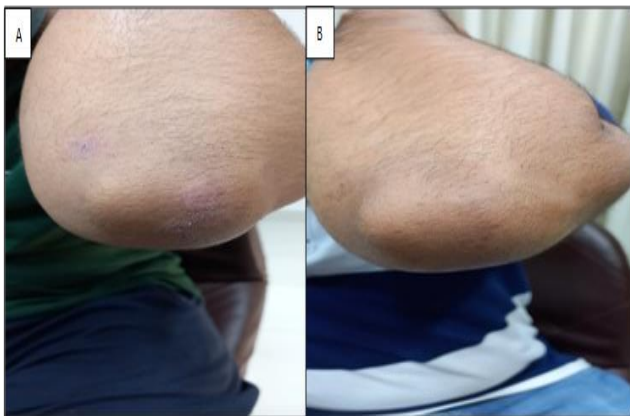
Impoyz™ (clobetasol propionate) cream 0.025% exhibits good effect and is safe with no adverse events of TCs. It

reduces the severity of patches and can be an effective therapy for plaque psoriasis, urticaria, and eczema.

**Case 3: Management of eczema with Impoyz™ (clobetasol propionate) cream 0.025%**

A 32-year-old male presented with eczematous itchy lesions on elbows and lower legs. He had no other comorbidity, occupational risk, or significant family history. No abnormality was detected in his vitals and systemic findings, and psychological or social sequelae were absent. The lesions were 3×3 cm in size with no surrounding inflammation. The center of the lesion was eczematous, and the skin was itchy and scaly (Figure 3 A). The patient was diagnosed with eczema and was prescribed a topical application of Impoyz™ (clobetasol propionate) cream 0.025% along with 5 mg levocetirizine for 14 days.

At a follow-up visit on day 14, erythema, scaling, itching, and plaque elevation had improved (Figure 3 B). Overall, the severity of the disease had decreased following treatment.



**Figure 3 (A and B): Pretreatment image of the lesions and post-treatment image of the lesions.**

**Expert opinion**

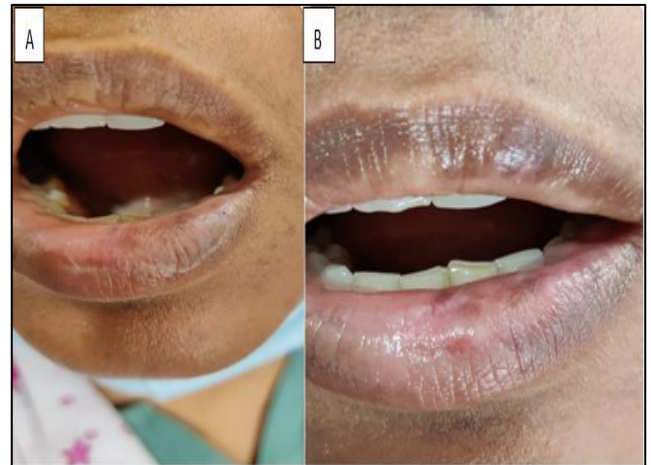Impoyz™ (CP) Cream 0.025% is safe and can be used to manage mild-to-moderate eczema. It can also be used as a tapering medication for the treatment of lichenoid lesions along with other steroids.

**Case 4: Treatment of mucocutaneous lesions with Impoyz™ (clobetasol propionate) cream 0.025%**

A 28-year-old female presented with a burning sensation on her lips with a white patch. She did not have any other comorbidity, occupational risk, or significant family history. Her vitals and systemic findings were normal, and she did not have psychological or social sequelae. Hypopigmented lesions were observed in the left corner of the lower lip, which were 2×3 cm in size. Inflammation was present around the lesions, but the

center of the lesion was normal. The skin had a macular rash and was itchy and scaly (Figure 4 A). The patient was diagnosed with lichen planus of the lips and was prescribed a topical application of Impoyz™ (clobetasol propionate) cream 0.025% along with a lip balm for 2 weeks. She was also advised to use a betadine gargle for better management of the indication.

At a follow-up after 14 days, scaling had decreased (Figure 4 B). Overall, a reduction was observed in the severity of the disease.



**Figure 4 (A and B): Pretreatment image of the lesions and post-treatment image of the lesions.**

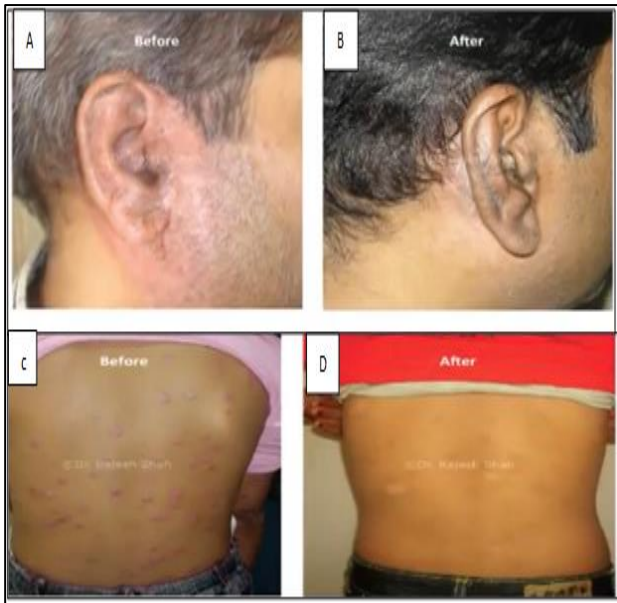**Expert opinion**

Impoyz™ (clobetasol propionate) cream 0.025% is good and safe for use in mucocutaneous lesions. It can be used as the first line of treatment for lichen planus of the lips, owing to fewer cutaneous side effects and efficacy in the reduction of lesions.

**Case 5: Safety and efficacy of topical Impoyz™ (clobetasol propionate) cream 0.025% for the treatment of papules on the ear and back**

A 20-year-old boy presented with itching and papules on the ear and back. The patient did not have any other comorbidity, occupational risk, or family history. Psychological and social sequelae were absent, and his vitals were normal. The size of the lesions on the back and ear was 1×1 cm and 4"×2", respectively. The skin was itchy and scaly with a papular rash (Figures 5 A and C). The patient was diagnosed with psoriasis and was prescribed Impoyz™ (clobetasol propionate) Cream 0.025%.

At a follow-up visit after 14 days, scaling, itching, plaque elevation, and erythema had reduced. (Figures 5 B and D). A marked reduction was also observed in the overall severity of the disease on treatment with Impoyz™ (clobetasol propionate) cream 0.025%.



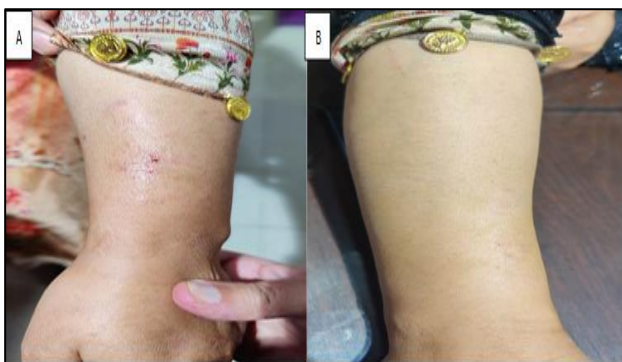
**Figure 5 (A-D): Pre-treatment image of the lesions and post-treatment image of the lesions.**

**Expert opinion**

Impoyz™ (clobetasol propionate) cream 0.025% has good efficacy with no local or systemic side effects. It can be used as a first-line topical treatment.

**Case 6: Psoriasis management using Impoyz™ (clobetasol propionate) cream 0.025%**

A 20-year-old girl presented with itchy red plaques. She did not have any other comorbidity, occupational risk, or significant family history. Her vitals and systemic findings were normal, and she did not have psychological or social sequelae. Lesions were present in the forearm and were 3×2 cm in size. Inflammation was present surrounding the lesion. The skin had a papular rash and was itchy (Figure 6 A). Less than 1% of the body surface area was covered with the lesion. The patient was diagnosed with psoriasis and was prescribed Impoyz™ (clobetasol propionate) cream 0.025%.



**Figure 6 (A and B): Pretreatment image of the lesions and post-treatment image of the lesions.**

At a follow-up visit after 14 days, a remarkable improvement was observed in itching, erythema, and plaque elevation (Figure 6 B). The overall severity significantly improved during treatment with Impoyz™ (clobetasol propionate) cream 0.025% (Figure 6 B).

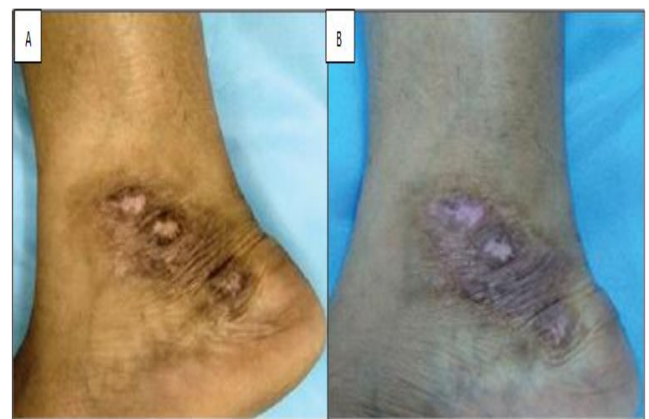
**Expert opinion**

Impoyz™ (clobetasol propionate) cream 0.025% exhibits potent efficacy and has a good safety profile with no adverse events.

**Case 7: Treatment of itchy plaques with Impoyz™ (clobetasol propionate) cream 0.025%: a case report**

A 51-year-old female presented with itchy plaque around the ankle. She did not have any other comorbidity, relevant family history, or occupational risk. Psychological and social sequelae were absent, and her vitals were unremarkable. The lesions were 3×2 cm in size surrounded by inflammation and plaque at the center. The skin was warm, itchy, and scaly with a papular rash (Figure 7 A). The patient was diagnosed with psoriasis and was prescribed Impoyz™ (clobetasol propionate) cream 0.025% to be applied twice daily for 15 days.

At a follow-up visit after 15 days, erythema and itching had completely disappeared, and scaling, plaque elevation, and flares or relapses had reduced (Figure 7 B). Overall, a reduction was observed in the severity of the disease.



**Figure 7 (A and B): Pretreatment image of the lesions and post-treatment image of the lesions.**

**Expert opinion**

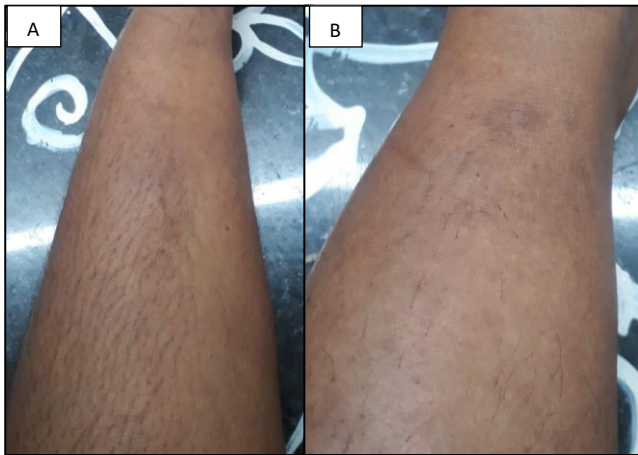
Impoyz™ (clobetasol propionate) cream 0.025% is safe and effective. It can be used to treat chronic skin diseases.

**Case 8: Scaly and pigmented plaque management with Impoyz™ (clobetasol propionate) cream 0.025%**

A 42-year-old male presented with scaly thickened plaques bilaterally over the anterior portion of both the

legs. The patient did not have any other comorbidity, occupational risk, or family history. The vitals and systemic findings of the patient were normal, and he had no psychological and social sequelae. The lesions were approximately 2×2 cm in size. There was no inflammation surrounding the lesions, and the center of the lesion was thick and mildly pigmented. The skin was itchy and scaly with a rash (Figure 8 A). Less than 5% of the body surface area was covered with the lesion. The patient was diagnosed with psoriasis and was prescribed Impoysz™ (clobetasol propionate) cream 0.025% to be applied at bedtime only on the lesion. The patient was also advised to avoid scratching for better management of the indication.

At a follow-up visit after 14 days, scaling, plaque elevation, and itching had decreased (Figure 8 B). Overall, a 90% improvement was observed in the severity of the disease after treatment with Impoysz™ (clobetasol propionate) cream 0.025%.



**Figure 8 (A and B): Pretreatment image of the lesions and post-treatment image of the lesions.**

#### Expert opinion

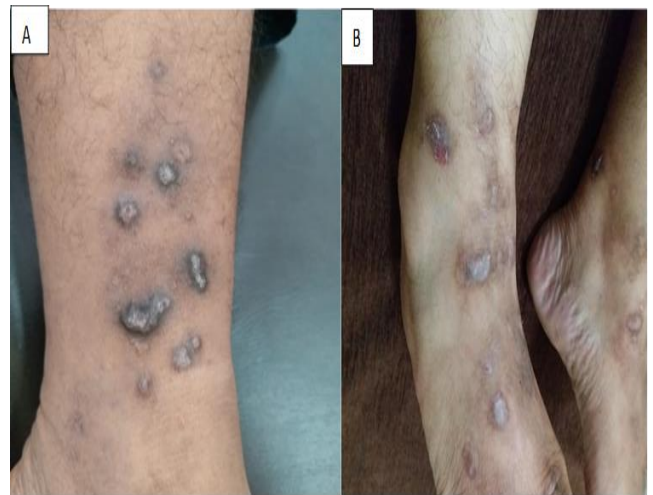Impoysz™ (clobetasol propionate) cream 0.025% is good and can be used for the long-term owing to its minimal side effects. It can be prescribed for the treatment of psoriasis and eczema.

#### **Case 9: Treatment of itchy and hyperpigmented plaques management with Impoysz™ (clobetasol propionate) cream 0.025%: a case report**

A 55-year-old male presented with itchy, hyperpigmented plaques bilaterally over both the ankles for the past 10 years. The patient had hypertension and dyslipidemia and his elder brother had a similar skin condition. His vitals and systemic findings were normal, and he had no psychological and social sequelae. The lesions were approximately 2×2.5 cm in size. There was no inflammation surrounding the lesions, and the center of the lesion was thick and mildly pigmented. The skin was

itchy and scaly (Figure 9 A). The patient was diagnosed with hypertrophic lichen planus and was prescribed Impoysz™ (clobetasol propionate) cream 0.025% to be applied twice a day along with an intralesional corticosteroid such as triamcinolone acetonide (40 mg/mL) administered every 3 weeks.

At a follow-up visit after 14 days, the itching had completely disappeared, scaling was reduced, and plaque elevation had flattened (Figure 9 B). Overall, a 90% improvement was observed in the severity of the disease after treatment with Impoysz™ (clobetasol propionate) cream 0.025%.



**Figure 9 (A and B): Pre-treatment image of the lesions and post-treatment image of the lesions.**

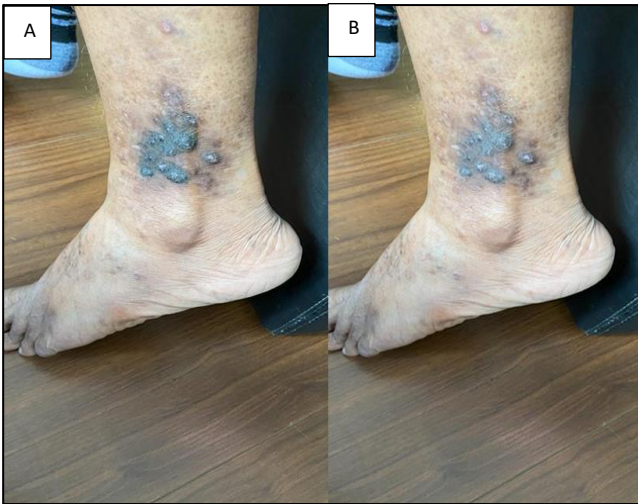#### Expert opinion

Impoysz™ (clobetasol propionate) cream 0.025% exhibits good results with moderate potency and can be safely used for the management of peripheral hypopigmentation.

#### **Case 10: Management of itchy, lichenified patches with Impoysz™ (clobetasol propionate) cream 0.025%**

A 30-year-old male presented with lichenified patches with itching over the ankle. He did not have any other comorbidity or occupational risk or family history. His vitals and systemic findings were within normal limits, and he had no psychological and social sequelae. The lesions were approximately 10-15 cm in size. There was no inflammation surrounding the lesions, and the skin was itchy (Figure 10 A). The patient was diagnosed with plaque psoriasis and was prescribed Impoysz™ (clobetasol propionate) Cream 0.025% to be applied for a month along with a moisturizer (to be applied in the morning).

At a follow-up visit after a month, itching and plaque elevation had reduced (Figure 10 B).



**Figure 10 (A and B): Pretreatment image of the lesions and post-treatment image of the lesions.**

**Expert opinion**

Impoyz™ (clobetasol propionate) cream 0.025% shows fast healing results with better compliance. It does not cause discoloration of the skin around the lesions.

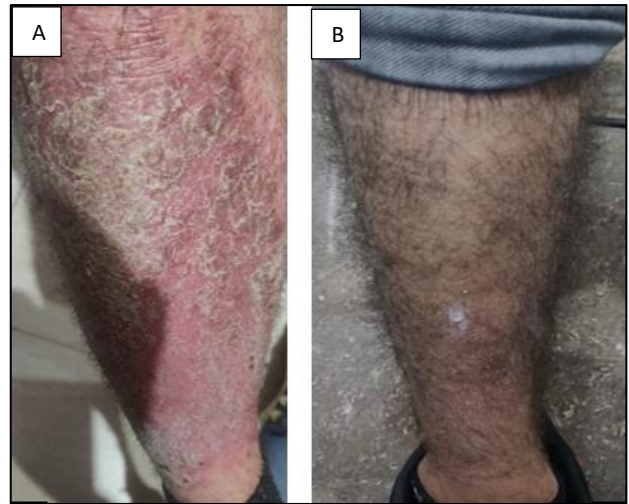**Case 11: Management of psoriasis with Impoyz™ (clobetasol propionate) cream 0.025% topical therapy: a case study report**

A 36-year-old male presented with a chief complaint of psoriasis. He had hypertension as a family history of psoriasis and diabetes. The patient neither presented any occupational risk factors nor had any psychological or social sequelae. His vitals were stable and systemic findings were within normal limits. The lesions were large and approximately 12×10 cm in size. They were presented on the lower legs. There was inflammation around the lesions, and the center of the lesions was also inflamed. The skin had a rash and was warm, itchy, and scaly. (Figure 11 A). The patient was diagnosed with plaque psoriasis. He was prescribed Impoyz™ (CP) cream 0.025% which was to be applied for 2 weeks followed by a moisturizer. However, no antifungal was prescribed to the patient. He was given general instructions to maintain the hygiene.

At the follow-up visit on the 14<sup>th</sup> day, scaling and plaque elevation had reduced significantly. Erythema and itching had also reduced (Figure 11 B). Overall, a reduction in the severity of the disease was observed with the use of topical therapy.

**Expert opinion**

The application of Impoyz™ (CP) cream 0.025% cream is very safe and has better efficacy and tolerance. It can be used as long-term, first-line topical therapy. More clinical experience on the usage of this agent is required.



**Figure 11 (A and B): Pretreatment image of the lesions and post-treatment image of the lesions.**

**DISCUSSION**

In India, approximately 0.44%-2.8% of adults are affected by psoriasis, a chronic autoimmune skin disorder. The global prevalence of psoriasis ranges from 0.09-11.43%, resulting in a high global burden that significantly hampers the quality of life.<sup>3</sup> Since the introduction of TCs, they serve a central position in the management of various skin disorders such as psoriasis, contact dermatitis, seborrheic dermatitis, atopic dermatitis, and other inflammatory dermatological conditions.<sup>1</sup>

Class 1 TCs are prescribed by dermatologists for the treatment of plaque psoriasis in approximately 60% of the patients. This is largely due to the superiority of class 1 TCs over other less potent therapeutics with respect to achieving marked improvement or initial clearance. Class 1 TC can be used as combination therapy or intermittent therapy for the long-term treatment of dermatological conditions such as psoriasis, irrespective of the severity of the disease.<sup>1</sup>

**Table 1: Patients reporting treatment-emergent adverse events.<sup>4</sup>**

Variables	CP 0.025% group, (n=24) (%)	CP 0.05% group, (n=22) (%)
<b>Patients who experienced TEAEs</b>	6 (25)	11 (50)
<b>Patients with TEAEs possibly, probably, or associated with the study drug</b>	5 (20.8)	10 (45.5)

TEAEs: Treatment-emergent adverse events.

Results from the phase II trial that compared the efficacy and safety of CP 0.025% versus CP 0.05% in patients with moderate-to-severe psoriasis showed that CP

0.025% demonstrated comparable efficacy as the super potent CP 0.05%. The primary efficacy assessment was investigator's global assessment scale (IGA) score. On day 15, a similar marked improvement was observed in the severity of the disease in both the treatment groups with an IGA score of 2 (mild) in half of the patients in each group. Approximately 16.7% and 18.7% of patients in the CP 0.025% and CP 0.05% group, respectively, had a score of 0 or 1 (null or minimal). CP 0.025% also exhibited potent safety in the trial over CP 0.05% as evidenced by a reduced HPA axis suppression and systemic exposure. The number of treatment-emergent adverse events (TEAEs) was also higher in the CP 0.05% group compared with the CP 0.025% group. The results of patients with reported TEAE are tabulated below (Table 1).<sup>4</sup>

## CONCLUSION

TCs are vital in managing steroid-responsive dermatoses. As evidenced by data from various trials and clinical practice, Impoyz™ (clobetasol propionate) cream 0.025% has comparable efficacy and a superior safety profile compared with the CP 0.05% cream, especially in patients with moderate-to-severe psoriasis. Owing to a favorable benefit-risk profile of CP 0.025%, it is recommended as first-line therapy by dermatologists for various skin disorders.

*Funding: No funding sources*

*Conflict of interest: None declared*

*Ethical approval: Not required*

## REFERENCES

1. Del Rosso JQ. Topical corticosteroid therapy for psoriasis-A review of clobetasol propionate 0.025% cream and the clinical relevance of penetration modification. *J Clin Aesthet Dermatol.* 2020;13(2):22-9.
2. Uva L, Miguel D, Pinheiro C. A Mechanisms of action of topical corticosteroids in psoriasis. *Int J Endocrinol.* 2012;2012:561018.
3. Sidgiddi S, Naqvi SMH, Shenoy M. Efficacy and safety of novel formulation of clobetasol propionate 0.025% cream in Indian moderate-to-severe psoriasis patients: Phase-2a, randomized 3-arm study. *Dermatol Ther.* 2021;11(5):1717-32.
4. Draelos ZD, Fowler JF, Cornelison R. A randomized, parallel group, open label, multicenter study to assess the potential for adrenal suppression and systemic drug absorption following multiple dosing with clobetasol propionate cream (Impoyz™), 0.025% versus clobetasol propionate (Temovate®) cream, 0.05% in subjects with moderate to severe plaque psoriasis. *National Society Cutaneous Med.* 2018;2(6):410-20.

**Cite this article as:** Singhal D, Deivasigamani R, Bhavsar BA, Ganiseti LS, Menghani PR, Majid I, et al. Topical clobetasol propionate 0.025%: a therapeutic dermatologic asset. *Int J Res Med Sci* 2022;10:xxx-xx.