

## Case Report

# A rare poisoning with a still rarer presentation: imidacloprid

Prasanth Prasad\*, Sumesh Raj

Department of General Medicine, Sree Gokulam Medical College, Venjaramoodu, Thiruvananthapuram, Kerala, India

**Received:** 02 November 2022

**Revised:** 02 December 2022

**Accepted:** 05 December 2022

**\*Correspondence:**

Dr. Prasanth Prasad,

E-mail: [drprasanthprasad11@gmail.com](mailto:drprasanthprasad11@gmail.com)

**Copyright:** © the author(s), publisher and licensee Medip Academy. This is an open-access article distributed under the terms of the Creative Commons Attribution Non-Commercial License, which permits unrestricted non-commercial use, distribution, and reproduction in any medium, provided the original work is properly cited.

### ABSTRACT

Imidacloprid is a neonicotinoid systemic insecticide. It is used to control agricultural pests. It controls the insects from within the plant. This product is applied to the soil and is taken up by the roots. Imidacloprid belongs to a new chemical family of chloronicotinyl compounds. Its mode of action on the insect nervous system differs from that of a traditional neurotoxic product. This compound is considered relatively safer to human beings, but it can lead to potentially life-threatening complications. Large quantity of this compound when ingested causes fatal complications like respiratory failure, cardiac arrhythmias. We reported a case of imidacloprid poisoning with its rarest unreported complications.

**Keywords:** Imidacloprid, Poisoning, Pancreatitis

### INTRODUCTION

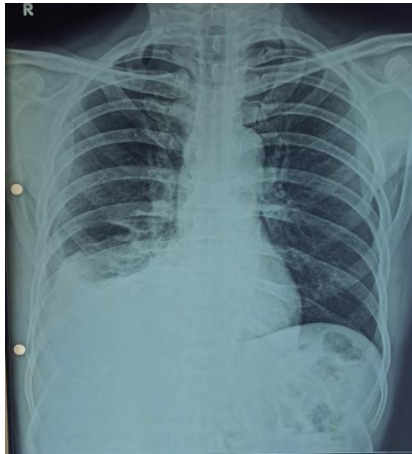
Pesticide poisoning is a major public health problem. Most pesticides used today belong to organophosphorus group. Imidacloprid belongs to neonicotinoid group. It selectively acts on the nervous system of pests via nicotinic acetylcholine receptors of  $\alpha 4\beta 2$  subtype. Here we reported a case of imidacloprid poisoning, which presented to us with respiratory failure and maintained on mechanical ventilator support initially and later developed paroxysmal supraventricular tachycardia. The patient subsequently developed acute pancreatitis and acute kidney injury.

### CASE REPORT

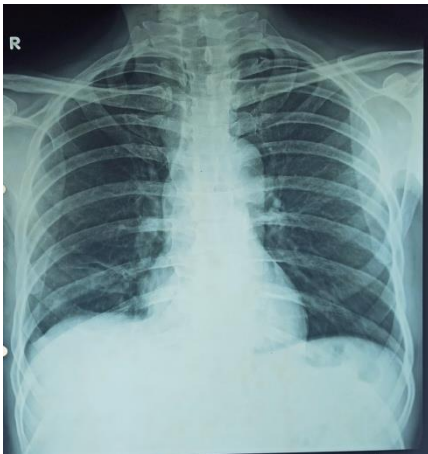A 64-year-old gentleman with no previous comorbidities attended our emergency department with history of consumption of imidacloprid compound of about 250 ml, 2 hours ago. On admission patient was drowsy with very

low GCS (E2V1M1). He was intubated and kept on mechanical ventilator support. He developed transient bradycardia which was reverted by initial bolus dose of parenteral atropine. Investigations revealed an elevated white blood cell count and deranged renal function tests. In view of acute kidney injury with oliguria, patient was initiated on renal replacement therapy for 2 consecutive days with improving urine output and renal parameters. Patient was later extubated. On the 5th day of admission, patient developed diarrhoea with abdominal pain and stools were green in colour. The stool culture did not yield any positive results. CT imaging of abdomen revealed features of acute pancreatitis and with four-fold elevation of amylase and lipase. The patient was initiated on parenteral antibiotics, fluid replacement and continuous nasogastric aspiration. Patient developed paroxysmal supraventricular tachycardia on 6th day of admission and reverted to normal sinus rhythm with intravenous adenosine. Echocardiogram revealed normal

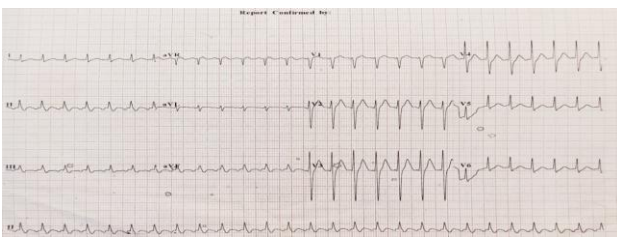
cardiac chambers and Holter study was normal. The patient recovered completely in about two weeks.



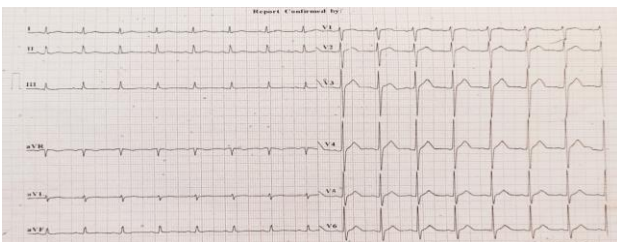
**Figure 1: Right sided pleural effusion.**



**Figure 2: Resolved right side pleural effusion.**



**Figure 3: PSVT on ECG.**



**Figure 4: Sinus rhythm (reverted).**

## DISCUSSION

Imidacloprid is first used in USA as insecticide in 1996. Imidacloprid poisoning was first described on early 2000 period and only few cases had been studied in literature.

Imidacloprid acts as a competitive inhibitor at nicotinic acetylcholine receptors in the nervous system resulting in impairment of normal nerve function.<sup>1</sup>

It has a higher binding strength to insect nerve receptors than mammalian receptors.<sup>2</sup> It has very low toxicity to human beings as per literature.<sup>3,4</sup> To date, neuropsychiatric symptoms of imidacloprid poisoning have been reported in one case with inhalational exposure mainly due to central nicotinic stimulation. Cardiac manifestations include bradycardia, tachycardia and cardiac arrest. As per literature only two cases were reported as respiratory failure and required mechanical ventilator support.<sup>5,6</sup> Imidacloprid when compared with other insecticides especially with organophosphorus compounds gave favourable outcomes.<sup>7</sup> Imidacloprid is the first neonicotinoid compound commercialized with widespread use. It is classified as moderately hazardous based on animal studies.<sup>8</sup> These compounds can be absorbed via ingestion, dermal or inhalational route, and the more severe poisoning occurs with oral ingestion than other routes.<sup>9</sup> A multicentric study from Sri Lanka, Portugal, and Australia by Mohamed et al revealed that plasma concentration of imidacloprid was not useful in the clinical management of imidacloprid poisoning, whereas features such as dyspnea, apnea, coma and mydriasis indicated a severe poisoning.<sup>10</sup> Viradiya et al also reported severe neuropsychiatric symptoms with respiratory failure following ingestion of imidacloprid and recovery with symptomatic treatment.

Our patient developed acute pancreatitis and acute kidney injury, which was unreported till date.

## CONCLUSION

Imidacloprid is less toxic to humans in low quantity, but cardiac toxicities have been reported. Here we discussed an infrequent presentation of this toxin, where the patient went into respiratory failure, arrhythmias, acute kidney injury and acute pancreatitis. Exhaustive search of literature revealed no case of renal and pancreatic involvement with Imidacloprid poisoning till date. This in all probability is the first case report highlighting complications like acute pancreatitis, acute kidney injury with imidacloprid poisoning. We would like to emphasize the need for intensive monitoring and appropriate supportive care of every case of poisoning due to imidacloprid.

*Funding: No funding sources*

*Conflict of interest: None declared*

*Ethical approval: Not required*

## REFERENCES

1. Kumar A, Verma A, Jaiswal K, Kumar S, Prasad R. Emergence of entirely new poisoning in rural India; an upcoming health hazard to the community health. *Indian J Community Health.* 2012;24(3):248-51.
2. Zwart R, Marga O, Henk PM. Nitromethylene heterocycles: selective agonists of nicotinic receptors in locust neurons compared to mouse N1E-115 and BC3H1 cells. *Pest Biochem Physiol.* 1994;48:202-13.
3. Wu I, Lin J, Cheng E. Acute poisoning with the neonicotinoid insecticide imidacloprid in N-methyl pyrrolidone. *Clin Toxicol.* 2001;39(6):617-21.
4. Shadnia S, Moghaddam HH. Fatal intoxication with imidacloprid insecticide. *Am J Emerg Med.* 2008;26(5):634.
5. Rao C, Venkateswarlu V, Surender T, Eddleston M, Buckley NA. Pesticide poisoning in south India – opportunities for prevention and improved medical management. *Trop Med Int Health.* 2005;10:581-8.
6. Eddleston M, Eyer P, Worek F, Mohamed F, Senarathna L, Meyer L, et al. Differences between organophosphorus insecticides in human self-poisoning: a prospective COHORT study. *Lancet.* 2005;366:1452-9.
7. Cimino AM, Boyles AL, Thayer KA, Perry MJ. Effects of neonicotinoid pesticide exposure on human health: a systematic review. *Environ Health Perspect.* 2017;125:155-62.
8. Tomizawa M, Casida JE. Neonicotinoid insecticide toxicology: mechanisms of selective action. *Annu Rev Pharmacol Toxicol.* 2005;45:247-68.
9. Mohamed F, Gawarammana I, Robertson TA, Roberts MS, Palangasinghe C, Zawahir S, et al. Acute human self-poisoning with imidacloprid compound: a neonicotinoid insecticide. *PLoS One.* 2009;4:5127.
10. Viradiya K, Mishra A. Imidacloprid poisoning. *J Assoc Physicians India.* 2011;59:594-5.

**Cite this article as:** Prasad P, Raj S. A rare poisoning with a still rarer presentation: imidacloprid. *Int J Res Med Sci* 2023;11:372-4.