

Case Report

Laparoscopic ureteral antero-position in a retrocaval ureter: a case report and review

Jorge A. Castro-Flores^{1*}, Diana E. Campos-Lopez², Cristopher Cardenas-Cruz³,
Jose de Jesus Vazquez-Hernandez⁴, Mauricio Porrás-Loya⁵, Celeste Espinosa-Coria⁵,
Alejandro Arias-Mendoza⁶, Rodrigo Rueda de Leon-Serna⁷

¹Department of Surgery, Hospital General ISSSTE, San Luis Potosi, Mexico

²Department of Surgery, Hospital Dr. Ignacio Morones Prieto, San Luis Potosi, Mexico

³Department of Investigation, National Institute of Pediatrics, Mexico City, Mexico

⁴Department of Urology, Hospital General ISSSTE, San Luis Potosi, Mexico

⁵Westhill University, Mexico City, Mexico

⁶Escuela Superior de Medicina, IPN, Mexico City, Mexico

⁷Department of Plastic Surgery, Hospital General de Mexico, Mexico City, Mexico

Received: 02 November 2022

Accepted: 17 November 2022

*Correspondence:

Dr. Jorge A. Castro-Flores,

E-mail: diana.clpz1@gmail.com

Copyright: © the author(s), publisher and licensee Medip Academy. This is an open-access article distributed under the terms of the Creative Commons Attribution Non-Commercial License, which permits unrestricted non-commercial use, distribution, and reproduction in any medium, provided the original work is properly cited.

ABSTRACT

Retrocaval ureter is a rare congenital anomaly due to altered development of the vasculature, in which the ureter passes behind the inferior vena cava. This is often secondary vascular variants. Here we present a case about a 41-year-old woman with pain in the right renal fossa, stenotic retrocaval ringlet was established by CT scan. RG showed 43.3 ml/min with obstructive pattern and a bordering left renal exclusion. A laparoscopic transperitoneal approach was realized. Right pyeloureterotomy and antero-position was done. The patient evolved satisfactorily, showed no signs of inflammatory systemic response and continued under post-surgical surveillance until drainage was removed, with progressively diminished serohematic output. Laparoscopic ureteral antero-position with pyeloureterotomy is considered the treatment of choice because it's a less invasive procedure. We recommend the laparoscopic approach because of a low postsurgical complications risk.

Keywords: Retrocaval ureter, Hydronephrosis, Ureteral catheter, Pelvic ureteric junction

INTRODUCTION

Retrocaval ureter, circumcaval ureter, anteuarteral vein or preuarteral vena cava, first described by Hochstetter in 1893, is a rare congenital anomaly due to altered development of the vasculature, in which the ureter passes behind the inferior vena cava (IVC).¹ It has an incidence of 1 per 1000-1500 live newborns, it occurs more frequently in males with a 3:1 ratio, the age at the time of diagnosis is between 20 to 40 years and it is considered an exclusive right-sided pathology, except in exceptional cases, caused by abnormal embryological development of the renal vasculature.²⁻⁴ It is associated

with other congenital anomalies such as horseshoe kidney, renal agenesis, renal hypoplasia, Goldenhar syndrome (first and second branchial arch syndrome), hypospadias, intestinal malrotation, syndactyly, turner syndrome, myelomeningocele, among others.²

The inferior vena cava comes from three venous systems: posterior cardinal, supracardinal and subcardinal⁵. Between the fourth and seventh weeks of gestation, it begins its development by fusion, succession, and regression phenomena, which evolve these three venous systems. The posterior cardinal and subcardinal veins are located ventral to the developing IVC. The right

subcardinal vein forms the prerenal IVC and persists as a tributary of the IVC: the gonadal vein; the subcardinal-supracardinal anastomosis forms the renal segment; and the right supracardinal vein forms the postrenal IVC. The cardinal vein regresses completely by the sixth to eighth week of gestation. Its persistence causes the ureter to be positioned behind the developing IVC, giving rise to the circumcaval ureter.^{2,4-6}

The retrocaval ureter presents two anatomical types depending on the position of the ureter crossing with respect to the inferior vena cava: type I, the most common, corresponds to a ureter whose trajectory is very marked in the form of a hook at the level of L3, in a radiographic image, by ureterography an inverted "J" shape is appreciated; type II, is described as progressive coiling, in this case, the initial portion (uretero-pyelic) of the ureter is the one that has the retrocaval situation.⁵

Most cases are asymptomatic during the first years of life, being until the third or fourth decade when they are discovered incidentally in imaging studies or because they present with some symptomatology.^{1,4} In 80-90% of cases, the main symptom is lumbar or right flank colicky pain that may be insidious or may simulate renoureteral colic, depending on the degree of obstruction.^{5,6} Micro or macroscopic hematuria is present in 20% of cases. Recurrent infections are also seen in up to 20% of cases and may be complicated by acute pyelonephritis, bacteremia, and sepsis.¹

CASE REPORT

A 41-year-old woman with no comorbidities and an unremarkable medical history. In January 2021, she reports pain in the right renal fossa 7/10 in intensity that started 5 months ago, with the pain radiating in a hemibelt pattern (around the abdomen but unilaterally, without crossing the midline).

The patient has a right positive Giordano sign, for which the emergency department initiates abdominal pain protocol and requests simple and contrasted abdominopelvic CT. Imaging tests reveal moderate-severe right ductal ectasia with the presence of a right ureteral retrocaval ringlet in the upper third of the ureter that produces stenosis, with the distal urethral third normal in appearance with no presence of ureteral stones or anatomic alterations (Figure 1). The left ureter is normal. Diagnosis of the right retrocaval ureter is established.

Laboratory findings showed no alterations in kidney function with a creatinine level of 1.12 mg/dL; urine culture showed no signs of bacterial growth. Nevertheless, as outlined by protocol, a renogram with DTPA (diethylenetriaminepentaacetic acid) + diuretic was requested, showing a partial obstructive pattern and a GFR in the right renal unit of 43.3 ml/min and a bordering left renal exclusion (Figure 2).

The patient undergoes transperitoneal laparoscopic surgery where the upper ureteral third is found enlarged in inverted J form with a clear stenosis zone in the lateral face of the inferior vena cava (Figure A). Pyeloureterotomy is performed for subsequent ureteral anteropositioning (Figure 3 C).

The ureteral distal and proximal lumen are exposed. A ureteral catheter is inserted and termino-terminal uretero-ureteroanastomosis is performed (Figure 3 D). Penrose drainage tube is placed facing right.

The patient evolved satisfactorily, showed no signs of inflammatory systemic response and continued under post-surgical surveillance until drainage was removed, with progressively diminished serohematic output. Ureteral catheter was removed after 6 weeks.

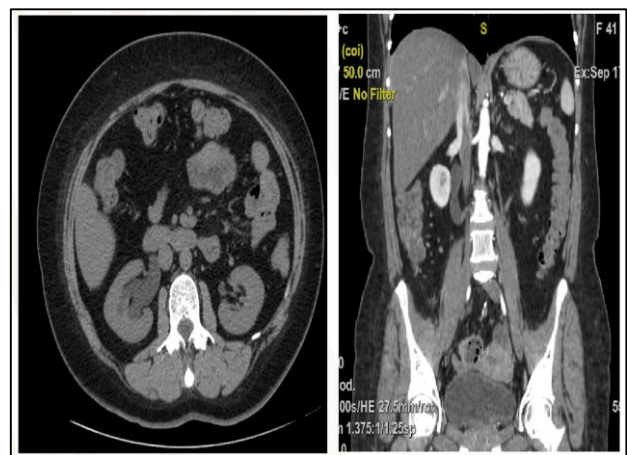

Figure 1: Abdominopelvic CT scan. Moderate-severe right hydronephrosis with the presence of a right ureteral stenotic retrocaval ringlet in the upper third of the ureter.

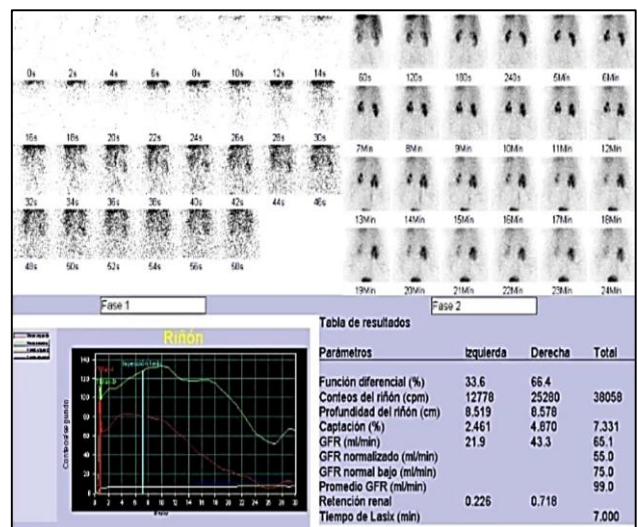


Figure 2: DTPA Renogram. Right partial obstructive pattern and a GFR (43.3 ml/min) and a bordering left renal exclusion.

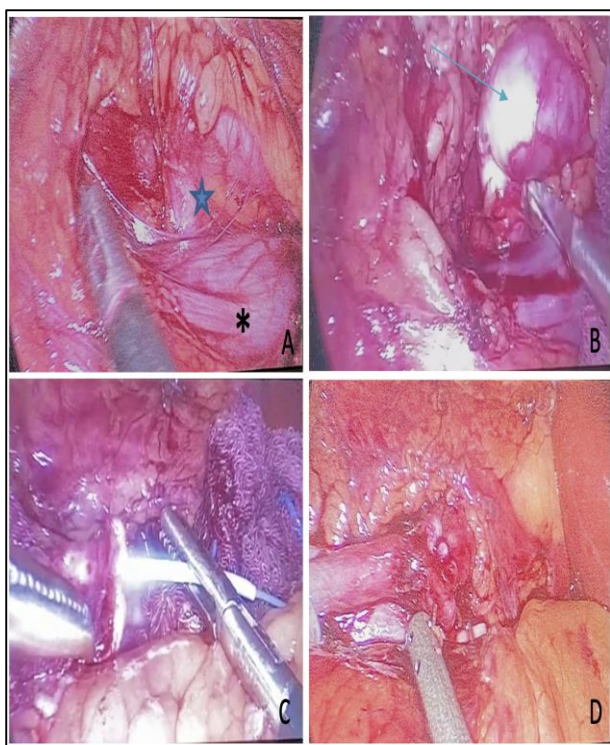


Figure 3 (A-D): Right ureteral retrocaval ringlet (star) near the right gonadal vein (asterisk). Moderate-severe right hydronephrosis due to retrocaval ureter (arrow). Ureteral antero-position: Retrocaval dissection of the ureter, uncrossing, and ureteral catheter colocation. Right uretero-ureteral anastomosis.

DISCUSSION

The retrocaval ureter is a rare congenital abnormality that arises like a pre-ureteral vena cava. Despite its congenital, symptoms may appear in the third or fourth decade. During fetal growth, the right posterior cardinal vein persists leading to a ureteral loop or retrocaval ureter.

Ultrasonography is useful for its diagnosis, where the pyelocaliceal dilatation can be seen showing the obstruction of the urinary tract but being operator-dependent and not assessing renal function, it puts it at a disadvantage compared to other diagnostic studies.⁷ Excretory or intravenous urography shows the characteristic images of inverted "J" or "S", the dilatation of the renal calyces, pelvis, and ureter above the obstruction, however, it is not possible to appreciate the middle or distal ureter to the obstruction.⁵ The gold standard for diagnosing this pathology is computed tomography urography since it is possible to determine the anatomy, the relationship between the ureter and the IVC, and with this the aberrant position of the ureter, the level of ureteral obstruction and the dilatation of the pyelocaliceal system; it also allows differentiation of other obstructive diseases such as tumors or retroperitoneal fibrosis.^{8,2}

Abdominopelvic CT scan define retrocaval ureter anatomy leading to a correct therapeutical approach. The medical and surgical approach depends on the severity of clinical symptoms, hydronephrosis and impairment of renal function.

The correct approach to this congenital obstructive uropathy as well as its adequate renal function is considered of great importance, for which we recognize in this case report the usefulness of renal scintigraphy with DTPA to give an example of a correct therapeutic approach, considering simple nephrectomy in patients with borderline GFR.

The treatment of retrocaval ureter can be conservative in those cases that do not present dilatation or important symptomatology, however, in most of cases, the management is surgical, whose objective is to restore the normal anatomical situation of the ureter.⁵ The surgery approach can be performed openly, laparoscopically trans-peritoneally or retroperitoneally, or even by robotic surgery.⁷ Regardless of the access route, the problem lies in the site of a section of the excretory tract, two strategies can be distinguished: the so-called Harril technique, with a high section of the excretory cavities, at pelvic level, followed by retrocaval dissection of the ureter, uncrossing and pyelic-skin anastomosis; in this technique the retrocaval portion of the ureter is not resected, allowing a wide anastomosis, although leaving the retrocaval segment in situ can generate ureteral stenosis due to poor vitality. The ureteral section at the level of the retrocaval passage and then abandonment or exeresis of the retrocaval ureter and uretero-ureteral anastomosis over a double J catheter is the technique of choice in minimally invasive surgery.

Laparoscopic ureteral antero-position is considered the treatment of choice, including pyeloureterotomy as well as uretero-ureteroanastomosis over a ureteral catheter. Despite acknowledging that the resection of the stenotic ureteral area has a good success rate, low risk of urinary leakage, and a high probability of total recovery in the short term, it is still under much controversy, which is why it is left to the surgeon's judgement. When renal function is significantly impaired and it is impossible to save the organ, simple nephrectomy becomes the technique of choice.⁵

CONCLUSION

Due to the lack of a gold standard surgical treatment for retrocaval ureter, multiple surgical techniques can be used. However, as technical knowledge has evolved, new techniques have emerged. Today, the minimally invasive laparoscopic technique offers the patient a reliable therapeutic result, equal to that of open surgery. It has been seen that it drastically reduces the risk of infection, and postoperative pain, requires less anesthesia, hospital discharge is early, and the aesthetic result is more satisfactory. Today it has almost completely replaced the

open technique, which should be considered the first-line therapy for this pathology.

Funding: No funding sources

Conflict of interest: None declared

Ethical approval: Not required

REFERENCES

1. Kennedy DR, Lenaghan D. The surgical treatment of retrocaval ureter. Aust N Z J Surg. 1977;47(4):486-90.
2. Vásquez-Lastra C, Cisneros MB, Contreras EA, Lomelín JP, Figueroa GR, Castro GA. Uréter retrocavo. Anales Médicos Asociación Médica Hospital ABC. 2005;50:130-5.
3. Rosales-Velázquez CE, Ruvalcaba-Oceguera GE, Zepeda-Aguilar A. Uréter retro- cavo: reporte de un caso y revisión de la bibliografía. Rev Mex Urol. 2020;80(3):1-10.
4. Ratkal JM, Jadhav R, Naique Dessai RR. Circumcaval Ureter-the Paradigm Shift in Diagnosis and Management. Indian J Surg. 2016;78(1):37-40.
5. Cornu J-N, Sèbe P. Uréter retrocavo. EMC Urol. 2011;43(2):1-5.
6. Xiaodong Z, Shukun H, Jichuan Z, Xiaofeng W, Guangdong M, Xingke Q. Diagnosis and treatment of retrocaval ureter. Eur Urol. 1990;18:207-10.
7. Abdessater M, El Khoury R, Elias S, Bart S, Coloby P, Sleiman W. Diagnosis and laparoscopic management of retrocaval ureter: A review of the literature and our case series. Int J Surg Case Rep. 2019;59:165-75.
8. Kulkarni NV, Sarda VR, Gupta KC. Retrocaval ureter: a rare cause of urinary tract obstruction. Int Surg J. 2019;6:3427-9.

Cite this article as: Castro-Flores JA, Campos-Lopez DE, Cardenas-Cruz C, Vazquez-Hernandez JDJ, Porrás-Loya M, Espinosa-Coria C et al. Laparoscopic ureteral antero-position in a retrocaval ureter: a case report and review. Int J Res Med Sci 2022;10:2932-5.