International Journal of Research in Medical Sciences
Kathpalia S et al. Int J Res Med Sci. 2023 Jan;11(1):309-315
www.msjonline.org
pISSN 2320-6071 | eISSN 2320-6012
DOI: https://dx.doi.org/10.18203/2320-6012.ijrms20223260

Case Series

Myriad of magnetic resonance imaging findings in human immune deficiency virus positive patients with central nervous system manifestations

Sudhanshu Kathpalia, Namrita Sachdev, Priyanka, Civilee Nanda*

Department of Radiodiagnosis, Atal Bihari Vajpayee Institute of Medical Sciences and Dr. Ram Manohar Lohia Hospital, New Delhi, India

Received: 19 November 2022
Revised: 29 November 2022
Accepted: 30 November 2022

***Correspondence:**
Dr. Civilee Nanda,
E-mail: civunanda@gmail.com

Copyright: © the author(s), publisher and licensee Medip Academy. This is an open-access article distributed under the terms of the Creative Commons Attribution Non-Commercial License, which permits unrestricted non-commercial use, distribution, and reproduction in any medium, provided the original work is properly cited.

ABSTRACT

Human immuno-deficiency virus (HIV) is a neurotropic virus that affects the central nervous system (CNS) early in the course of illness. Neurological complications are seen in about 60% of the patients and were the major presenting complaints in 20% patients in the pre-highly active anti-retroviral therapy (HAART) era. Imaging especially magnetic resonance imaging (MRI) is thus helpful in shedding light on the causative factor of neurological symptoms in acquired immunodeficiency syndrome (AIDS) patients. It can be used as an adjunct to clinical features and serological/cerebrospinal fluid (CSF) findings to diagnose CNS abnormalities with greater confidence and modify therapeutic strategy accordingly. We conducted a cross-sectional observational study with 12 HIV positive patients for a period of 12 months. MRI evaluation was done using conventional brain sequences. HIV encephalopathy was diagnosed on imaging in 8 patients, polymorphic light eruption (PMLE) in 2 patients, CNS toxoplasmosis in 1 patient and CNS lymphoma in one patient. The clinical details and imaging features of the various manifestations are described. Though there might be a certain degree of overlap in the imaging findings, some imaging findings provide important diagnostic clues for specific diseases, especially on MRI.

Keywords: CNS manifestations, HIV positive patients, AIDS, HIV related CNS disease

INTRODUCTION

Human immunodeficiency virus (HIV) is a retrovirus responsible for causing acquired immuno-deficiency syndrome (AIDS) which currently has the status of epidemic in India. It has two subtypes – HIV 1 and HIV 2, of which HIV 1 is prevalent globally while HIV 2 is most commonly seen in the West African population. According to a retrospective analysis done in 2013, there is the presence of HIV 2 infection in India especially in the southern and western states.[1] Although the prevalence of this fatal infection has been on the declining trend since its peak in 2000, there were still 23.49 lakh people living with HIV (PLHIV) in the 2019 surveillance, with an adult (15–49 years) HIV prevalence of 0.22%. There were 69.22 thousand new HIV infections and 58.96 thousand AIDS-related deaths in the year 2019.[2] The decrease in incidence and AIDS related death can be attributed to the introduction of highly active antiretroviral therapy (HAART).[3]

Post- infection with the virus, there is a long latent period till the onset of symptoms. Seroconversion after acquiring the virus is known as primary HIV infection during which the virus enters the CD4 T-lymphocytes and starts replication, causing a transient rise in the viral load and fall in CD4 lymphocytes. Following this phase there is very low rates of viral replication leading to a long

asymptomatic/group II phase. It might also lead to persistent generalized lymphadenopathy/group III infection presenting as lymphadenopathy in extra-inguinal sites in an otherwise normal person.[4] It then leads to a symptomatic infection, with AIDS as the final stage of the illness (Figure 1).

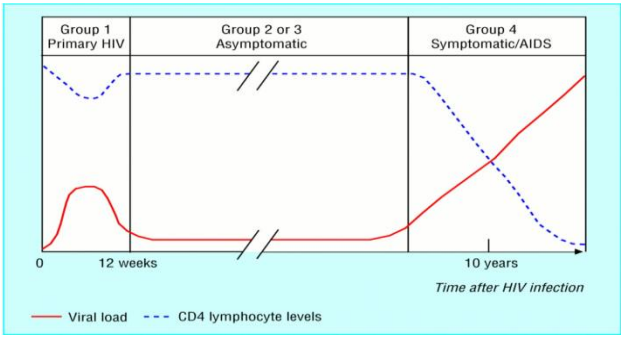

Figure 1: Natural history of HIV infection.[4]

HIV is a neurotropic virus that affects the CNS early in the course of illness. Neurological complications are seen in about 60% of the patients and were the major presenting complaints in 20% patients in the pre-HAART era. The neurological manifestations can be the result of the virus itself, opportunistic infections and neoplasms or from drug related complications. There can be a multitude of opportunistic infections like progressive multifocal leukoencephalopathy (PML), cytomegalovirus (CMV) infection, tuberculosis and fungal infections. Immune reconstitution inflammatory syndrome (IRIS) is a complication of HAART due to improvement in immunity status that causes transient worsening of symptoms or radiologic features of opportunistic infection after initiation of therapy. Imaging helps in identification of the cause of neurological symptoms in HIV patients and thus can guide treatment strategies.[5,6]

We evaluated the imaging and clinical data of 12 HIV positive patients (10 males and 2 females), ranging from 20 to 55 years old, who presented with neurological complaints to the department of radiodiagnosis, ABVIMS and Dr. Ram Manohar Lohia Hospital from 01st September 2021 to 31st August 2022 for a duration of 12 months. Clinical details regarding presentation, management and evolution of disease were obtained in all cases. All patients underwent MR imaging in a Seimens 3-T system using T1 weighted, T2 weighted sequences, diffusion weighted imaging, susceptibility weighted imaging and post contrast imaging after administration of gadopentetate dimeglumine (0.1 mmol/kg). One of the patients underwent arterial spin labelling for evaluation of perfusion parameters.

CASE SERIES

Clinical details

Our study population comprised mostly of males on the age group of 20-35 years. 83.33% patients were males while only 16.7% patients were females. All patients presented with neurological complaints of cognitive decline, altered sensorium and personality changes. Seizures and focal neurological deficit were noted in one patient.

HIV encephalopathy was diagnosed on imaging in 8 patients, PMLE in 2 patients, CNS toxoplasmosis in 1 patient and CNS lymphoma in one patient (Figure 2).

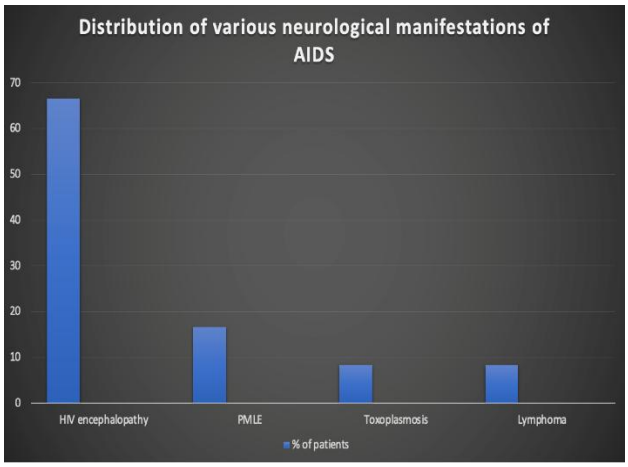

Figure 2: Distribution of cases of CNS complications in HIV positive patients in the study sample.

AIDS dementia complex/HIV encephalopathy

ADC was seen in majority of the patients i.e., 8 out of 12 cases (66.6%). It is the most common neurological manifestation of AIDS and is primarily due to the neurotropic effect of the virus.[7,8] 6 out of 8 patients presented with long term cognitive impairment, 4 patients presented with complaints of forgetfulness, and 3 patients presented with rapidly evolving altered behaviour (Table 1). CSF serology revealed increased protein concentration and lymphocytes with normal glucose levels with positive HIV RNA on polymerase chain reaction (PCR) analysis. Non-contrast computed tomography (NCCT) brain in all patients revealed cortical atrophic changes in the form of widened sulcal and cisternal spaces with prominence of ventricular system.

MR imaging in all patients revealed bilaterally symmetrical areas of confluent T2/FLAIR hyperintensities without any mass effect involving periventricular white matter along with gross cerebral atrophy. Involvement of deep white matter in the form of T2/FLAIR hyperintensities in the anterior and posterior limbs of bilateral internal capsule was noted in 6 out of 8 patients (75%). 2 of 8 patients (25%) revealed patchy involvement of subcortical U-fibres in bilateral frontal region. There was no evidence of any blooming on susceptibility weighted images or restriction on DWI/ADC maps. No enhancement was seen on post contrast study (Figures 3 and 4).

Table 1: Clinical scenario in patients of AIDS dementia complex (ADC).

Clinical presentation in ADC	No. of patients (percentage)
Long term cognitive impairment	6 (75)
Forgetfulness	4 (50)
Rapidly evolving altered behaviour	3 (37.5)

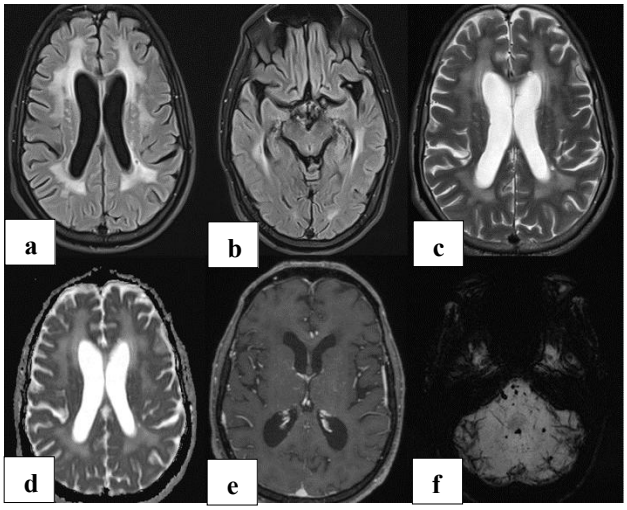

Figure 3: 56-year PLHA male presented with progressive forgetfulness and weakness; (a) and (b) FLAIR, and T2W images reveal symmetric, confluent periventricular hyperintensities involving deep and periventricular white matter with sparing of U-fibres along with atrophic changes. ADC maps reveal (d) T2 shine through, (e) with no enhancement on post contrast images. On SWI, multiple punctate blooming foci were noted in pons, (f) cerebellum and basal ganglia (not shown).

Progressive multifocal leukoencephalopathy (PMLE)

PMLE was the found in 2 out of 12 (16.6%) patients in our study group comprising 20% of the study population.

Case 1

PLHA presented with altered sensorium. CD4 count was 67 cells/microliter. Cryptocccal antigen was negative, HSV serology was negative, CSF Gene XPERT (CBNAAT) was positive. HAART was initiated in July 2021 following which ATT was started in August 2021.

MRI brain showed asymmetric confluent areas of T2/FLAIR hyperintensity in bilateral periventricular white matter, splenium of corpus callosum, left centrum semiovale, deep and subcortical white matter in bilateral fronto-occipital region(left>right), left insular and left temporal lobe. Few small areas of signal suppression were noted on FLAIR images s/o cyst formation. Few punctate T2/FLAIR hyperintense foci were also noted in corona radiata in bilateral fronto-parietal region, bilateral thalami, pons and cerebellar hemispheres. On post contrast study punctate foci of enhancement was noted in bilateral cerebral hemispheres (Figure 5). A diagnosis of PMLE was made and a second possibility of PML-IRIS was also considered.

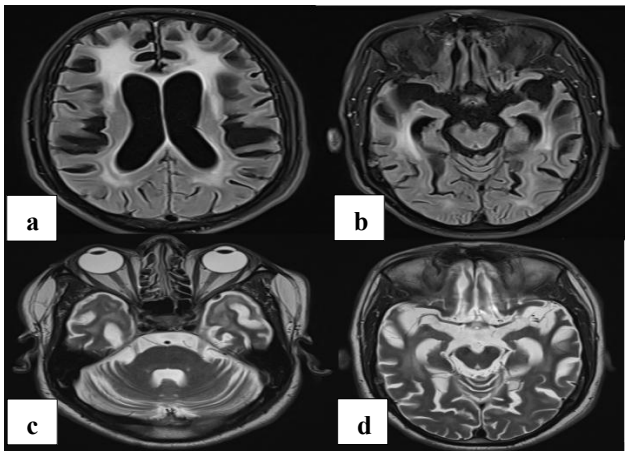

Figure 4: 34-year PLHA male presented with altered sensorium; (a) and (b) FLAIR; (c) and (d) T2W images reveal symmetric, confluent periventricular hyperintensities involving deep and periventricular white matter along with involvement of subcortical U-fibres in bilateral frontal region and atrophic changes.

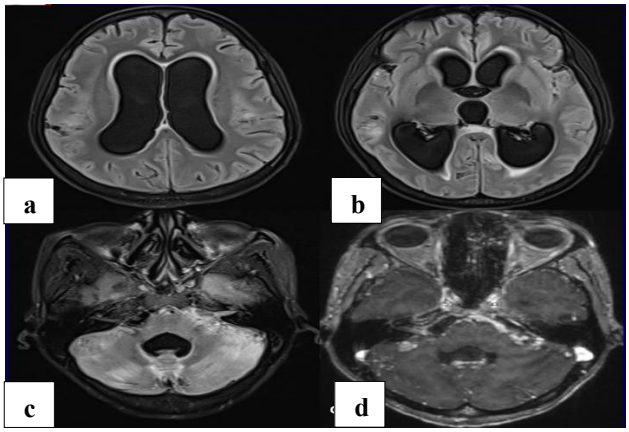

Figure 5: HIV positive patient presented with altered sensorium with a CD4 count of 250 U. Patient also had tuberculosis on ATT for 4 weeks and HAART for 2 weeks after initiation of ATT. Ill-defined patchy areas of T2/FLAIR hyperintensity in subcortical white matter. There is communicating hydrocephalus due to cisternal exudates. Punctate enhancement is noted in bilateral cerebellar hemispheres.

Case 2

HIV positive patient presented with altered sensorium with deteriorating general condition. She had a CD4 count of 250 cells/microliter. Patient also had tuberculosis for

which she was receiving ATT for 4 weeks. HAART was started 2 weeks after initiation of ATT.

MRI brain revealed multiple ill-defined patchy areas of altered signal intensity in the subcortical white matter of bilateral inferior parietal lobes, right temporal lobe, anterior aspect of pons on right side, bilateral cerebellar hemispheres and right middle cerebellar peduncle appearing iso-hypointense on T1W and hyperintense on T2W/FLAIR images. Blooming was not seen on GRE images and there was no evidence of diffusion restriction on DWI/ADC maps. On post contrast images, supra tentorial lesions did not show enhancement while faint punctate enhancement was noted in bilateral cerebellar hemispheres (Figure 6).

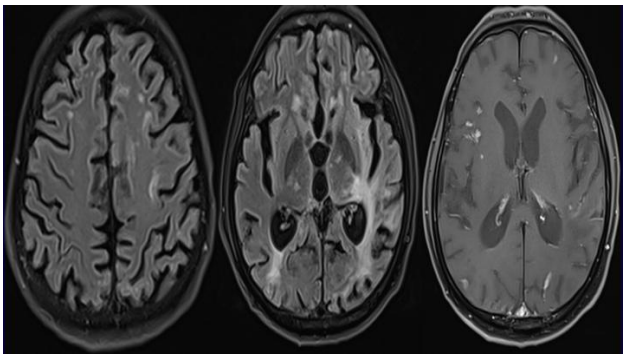

Figure 6: PLHA presented with altered sensorium with a CD4 count was 67 cells. Asymmetric confluent areas of T2/FLAIR hyperintensity in bilateral periventricular white matter deep and subcortical white matter in bilateral fronto-occipital region (left>right), left insular and left temporal lobe. Punctate foci of enhenacement noted in bilateral cerebral hemispheres.

CNS toxoplasmosis

It was reported in one of the 12 patients (8.3% cases). The patient was a 20-year male with complaints of recurrent infections for two months, fever and altered sensorium for two weeks and 2 episodes of generalized tonic clonic seizures over a period of 48 hours. Post- admission HIV serology was positive with severely reduced CD4 count (10 cells/microlitre).

MRI brain was done which revealed multiple well defined oval solitary and confluent lesions appearing heterogeneously hyperintense on T2/FLAIR images, and hypointense with a hyperintense rim on T1WI with significant perilesional edema in right thalamus, bilateral putamina, heads of bilateral caudate nuclei, right cerebral peduncle, cortex of right occipital region and medial temporal lobe, bilateral frontoparietal region, bilateral cerebellar hemispheres. On DWI, significant restriction of diffusion was present. On post contrast images rim enhancement with eccentric mural nodule was noted. On SWI few foci of blooming, appearing bright on phase images were noted within, s/o hemorrhagic foci. On perfusion images, reduction in cerebral blood volume (CBV), cerebral blood flow (CBF) and time to peak (TTP) was found. The lesions were causing mass effect in form of midline shift of 4.5 mm to left (Figure 7). The findings favoured a diagnosis of cerebral toxoplasmosis. Post-imaging evaluation, serum titres for *Toxoplasma gondii* were found to be elevated (612 IU/ml).

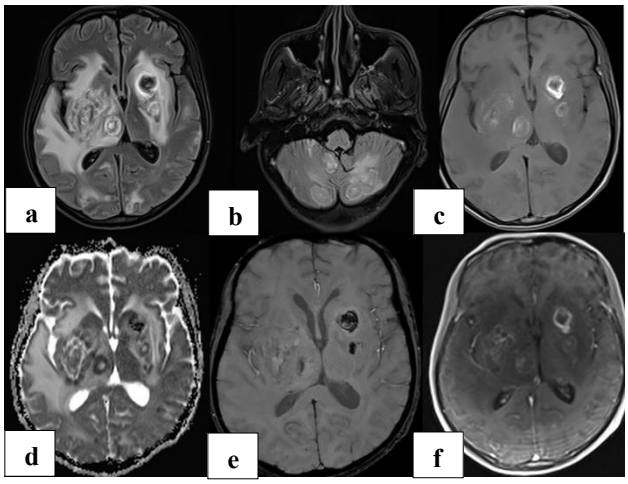

Figure 7: 20-year HIV positive male with severely reduced CD4 count (10 cells/microlitre); (a) and (b) imaging revealed concentric hyper and hypointensity lesions on FLAIR images in bilateral basal ganglia, right thalamus and bilateral cerebellar hemispheres; (c), (d), and (e) the lesions were hypo-isointense on T1 with a hyperintense rim that showed blooming and restriction s/o hemorrhagic areas; and (f) there was ring enhancement of lesions with eccentric target sign.

CNS lymphoma

It was reported in one of the 12 patients (8.3% cases). 47 years recently diagnosed HIV positive male presented with generalized weakness, headache, multiple episodes of vomiting and altered behavior for a period of 15-20 days. CD4 count was 120 cells/microlitre. NCCT head was done in a private center which revealed ill-defined iso-mildly hyperdense areas involving the splenium of corpus callosum extending to bilateral parietal lobes. Patient was referred to our hospital for further evaluation and management.

MRI brain revealed multiple well circumscribed variable sized lesions in periventricular and deep white matter of left frontal lobe, left parietal lobe, splenium, genu and body of corpus callosum, left thalamus and deep white matter of bilateral cerebellum. The lesion in the splenium of corpus callosum was seen to cross the midline and extend into the contralateral cerebral hemisphere. The lesions appeared hyperintense on T1WI, heterogeneously hyperintense on T2WI/ FLAIR images and showed areas of diffusion restriction on DWI. On post contrast images, intense peripheral and heterogenous enhancement was seen. MRS showed mildly increased choline with reduced

NAA levels. Minimal to mild surrounding perilesional edema was present (Figure 8).

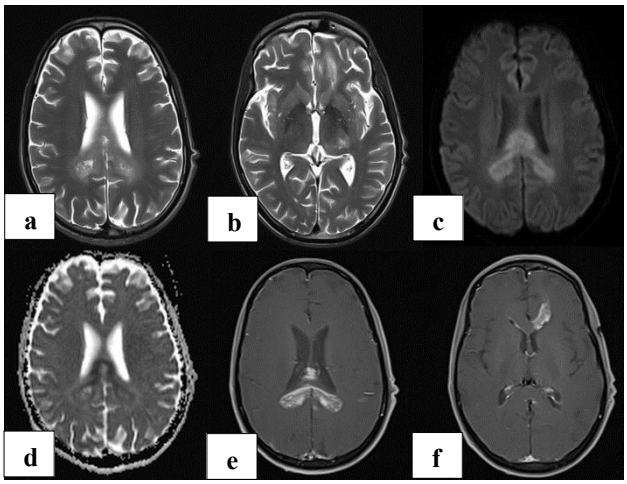

Figure 8: 47-year recently diagnosed HIV positive male presented with generalized weakness; (a) - (d) on T2W images heterogeneously hyperintense geographical lesion in periventricular region extending to bilateral parietal hemispheres via splenium of corpus callosum with restricted diffusion on DWI. Post contrast images reveal heterogeneous and predominantly peripheral enhancement.

DISCUSSION

The spectrum of CNS manifestations of HIV are mainly due to neurotropic effect of the virus, opportunistic infections and neoplasms due to severe immunosuppression and post-HAART complications.[7] Though there might be a certain degree of overlap in the imaging findings, some imaging findings provide important diagnostic clues for specific diseases, especially on MRI.

HIV encephalopathy also known as HIV associated neurocognitive disorder (HAND) is the most common neurological manifestation and is due to neuronal invasion by the retrovirus. The patients present with progressive dementia, altered sensorium and behavioural changes.[8,9] The lesions are noted symmetrically involving the central regions i.e. the periventricular white matter with sparing of the U fibres. In advanced stages, there may be involvement of the basal ganglia and subcortical white matter. Brainstem and cerebellar lesions can also be seen. MRI due to its superior soft tissue resolution can delineate the lesions better than CT which is mostly negative in such patients. These lesions appear hyperintense on T2/FLAIR images without any mass effect or contrast enhancement. Cortical atrophy is commonly found and is one of the earliest manifestations.[3,10]

Progressive multifocal leukoencephalopathy is a subacute progressive demyelinating disease caused by JC polyoma virus in immunocompromised patients. The clinical features are altered sensorium, cognitive decline and 20% patients show seizures and focal neurologic deficits. The diagnosis was initially established on identification of triad of demyelination, bizarre astrocytes and enlarged oligodendrocytes on histopathological examination. However, granule cell neuronopathy of the cerebellum and JC encephalopathy share similar histologic findings. Thus, based on clinical and imaging features along with demonstration of JC virus in CSF, the diagnosis of PMLE can be clinched (Figure 9).[3]

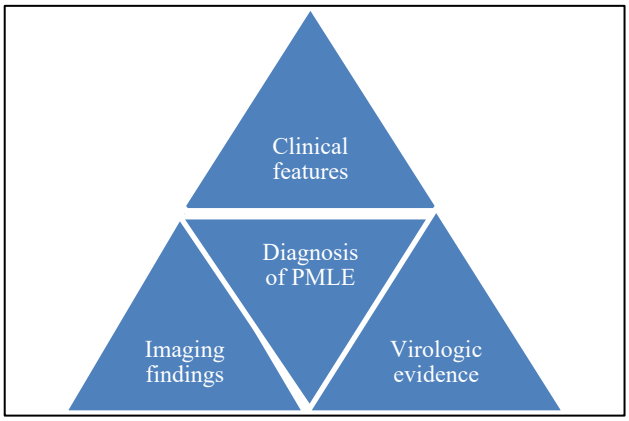

Figure 9: Diagnostic criteria for PMLE.

However, the PCR for JC virus often has false negative results. In presence of clinical and imaging features only, the diagnosis of presumptive PMLE is made.[3] On MRI, the lesions appear hypointense on T1 and hyperintense on T2 involving the periventricular and subcortical white matter and without any mass effect.[11,12] They have a bilateral, multifocal and asymmetric distribution pattern with greater involvement of subcortical white matter. Microcystic changes may be noted in an active lesion. Mass effect is not commonly seen. There is significant involvement of the deep gray matter especially basal ganglia and thalami. Approximately a third of the cases show posterior fossa involvement especially the middle cerebellar peduncle and pons. On post contrast study, these lesions either show no enhancement or faint/punctate enhancement in approximately 10% cases.[3,12] The presence of mass effect, increased T1 hypointensity and increased atrophy are poor prognostic indicators.[3]

Toxoplasmosis is caused by an obligate intracellular parasite *T. gondii* and is the most common cause focal mass lesion in HIV positive patients.[13] It is usually caused by reactivation of previous latent infection, hence antibody titers are not much helpful in clinching the diagnosis of toxoplasmosis.[14,15] The patients present with focal neurological symptoms, or due to symptoms from mass effect. They are usually severely immunocompromised with CD4 counts less than 100 cells/microliter.[7] NCCT reveals multiple areas of hypodensity in the basal ganglia, thalamus and corticomedullary junction with marked perilesional edema showing ring enhancement on CECT. On MR images, they appear as T1 hypointense lesions and show alternate areas of hypo- and hyper intensity on T2W

images. Eccentric target sign is seen on T1C+ images due to rim enhancement with a peripheral enhancing mural nodule.[7]

CNS lymphoma is the most common AIDS defining malignancy and its prevalence has been least affected by the initiation of HAART. Owing to its rapid progression early diagnosis is essential.[16] Imaging along with clinical features aid in the diagnosis and presence of EBV DNA in CSF gives further clue towards CNS lymphoma. They may present as single or multiple (uncommon) masses, especially in the basal ganglia and deep white matter in periventricular location. Central necrosis and hemorrhage are common in AIDS related lymphoma. They are seen too often cross the midline. The major differential is CNS toxoplasmosis, however the presence of singular lesions, choline peak, and higher rCBV favors the diagnosis of CNS lymphoma (Figure 10 and Table 2). Nuclear imaging is also helpful as lymphoma appears hot while toxoplasmosis lesions appear cold.[17]

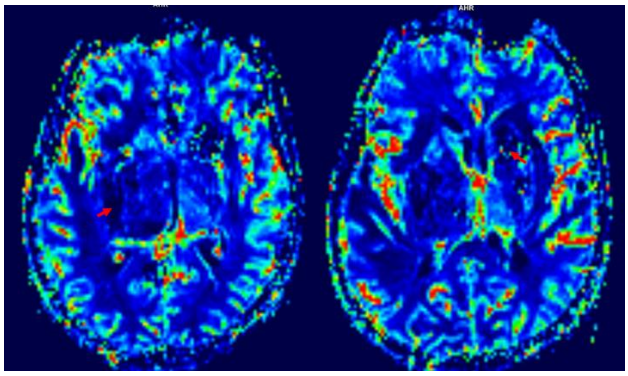

Figure 10: Reduced rCBV within the lesions in the case of CNS toxoplasmosis (arrows).

Table 2: Imaging manifestations in various neurological conditions in HIV positive patient.

Imaging findings	HAND	PMLE	Toxoplasmosis	PCNSL
Location	Central (periventricular)	Subcortical	Basal ganglia, thalamus	Corpus callosum, periventricular white matter
Size	NA	NA	<4cm	>4 cm
Edema	None	None	Moderate to marked	None to mild
Contrast enhancement	None	None to mild	Eccentric target sign	Ring like enhancement
rCBV	NA	NA	Reduced	Raised

CONCLUSION

Imaging especially MRI is thus helpful in shedding light on the causative factor of neurological symptoms in AIDS patients. It can be used as an adjunct to clinical features and serological/CSF findings to diagnose CNS abnormalities with greater confidence and modify therapeutic strategy accordingly.

Funding: No funding sources
Conflict of interest: None declared
Ethical approval: Not required

REFERENCES

1. Ingole NA, Sarkate PP, Paranjpe SM, Shinde SD, Lall SS, Mehta PR. HIV-2 infection: where are we today? J Global Infect Dis. 2013;5(3):110.
2. National AIDS Control Organization. HIV Surveillance. 2019. Available at: http://naco.gov.in/surveillance-epidemiology-0. Accessed on 18 November 2022.
3. L.Celso Hygino da Cruz. Intracranial Infection. In: Scott W. Atlas' Magnetic Resonance Imaging of the Brain and Spine. 5th edition. Wolters Kluwer. 2017;953-72.
4. Mindel A, Tenant-Flowers M. Natural history and management of early HIV infection. BMJ. 2001;322(7297):1290-3.
5. Levy RM, Bredesen DE, Rosenblum ML. Neurological manifestations of the acquired immunodeficiency syndrome (AIDS): experience at UCSF and review of the literature. J Neurosurg. 1985;62(4):475-95.
6. de la Monte SM, Ho DD, Schooley RT, Hirsch MS, Richardson EP Jr. Subacute encephalomyelitis of AIDS and its relation to HTLV-III infection. Neurology. 1987;37(4):562-9.
7. Smith AB, Smirniotopoulos JG, Rushing EJ. Central nervous system infections associated with human immunodeficiency virus infection: radiologic-pathologic correlation. Radiographics. 2008;28(7):2033-58.
8. Sakai M, Higashi M, Fujiwara T, Uehira T, Shirasaka T, Nakanishi K, Kashiwagi N, Tanaka H, Terada H, Tomiyama N. MRI imaging features of HIV-related central nervous system diseases: diagnosis by pattern recognition in daily practice. Japanese J Radiol. 2021;39(11):1023-38.
9. Abidin AZ, Dsouza AM, Nagarajan MB, Wang L, Qiu X, Schifitto G, et al. Alteration of brain network topology in HIV-associated neurocognitive disorder: a novel functional connectivity perspective. Neuroimage Clin. 2017;17:768-77.
10. Cortese I, Reich DS, Nath A. Progressive multifocal leukoencephalopathy and the spectrum of JC virus-related disease. Nat Rev Neurol. 2021;17(1):37-51.
11. Berger JR, Aksamit AJ, Clifford DB, Davis L, Koralnik IJ, Sejvar JJ, et al. PML diagnostic criteria:

consensus statement from the AAN Neuroinfectious disease section. Neurology. 2013;80:1430-8.
12. Thurnher MM, Post MJ, Rieger A, Kleibl-Popov C, Loewe C, Schindler E. Initial and follow-up MR imaging findings in AIDS-related progressive multifocal leukoencephalopathy treated with highly active antiretroviral therapy. AJNR Am J Neuroradiol. 2001;22:977-84.
13. Wright D, Schneider A, Berger JR. Central nervous system opportunistic infections. Neuroimaging Clin N Am. 1997;7(3):513-25.
14. Luft BJ, Remington JS. Toxoplasmic encephalitis in AIDS. Clin Infect Dis. 1992;15(2):211-22.
15. Zufferey J, Sugar A, Rudaz P, Bille J, Glauser MP, Chave JP. Prevalence of latent toxoplasmosis and serological diagnosis of active infection in HIV positive patients. Eur J Clin Microbiol Infect Dis. 1993;12(8):591-5.
16. Gupta NK, Nolan A, Omuro A, Reid EG, Wang CC, Mannis G, et al. Long-term survival in AIDS-related primary central nervous system lymphoma. Neuro Oncol. 2017;19:99-108.
17. Annie G. Osborn. In: Osborn's Brain Imaging, pathology and anatomy. 2nd edition. Elsevier. 2018;417-48.

Cite this article as: Kathpalia S, Sachdev N, Priyanka, Nanda C. Myriad of magnetic resonance imaging findings in human immune deficiency virus positive patients with central nervous system manifestations. Int J Res Med Sci 2023;11:309-15.