

Case Report

A case report of Kounis syndrome: acute myocardial injury caused by multiple bee stings

Megha S.*, Gaurav Agarwal

Department of General Medicine, SRG Hospital and Medical College, Jhalawar, Rajasthan, India

Received: 09 December 2022

Accepted: 05 January 2023

***Correspondence:**

Dr. Megha S.,

E-mail: meghasanumanu@gmail.com

Copyright: © the author(s), publisher and licensee Medip Academy. This is an open-access article distributed under the terms of the Creative Commons Attribution Non-Commercial License, which permits unrestricted non-commercial use, distribution, and reproduction in any medium, provided the original work is properly cited.

ABSTRACT

Kounis syndrome, also known as “allergic angina syndrome” or “allergic myocardial infarction”, refers to acute coronary syndrome secondary to hypersensitivity reaction as a result of exposure to various allergens. Signs and symptoms may include chest pain, with or without raised troponins and cardiac enzymes, vomiting, syncope, hypotension or acute renal failure. A 60-year-old male, farmer by occupation, was bitten by multiple bees over head, neck region and bilateral upper limbs in the afternoon on 04/03/2022. On presentation, vitals were stable. After 2 hours, patient developed severe chest pain, palpitations, and dizziness. ECG showed inferior wall ST elevation MI. Subsequently CPK, CK-MB, troponin I were done, which were found to be elevated. Echocardiography was done, which showed regional wall motion abnormality in the inferior wall. Patient was treated with anticoagulants and antiplatelets. CT coronary angiography showed healthy coronaries. In literature, we had few cases of myocardial infarction following bee sting. In acute myocardial infarction after bee stings, it has been suggested that vasoconstriction secondary to mediators released after the sting, aggravated by exogenous adrenaline and platelet aggregation contributes to myocardial ischemia. Cardiac complications can accompany bee sting. Intensive supportive treatment in intensive or coronary care facilities with administration of drugs to treat complications early in the course of the illness will improve the outcome.

Keywords: Kounis syndrome, Allergic myocardial infarction, Bee sting

INTRODUCTION

The acute coronary syndrome resulting from an allergic reaction is referred to as Kounis syndrome. Kounis and Zafras reported the first case in 1991.¹ Envenomation by bee sting is a common occurrence with self-limiting local reactions in most cases.² Rarely, acute coronary syndrome may occur after an insect sting.³ Here we report a case of inferior wall ST elevation MI following bee sting.

CASE REPORT

A 60-year-old male, farmer by occupation, was bitten by multiple bees over head, neck region and bilateral upper limbs in the afternoon on 04/03/2022. On presentation, he was noted to have a normal pulse (86/min), blood

pressure (124/82 mmHg), and respiration (14/min). There was no respiratory distress. He was treated for his local symptoms. After 2 hours, patient developed severe chest pain, palpitations and dizziness. On re-evaluation, his pulse (86/min), blood pressure (110/76 mmHg), respiratory rate (20/min), temperature (98.8°F), and systemic examination was normal. However, ECG showed ST-elevation in the inferior wall leads (Figure 2) with associated significant elevation of cardiac enzymes (Troponin T 4 ng/ml, CKMB 290 U/L, CPK 2800U/L, LDH 750, Trop I 1ng/ml). The echocardiographic finding revealed an ejection fraction of 50%, grade 1 diastolic dysfunction along with regional wall motion abnormality (RWMA) in the inferior wall. CT coronary angiography showed healthy coronaries. He was managed with low molecular weight heparin, dual antiplatelets, statins, ACE-inhibitors and beta-blockers.

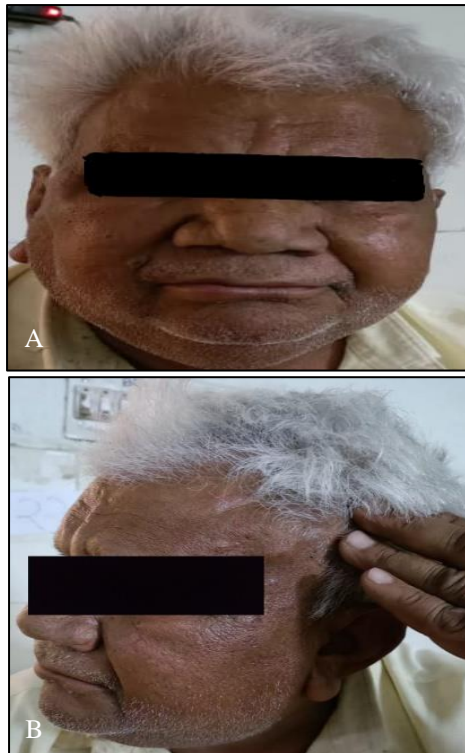

Figure 1 (A and B): Pictures of the patient with angioedema following bee sting.

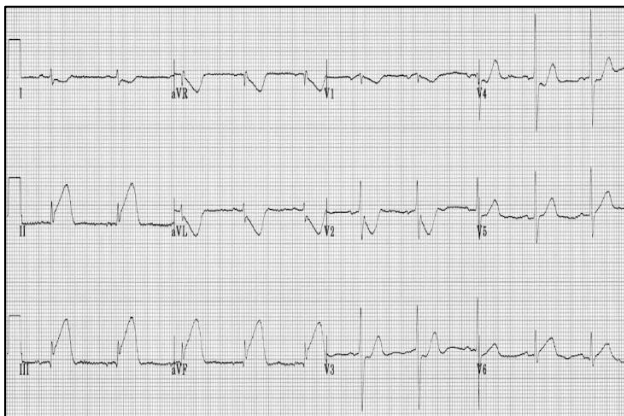


Figure 2: ECG showing inferior wall ST elevation MI.

DISCUSSION

The underlying pathophysiology in Kounis syndrome is due to coronary vasospasm and atheromatous plaque

rupture.⁴ Kounis syndrome is divided into three subtypes: Type I patients don't have any predisposing factors for coronary artery disease. The allergic event leads to coronary artery spasm resulting in chest pain and ECG changes. In Type II, there is angiographic evidence of coronary artery disease during an acute allergic reaction. In type III patients with coronary thrombosis (including stent thrombosis), the presence of eosinophils and mast cells have been demonstrated.^{5,6}

CONCLUSION

Kounis syndrome is a rare cause of acute coronary syndrome with atypical presentations. This along with the lack of knowledge of this entity may lead to delay in diagnosis and treatment. The present case highlights the importance of suspicion and early recognition of this rare syndrome.

Funding: No funding sources

Conflict of interest: None declared

Ethical approval: Not required

REFERENCES

1. Kounis NG, Zavras GM. Histamine-induced coronary artery spasm: The concept of allergic angina. *Br J Clin Pract.* 1991;45:121-8.
2. Kounis NG. Kounis syndrome (allergic angina and allergic myocardial infarction): a natural paradigm? *Int J Cardiol.* 2006;1.
3. Nittner-Marszalska M. Non-ST elevation myocardial infarction after multiple bee stings. A case of "delayed" Kounis syndrome? *Int J Cardiol.* 2013;10
4. Brawnvald E. Unstable angina. An etiologic approach to management. *Circulation.* 1998;98:2219-22.
5. Kounis NG. Kounis syndrome (allergic angina and allergic myocardial infarction): A natural paradigm? *Int J Cardiology.* 2006;110:7-14.
6. Kounis GN, Soufras GD, Kouni SA, Kounis NG. Hypersensitivity myocarditis and hypersensitivity coronary syndrome (Kounis syndrome) *Am J Emerg Med.* 2009;27:506-8.

Cite this article as: Megha S, Agarwal G. A case report of Kounis syndrome: acute myocardial injury caused by multiple bee stings. *Int J Res Med Sci* 2023;11:714-5.