

## Original Research Article

# Protective effects of pomiferin isolated from *Maclura pomifera* on ischemia-reperfusion injury of rat ovary: biochemical and histopathologic evaluation

Osman Nuri Keleş<sup>1</sup>, Hüseyin Serkan Erol<sup>2</sup>, Dilek Vural Keleş<sup>3</sup>, Mehmet Karaca<sup>4</sup>, Ahmet Çakır<sup>5</sup>, Murat Koç<sup>6</sup>, Jale Selli<sup>7\*</sup>, Mesut Bünyami Halıcı<sup>8</sup>

<sup>1</sup>Department of Medical Histology and Embryology, Ataturk University Medical Faculty, Erzurum, Turkey

<sup>2</sup>Department of Biochemistry, Kastamonu University Veterinary Faculty, Kastamonu, Turkey

<sup>3</sup>Department of Nursing, Kırklareli University Health Sciences Faculty, Kırklareli, Turkey

<sup>4</sup>Obstetrics and Gynecology Clinics, Antalya Medical Park Hospital, Antalya, Turkey

<sup>5</sup>Department of Chemistry, Kilis 7 Aralık University Science Faculty, Kilis, Turkey

<sup>6</sup>Department of Traditional, Complementary and Integrative Medicine, Ankara Yıldırım Beyazıt University Public Health Graduate School, Ankara, Turkey

<sup>7</sup>Department of Medical Histology and Embryology, Alanya Alaaddin Keykubat University Medical Faculty, Antalya, Turkey

<sup>8</sup>Department of Biochemistry, Ataturk University Veterinary Faculty, Erzurum, Turkey

**Received:** 18 December 2022

**Accepted:** 03 January 2023

### \*Correspondence:

Dr. Jale Selli,

E-mail: [jale.selli@alanya.edu.tr](mailto:jale.selli@alanya.edu.tr)

**Copyright:** © the author(s), publisher and licensee Medip Academy. This is an open-access article distributed under the terms of the Creative Commons Attribution Non-Commercial License, which permits unrestricted non-commercial use, distribution, and reproduction in any medium, provided the original work is properly cited.

## ABSTRACT

**Background:** The aim of this study was to investigate the antioxidant and anti-inflammatory properties of pomiferin, a prenylated flavonoid was purified from *Maclura pomifera* by thin layer chromatography method, on oxidative stress, sterile inflammation and ovarian tissue damage caused by ischemia-reperfusion model.

**Methods:** Thirty female Wistar albino rats were divided into five groups. In the group CN only laparotomy operation was performed. In group CN<sup>Pomiferin</sup>, rats received 200 mg/kg pomiferin. In group IR<sup>Vehicle</sup>, reperfusion for 3 h performed after an ischemic period of 3 hours. In groups IR<sup>Pomiferin100</sup> and IR<sup>Pomiferin200</sup> rats received 100 mg/kg and 200 mg/kg doses of pomiferin, by oral gavage 1 hours before reperfusion. After the experiments, tissue level of malondialdehyde (MDA) and activities of myeloperoxidase (MPO), catalase (CAT), superoxide dismutase (SOD) were determined, and histopathological changes were examined in all rat ovarian tissue.

**Results:** It was determined that irreversible cell damage such as apoptotic and necrotic deaths and reversible cell damage occurred in follicular, endothelial and stromal cells due to oxidative stress in the group IR<sup>Vehicle</sup>. In this group, it was determined that the LPO level exceeded the cellular antioxidant capacity (SOD and CAT enzyme activities) and the PMNL infiltration and activity (MPO), an indicator of sterile inflammation, increased. It was determined that oxidative stress sterile inflammation and irreversible cell damage decreased in a dose-dependent manner with pomiferin treatment.

**Conclusions:** Pomiferin treatment strongly protects ovarian follicles and vascular structures against ischemia-reperfusion injury, thus it may prevent the reduction of ovarian follicle reserve, which is an indicator of female fertility.

**Keywords:** Ischemia/reperfusion injury, Oxidative stress, Pomiferin, Sterile inflammation

## INTRODUCTION

Ovarian torsion is a serious gynecologic condition that occurred infarction after ovarian ischemia and is characterized by the occlusion of venous and lymphatic drainage and deterioration of the arterial supply a result of the twisting of the ovary and portion of the fallopian tube on the supplying vascular pedicle.<sup>1,2</sup> It is reported to be the fifth common gynecologic emergency condition, occurring more common in women under 30 years of age and mimicking signs and symptoms of acute appendicitis and terminated by oophorectomy an ischemic process that evolves over time till necrosis if it is not diagnosed in the early stages.<sup>3</sup> If the ovarian torsion (also known as adnexal torsion) is early diagnosed, it can be surgically detorsed and blood flow is restored again. The main purpose of ovarian detorsion is to restore perfusion of tissue together with the correction of bloodstream. After ischemia caused by torsion, ensuring recirculation cause pathophysiological process known as "reperfusion injury".<sup>4</sup> Therefore, reduction or cessation of reperfusion injury increases the success and efficiency of treatment.<sup>5</sup> Ischemia/reperfusion (I/R) injury is associated with several factors including activation of macrophages, production of pro-inflammatory cytokines and free radicals. After the ischemic event, the byproducts of monovalent oxygen metabolism or formation of the free radicals generate deterioration in lipid, carbohydrate, protein and nucleic acid in cells and thus cause damage to tissue.<sup>6</sup> When reperfusion exposed to tissue after ischemic injury, pro-inflammatory cytokines such as IL-1 $\beta$ , IL-6, TNF- $\alpha$  and chemokines produced by inflammatory cells trigger the adhesion of neutrophils to endothelial cells and migration from circulation into tissue. The neutrophils activated by forming inflammatory response are a potential source for reactive oxygen species (ROS) and inflammatory products may cause more oxidative damage.<sup>7</sup> I/R injury in the organs such as heart, intestines, brain, kidney and ovary leads to cellular degeneration and loss of function associated with excess production of ROS and inflammatory products.<sup>8</sup> Therefore, in I/R injuries, some anti-inflammatory and antioxidants are used to prevent tissue damage.<sup>9</sup>

Pomiferin (PMF) is a prenylated isoflavone obtained from ethyl acetate extract of fruits of the *Maclura pomifera*, a member of the *Moraceae* family. *Moraceae* species possess a variety of significant effects such as anticancer, antidiabetic, antiviral, antifungal, anti-allergic, antioxidant and anti-inflammatory.<sup>10,11</sup> Pomiferin possesses high ability to scavenge superoxide radicals, hydrogen peroxide, and hypochlorous acid in cell-free models.<sup>12</sup> Also, PMF has a strong antioxidant activity against the superoxide anion in a photo chemiluminescence (PCL) assay system.<sup>13</sup> It has many antioxidative effects including inhibition of lipid peroxidation and tyrosine nitration, scavenging of  $\alpha$ ,  $\alpha$ -diphenyl- $\beta$ -picrylhydrazyl (DPPH) and high ethoxyresorufin-O-deethylase (EROD) activity.<sup>14</sup> In addition PMF is highly potent antioxidant in ferric

reducing antioxidant power (FRAP) and  $\beta$ -carotene-linoleic acid model system ( $\beta$ -CLAMS) systems, comparable to the antioxidant vitamins C and E and the synthetic antioxidant butylated hydroxytoluene (BHT).<sup>15</sup> PMF markedly decreased oxidative damage of the four bases (guanine, thymine, adenine and cytosine) in DNA which exposed to oxygen radicals due to Fenton's reaction.<sup>16</sup> In line with the results from the cell free methods, strong evidence of the antioxidant activities of pomiferin were observed in alloxan-induced diabetes mellitus and I/R models of heart and kidney in in-vivo (animal) studies.<sup>17,18</sup> Pomiferin possesses down-regulation of I $\kappa$ B- $\alpha$  degradation mediated anti-inflammatory effects in macrophage cell cultures and increases activity of nonsteroidal anti-inflammatory drug-activated gene (NAG-1) and macrophage inhibitory cytokine -1 (MIC-1) which suppresses macrophages induced inflammation.<sup>12,19</sup>

Consequently, in present study we aimed to investigate the ovarian-protective, anti-inflammatory and antioxidant effect of pomiferin in I/R induced ovarian damage and oxidative stress in rats.

## METHODS

### *Plant material, extraction and isolation procedures*

All chemicals exerted for present investigation were purchased from Sigma-Aldrich (Germany). Nuclear magnetic resonance (NMR) spectra registered by 400 MHz varian mercury spectrometer, operating at 400 MHz and 100 MHz for <sup>1</sup>H-NMR and <sup>13</sup>C-NMR. Furthermore, the infrared spectrum (FTIR) was detected on fourier transform infrared spectrophotometer (Perkin Elmer model 1600). The fruits (about 10-15 pieces) of *M. pomifera* tree were gathered from in October, which grows at a park in Kilis/Turkey, by Murat KOC and a voucher sample (M. Koç 1292) stored in the herbarium of Department of Biology, Bozok University, Yozgat (Turkey). After chopping into small pieces, fresh fruits of *M. pomifera* dried in an oven at 60 °C, dried fruits were extracted with ethyl acetate (5 $\times$ 2.5 L). Organic solvent was evaporated using a rotary evaporator under reduced pressure and temperature and then yellow-greenish viscous extract were obtained. The extract was subjected to silica gel (70-230 mesh) column chromatography (CC) over chloroform-ethyl acetate (8:2) mobile phase. The fractions (50 ml) were checked via thin layer chromatography (TLC) with chloroform-ethyl acetate (8:2) and the fractions containing a pure compound were combined. The chemical structure of this compound was characterized as pomiferin (PMF) by spectroscopic methods in the UV-VIS, IR, <sup>1</sup>H-NMR, <sup>13</sup>C-NMR, 1D and 2D NMR.

### *Animals and experimental design*

The present study was carried out according to national and international guidelines for the use of experimental

animals. The protocols of experiments were reviewed and approved by the local and governmental committees for animal care and use (ATADEM-Approval No: 36643897). The 30 sexually mature female rats in the estrous phase (Ataturk university experimental laboratories, Wistar albino, body weight 210-230 gm) were used in this study.

Intraperitoneal injection of sodium thiopental (25 mg, per kilogram of body weight) used for anesthesia of rats, before surgical procedures. A small longitudinal incision (no longer than 2.5 cm) that included the skin, muscle and peritoneum was performed in the midline area of the lower abdomen and the left and right ovaries were exposed. The abdominal wall was kept open for 1 min and then closed with 3/0 silk sutures in CN group (sham-operated control group; n=6). Sham operation was applied in the CN<sup>Pomiferin</sup> group (n=6), 1 h after administration of 200 mg/kg pomiferin by oral gavage.

For the IR<sup>Vehicle</sup> group (n=6), bilateral adnexal torsion model (3-hour ischemia) was performed by using vascular clips just below the both left and right ovary and then detorsion (3-hour reperfusion) was performed after a 3-hour torsion period. This group was applied 1 ml/kg of saline solution by oral gavage 2 hours after torsion. The IR<sup>Pomiferin100</sup> (n=6) and IR<sup>Pomiferin200</sup> (n=6) groups received 100 mg/kg and 200 mg/kg doses of pomiferin, by oral gavage, respectively, 1 hours before the detorsion. Pomiferin was dissolved in 1 ml volume hot saline solution. 3 hours after reperfusion, ovaries were removed for investigation and measure both histopathological changes and biochemical parameters.

#### ***Tissue sample preparation and homogenization***

For blind biochemical studies ovarian tissue samples were labeled as group 1, 2, 3 and 4 etc, placed in liquid nitrogen promptly and afterwards carried to the laboratory for measurement of lipid peroxidation levels and antioxidant and inflammatory enzyme activities.

Ovarian tissues were grinded with liquid nitrogen in a mortar and then homogenated using a tissue homogeniser (QIAGEN TissueLyser LT, USA) at 35 Hz (15 min at 4°C). The homogenates were centrifuged at 1000 gm for 10 min and supernatants were saved.

#### ***Assays for tissue lipid peroxidation and antioxidant enzymes***

Ovarian lipid peroxidation levels were measured spectrophotometrically by the method explained in previous studies which follows changes in malonaldehyde precursors in tissue through use of the thiobarbituric acid (TBA) test.<sup>20</sup> Tissues were weighed as 15 mg in a sterile tube and homogenized in cold 1.5 mL of 100 g/L KCl. The homogenates were centrifuged 10000 g for an hour. To 0.25 ml of tissue homogenate, 0.3 mL of distilled water, 0.2 mL of 80 g/L sodium lauryl

sulfate, 1.5 mL of 8 g/L TBA aqueous solution and 1.5 mL of 200 g/L acetic acid was added, stirred and heated in a boiling water bath for 45 min. After cooling, 4 ml of n-butanol was added. The butanol layer was separated by centrifugation and the absorbance of the butanol layer was measured spectrophotometrically at 532 using a spectrophotometer (Bio-Tek, USA). 1,1,3,3-tetramethoxypropane was used as the primary standard. Results were expressed as nanomol MDA per gram of tissue (nmol/g tissue).

Ovarian endogenous antioxidant status were assessed by measurement of superoxide dismutase (SOD) according to Sun et al and catalase (CAT) according to Aebi.<sup>21,22</sup> In measurement of SOD activity, superoxide radicals generated from the conversion of xanthine to uric acid and hydrogen peroxide by xanthine oxidase (XOD) converts the nitro blue tetrazolium (NBT) to formazan dye. SOD activity was measured by the amount of enzyme-reducing NBT. SOD activity was expressed as millimoles per minute per milligram. In measurement of CAT activity, it catalysis the decomposition of hydrogen peroxide (H<sub>2</sub>O<sub>2</sub>) to water and oxygen and was measured in a quartz cuvette at 240 nm. CAT activity was described as the amount of catalase required to decompose 1 nanomole of H<sub>2</sub>O<sub>2</sub> per minute at 25 °C and pH 7.0. CAT activity was expressed as mmol/min/mg.

#### ***Assay of MPO enzyme for polymorphonuclear leukocyte response***

MPO activity was determined according to the modified method of Bradley et al.<sup>23</sup> The homogenized tissues mixture (15 mg tissue in 1.5 mL buffer) was centrifuged for 10 min at 4°C. By first mixing 0.1 mL supernatant with 1.9 mL of 10 mmol/L phosphate buffer (pH 6.0) MPO reaction was carried out. After adding 1 mL of 1.5 mmol/L o-dianisidine hydrochloride containing 0.0005% (wt/vol) hydrogen peroxide, MPO absorbance activity were measured at 460 nm every 30 sec during 3 min. MPO activity is expressed as the change in unit per mg of tissue.

#### ***Histopathological examination***

For histopathological assessment ovaries were immediately fixed in 10% buffered formalin for 24 to 48 hours. Then tissues were dehydrated in a graded alcohol series, cleared with xylene and then embedded in paraffin wax. 5-mm-thick sections were cut from paraffin-embedded tissue samples with a Leica RM2125RT microtome. Sections were stained with hematoxylin and eosin by the end of deparaffinization and rehydration. A light photomicroscope used for evaluation and photomicrography of all sections.

#### ***Data analyses***

Descriptive statistical data were expressed as means ± S.E.M. and SPSS (Statistical package for social science)

version 20.0 for Windows (SPSS Inc, Chicago, IL) used for statistical analysis. The one-way analysis of variance (ANOVA) test was used to compare the significance of differences among different groups. Duncan's multiple range test was used to differentiate between means (to determine differences between means of treatments at significance rates of 0.05).  $P < 0.05$  was considered as statistically significant.

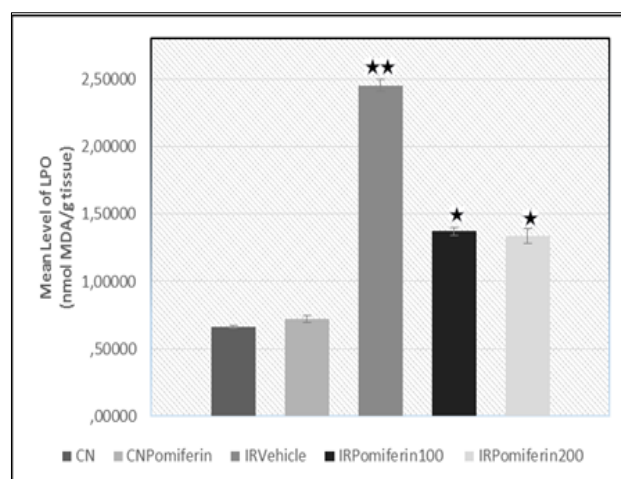
## RESULTS

### Biochemical results

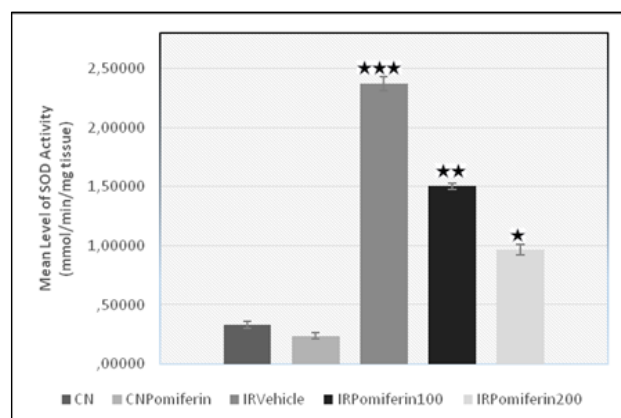
Compared results on ovarian tissue homogenate lipid peroxidation and antioxidant parameters during I/R injury and pomiferin applied groups are shown in Figure 1, 2 and 3. As Figure 1 shows, LPO values at the physiological level were determined in the ovaries of CN<sup>Pomiferin</sup> and CN groups, and statistical difference was no in LPO levels between them. A marked increase in ovarian LPO (270.82%) levels in IR<sup>Vehicle</sup> group was observed in comparison to the CN group. Also, compared to the CN group, activities of ovarian SOD and CAT enzymes were significantly increased (617.04% and 87.69%, respectively) in IR<sup>Vehicle</sup> group (Figure 2 and 3.). As Figure 1 shows, pomiferin treatment considerably decreased LPO levels that had been raised in ovary by ischemia-reperfusion, both at the low dose (44.15%) and the high dose (45.55%) (Figure 1). Ovarian SOD activity were declined in a dose-dependent manner in the IR<sup>Pomiferin100</sup> (36.59%) and IR<sup>Pomiferin200</sup> (59.29%) groups compared to the IR<sup>Vehicle</sup> group (Figure 2). On the other hand, as Figure 3 shows, PMF treatment had biphasic effect on ovarian CAT activity. Ovarian CAT activity were decreased in the IR<sup>Pomiferin100</sup> (33.12%), while were increased in the IR<sup>Pomiferin200</sup> (16.64%) group compared to the IR<sup>Vehicle</sup> group.

Increased tissue levels of MPO, an enzyme secreted by activated neutrophils and macrophages, are a hallmark of inflammatory diseases such as sepsis, and ischemia and reperfusion and Figure 4 shows the MPO enzyme activities in ovarian tissues for all treatments, ischemia-reperfusion and control groups. As Figure 4 shows, ovaries in the CN<sup>Pomiferin</sup> and CN groups possess MPO activity at the physiological level, and statistical difference were no in levels of MPO activity between them ( $P > 0.05$ ). Ovarian tissue of the CN<sup>Pomiferin</sup> and CN groups MPO activity was detected at the physiological level as shown Figure 4, and there was no statistically significant statistical difference in levels of MPO activity between them ( $p > 0.05$ ).

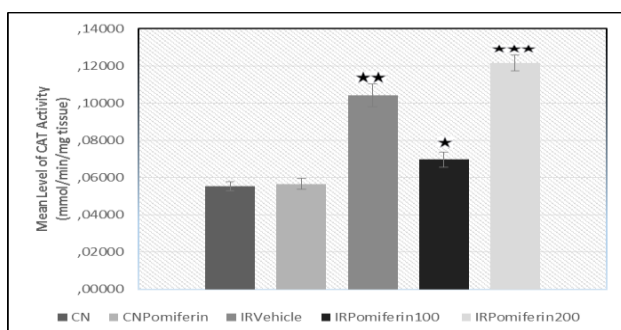
IR<sup>Vehicle</sup> ovaries showed an important enhancement in MPO activity (634.58%) compared to the CN group. PMF treatments decreased high ischemia-reperfusion-induced MPO activity in a dose-dependent manner in the IR<sup>Pomiferin100</sup> (37.91%) and IR<sup>Pomiferin200</sup> (56.74%) groups compared to the IR<sup>Vehicle</sup> group.



**Figure 1: The mean level of lipid peroxidation (LPO) in control and different treated groups. Data are expressed as means  $\pm$  s.e.m. (n=6 per group). Values having different superscripts within same row are significantly different ( $p < 0.05$ ).**

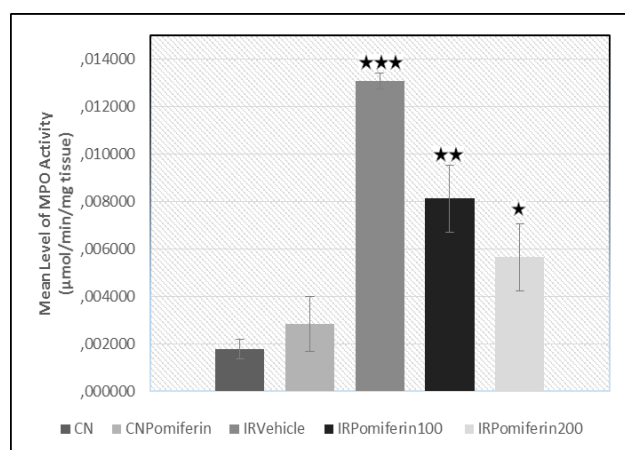


**Figure 2: The mean level of SOD activity in control and different treated groups. Data are expressed as means  $\pm$  s.e.m. (n=6 per group). Values having different superscripts within same row are significantly different ( $p < 0.05$ ).**



**Figure 3: The mean level of CAT activity in control and different treated groups. Data are expressed as means  $\pm$  s.e.m. (n=6 per group). Values having different superscripts within same row are significantly different ( $p < 0.05$ ).**



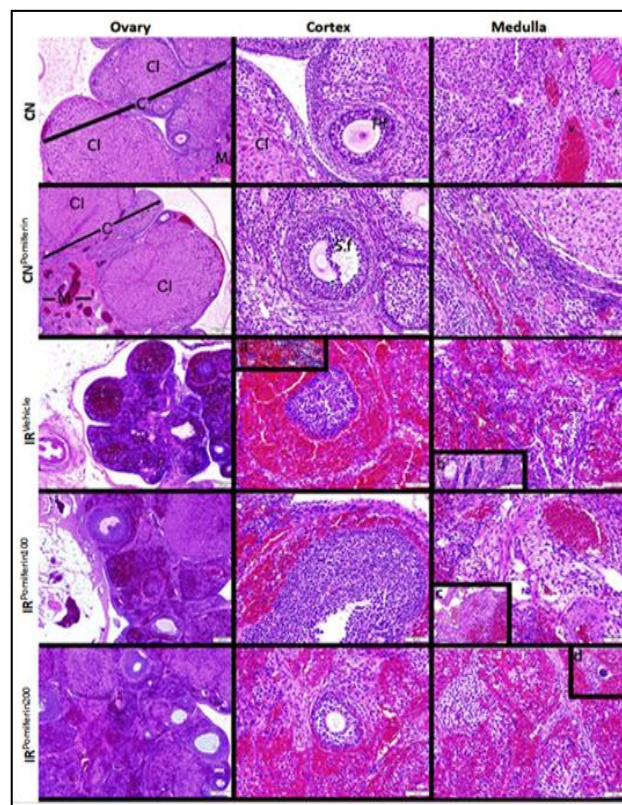


**Figure 4: The mean level of MPO activity in control and different treated groups. Data are expressed as means  $\pm$  s.e.m. (n=6 per group). Values having different superscripts within same row are significantly different ( $p < 0.05$ ).**

### Histopathological investigations

Normal histological structure, as well as was tunica albuginea containing cortex, ovarian follicles, medulla including blood vessels and the loose connective tissue, detected in the ovarian tissues of the CN and CN<sup>Pomiferin</sup> groups (Figure 5). Primordial, primary and secondary follicle structures, the structure of atretic follicle and corpus luteum and connective tissue structures were normal. As Figure 5 shows, mild congestions in veins were observed in CN<sup>Pomiferin</sup> group in addition to normal histological structures as it is the case in the control group. IR<sup>Vehicle</sup> group showed common hemorrhagic areas in cortex and medulla. Hemorrhagic areas were observed between the corpus luteum and atretic follicles, primary and secondary follicles. Increased polymorphonuclear leukocytes infiltration (PMNL) towards the connective tissue, destruction of arteries and veins, giant epithelioid bodies were indicated in IR<sup>Vehicle</sup> group (Figure 5). On the other hand, follicle cells in IR<sup>Vehicle</sup> group ovarian tissues were more basophilic and displayed more necrotic changes, apoptotic death in both parenchymal and stromal cells were shown (Figure 5). In examination of IR<sup>Pomiferin100</sup> group hemorrhagic areas, apoptotic and necrotic changes, PMNL and MNL infiltration decreased, hyalinisation and interstitial edema levels were lower compared to IR<sup>Vehicle</sup> group and even lower compared to other groups. IR<sup>Vehicle</sup> group demonstrated the thickening of the vessel walls, particularly in artery walls, also mesenchymal-like cells were noticed in the connective tissues of this group and it was the most interesting finding. Furthermore, there was an increase in the production of amorphous intermediate matter in the connective tissue (Figure 5). Histopathological evaluation of IR<sup>Pomiferin200</sup> group revealed that ovarian tissue structures were more similar one to CN and CN<sup>Pomiferin</sup> groups among others. Hemorrhagic areas decreased, PMNL and MNL infiltrations were significantly reduced compared to other experimental groups and the

degeneration was very low in arterial and venous structures. As Figure 5 shows, parenchymal and stromal components, oocytes, follicular and corpus luteum structures were preserved in IR<sup>Pomiferin200</sup> group. In addition, giant epithelioid bodies were rarely and apoptotic cell death was not observed in examination of IR<sup>Pomiferin200</sup> group ovarian tissues (Figure 5).



**Figure 5: Histologic micrographs of ovaries in all groups. Haematoxylin and eosin (H and E) staining. C: Cortex, M: Medulla, Cl: Corpus Luteum, Pf: Primary follicle, Sf: Secondary follicle, A: Artery, V: Vein.**

### DISCUSSION

I/R injury is a pathophysiological process which is associated with restoration of blood flow and re-oxygenation following the hypoxic organ damage. Reestablishment of the oxygen flow and other components lead to oxidative stress, sterile inflammation and deterioration of vascular structure and flow rather than the restoration of the normal functions.<sup>24</sup> ROS attack on double bonds of lipids and proteins and double bonds of DNA bases during the oxidative stress initiates the damage in main structural components of the cell through chain oxidation reactions by breaking one hydrogen atom.<sup>7,25</sup> In this process, cellular function loss or apoptotic and necrotic cell deaths occur as a result of the damage in main structural components.<sup>26</sup> Oxidative damage can be detected through measurements of products such as MDA and 4-hydroxynonenal which are produced as a result of the lipid peroxidation in the

membrane systems due to ROS.<sup>27</sup> In the present study, we examined the ovarian MDA levels as an indicator of the oxidative damage to lipids, which is the main component of the the cell membrane systems, and activities of the SOD, and CAT enzymes, important endogenous antioxidants playing roles in the protection mechanism against oxidative damage, in ovarian tissue.

Three hours of reperfusion following the three hours of ischemia processes increased the LPO levels (270.82%) compared to CN group. Furthermore, we observed that there was a marked increase in the ovarian SOD and CAT enzyme activities in IR<sup>Vehicle</sup> group (617.04% and 87.69%, respectively). The increase in the levels of LPO in the IR<sup>Vehicle</sup> group can be due to various sources during the hypoxia or after the hypoxia. Impaired mitochondrial membrane integrity, increased purine metabolites, xanthine, hypoxanthine, and xanthine oxidase activities, increased damage-associated molecular patterns (DAMPs) during the hypoxia can lead to increase in ROS derivatives.<sup>28</sup> Firstly, elevated oxidative phosphorylation to meet the increased ATP requirements during the tissue regeneration, decreased functions of the mitochondrial antioxidant system and raised membrane permeability boosts transport of the superoxide from mitochondrium to the cytoplasm, and so this situation causes an increase in the LPO levels during reperfusion period after the hypoxia.<sup>29</sup> Secondly, xanthine oxidase increases during the hypoxia and it uses the oxygen which is obtained as a result of the reperfusion. It primarily converts the hypoxanthine to xanthine and then to uric acid. Superoxide radical, which is one of the reactive oxygen species, is formed in the last two steps, and it is another intercellular factor in the increase of intracellular oxidative stress.<sup>30</sup> Thirdly, another reason that is responsible for the LPO increase in the I/R damage is the neutrophil recruitment during the post ischemic sterile inflammatory response. Sterile inflammation in the tissues during the ischemia-reperfusion process, pro-inflammatory mediators that are released by endothelial cells, macrophages, mast cells and other cells lead to migration and adhesion of PMNL.<sup>31</sup> They produce oxidant mediators through the mechanism named respiratory burst. Superoxides, which are produced in phagocytic cells by the increasing influence of the NADPH oxidases (NOX) enzyme in the respiratory burst, are primarily converted to hydrogen peroxide by SOD enzyme, then either to hypochlorous acid by the MPO or to hydroxyl radical by Fenton reaction. They are released upon these conversions. This process is the main factor depending on the extracellular source which leads to LPO increase. For this purpose, in the present study LPO levels investigated as a criterion of oxidative tissue damage and data indicate that I/R significantly increased LPO levels. Furthermore, the increase of the MPO activity and PMNL migrations towards tissues are in line with these findings of the reperfusion group.

Under physiological conditions, superoxide radical ( $O_2^{\cdot-}$ ) is primarily converted to hydrogen peroxide by SOD and

then to water by catalase enzyme. However, increased amounts of  $O_2^{\cdot-}$  and  $H_2O_2$  during the I/R process exceed the buffering capacity of antioxidants and they cannot be removed efficiently.<sup>32</sup>  $H_2O_2$  reacts with transition metals such as  $Fe^{+2}$  or superoxide radicals and forms the most strong radical named hydroxyl radical ( $OH^{\cdot}$ ). The increase of the hydroxyl radical leads to oxidative degradation of lipids located in the cellular membranes. Even though there was an increase in SOD and CAT activities in the reperfusion group, LPO levels were not reduced. In other terms, produced ROS exceeded the buffering capacity of antioxidants and cells were in the oxidative stress. Furthermore, the increase in the vascular permeability, apoptosis and necrosis in endothelial and parenchymal follicular cells show that oxidative stress leads to loss of function and death in tissues. Many studies reported that oxidative stress and excessive ROS products as a result of I/R injuries may cause either reversible or irreversible cell damage such as apoptosis and necrosis.<sup>33,34</sup> Histopathological evaluation of ovarian tissue in the I/R group revealed reversible cell damage and degenerative changes in parenchymal cells as well as stromal components of tissue. Furthermore, apoptotic death and vacuolization were prominent mainly in follicular cells. Also, severe hemorrhage due to destruction of blood vessels and capillaries accompanied intensive infiltration of polymorphonuclear leukocytes in the stroma. Previous studies indicate that reversible damage and irreversible cell damage such as apoptosis and necrosis can develop due to oxidative stress and excess production of inflammatory markers during I/R injuries.<sup>17,35</sup> Progressive loss and damage of follicles in ovaries is associated with female fertility.<sup>36</sup> Effects of ischemia-reperfusion injury on ovarian reserve have been investigated by Ozler et al with a rat model and authors reported a significant decrease in ovarian reserve.<sup>37</sup>

In this study, endothelial dysfunction, follicular cell death (apoptosis and necrosis), PMNL infiltrations and LPO levels were significantly reduced by pomiferin treatment. LPO levels were decreased by pomiferin in ovarian tissues (100 mg/kg dose (44.15%) and the 200 mg/kg dose (45.55%)). Similar to our study, various studies found that pomiferin treatment reduced the increased LPO levels in kidney, heart, blood due to ischemia reperfusion injury and diabetes in animal models.<sup>14,15</sup> IR<sup>Pomiferin100</sup> (36.59%) and IR<sup>Pomiferin200</sup> (59.29%) groups showed reduced amounts of ovarian SOD activity in a dose dependent manner compared to IR<sup>Vehicle</sup> group. In metabolic processes, increased activity of an enzyme can be associated with the increased substrate production. Reduced superoxide radical or the levels of substrates correlates with the reduced SOD enzyme activity in treatment groups. Pomiferin leads to scavenging of superoxide radicals in cell-free models and in a photochemiluminescence (PCL) assay system.<sup>12,15</sup> Decreased SOD activity can be explained by the strong scavenging activity of pomiferin and the decreased amount of superoxide. Furthermore, decreased ovarian CAT activity was observed in the IR<sup>Pomiferin100</sup> (33, 12%)

group whereas increased ovarian CAT activity was observed in the IR<sup>Pomiferin200</sup> (16, 64%) group compared to the IR<sup>Vehicle</sup> group. Decreased CAT activity in response to the low doses of pomiferin treatment can be explained by the reduction of the H<sub>2</sub>O<sub>2</sub> amount, which is a substrate of catalase, due to the decreased SOD activity. However, catalase activity shows that higher dose of pomiferin has an increasing effect on the CAT activity but this effect is limited. On the other hand, density of hemorrhagic areas, PMNL infiltration, apoptotic cell death was significantly reduced in both IR<sup>Pomiferin100</sup> and IR<sup>Pomiferin200</sup> groups compared to the I/R group in a dose dependent manner. Results of histological examination demonstrated a marked improvement in ovarian morphology in IR<sup>Pomiferin100</sup> and IR<sup>Pomiferin200</sup> groups compared with the ischemia and ischemia-reperfusion groups. Ovarian parenchymal and stromal components in the IR<sup>Pomiferin200</sup> group exhibit normal histological features similar to those in the CN group.

In this study, we found that the ovaries treated with pomiferin display lower MPO levels and neutrophil infiltration indicating anti-inflammatory response of pomiferin. It was previously shown that pomiferin treatment inhibits I $\kappa$ B- $\alpha$  degradation in macrophage cells leading to anti-inflammatory response.<sup>12</sup> Various pro-inflammatory cytokines such as TNF- $\alpha$ , IL-1 $\beta$ , IL-6 and IL-8 are expressed with the help of the essential transcription factor named NF- $\kappa$ B (p65) in macrophages. The translocation of NF- $\kappa$ B from cytoplasm to cell nucleus is prevented by I $\kappa$ B $\alpha$  by binding to nuclear localization signals of NF- $\kappa$ B. Upon stimulation I $\kappa$ B- $\alpha$  is degraded and NF- $\kappa$ B translocates from the cytoplasm to the nucleus promoting pro-inflammatory cytokine expression. In this study, the mitigating effects of PMF was indicated on neutrophil activity and recruitment. Biochemical and histopathological findings are associated with less amount of pro-inflammatory cytokine release from macrophages due to the inhibitory effect of pomiferin on I $\kappa$ B  $\alpha$  degradation. Reduced LPO levels may be associated with the diminished neutrophil-derived ROS which is triggered by the anti-inflammatory effect of pomiferin.

Previous studies reported that degeneration of follicles and reduction in the number of primordial follicles play a key role in ovarian reserve as an indicator of reproductive longevity.<sup>38</sup> Ovarian tissue injury, consequently to oxidative damage during ischemia-reperfusion, affects ovarian reserve due to follicular cell apoptosis.<sup>39</sup> Recently many studies focused on antioxidant and anti-inflammatory agents to preserve the ovarian reserve by reducing follicular apoptotic cell death in the reperfusion damage.<sup>40</sup> Pomiferin could provide protection of the follicle pool against ovarian I/R injury by blockage of apoptotic pathways with its antioxidant and anti-inflammatory effects.

## CONCLUSION

In this study, it is the first time that early PMF treatment improves the ovarian tissue injury because of I/R. It can be concluded that PMF may be used in women for the permanent ovarian injury which can happen due to torsion-detorsion.

*Funding: No funding sources*

*Conflict of interest: None declared*

*Ethical approval: The study was approved by the Institutional Ethics Committee by Ataturk University Animal Ethical Committee (ATADEM-Approval No: 36643897).*

## REFERENCES

1. Jain KA. Magnetic resonance imaging findings in ovarian torsion. *Magnetic Resonance Imaging*. 1995;13;1:111-3.
2. Olesen HO, Pors SE, Jensen LB. N-acetylcysteine protects ovarian follicles from ischemia-reperfusion injury in xenotransplanted human ovarian tissue. *Human Reproduction*. 2021;36;2:429-43.
3. Petkovska I, Martin DR, Covington MF. Accuracy of Unenhanced MR Imaging in the Detection of Acute Appendicitis: Single-Institution Clinical Performance Review. *Radiology*. 2016;279;2:451-60.
4. Halici Z, Karaca M, Keleş ON, et al. Protective effects of amlodipine on ischemia-reperfusion injury of rat ovary: biochemical and histopathologic evaluation. *Fertil Steril*. 2008;90;6:2408-15.
5. Cadirci E, Oral A, Odabasoglu F. Atorvastatin reduces tissue damage in rat ovaries subjected to torsion and detorsion: biochemical and histopathologic evaluation. *Naunyn-Schmiedeberg's Arch Pharmacol*. 2010;381;5:455-66.
6. Sung CC, Hsu YC, Chen CC, Lin YF, Wu CC. Oxidative stress and nucleic acid oxidation in patients with chronic kidney disease. *Oxidative Med Cellular Longevity*. 2013;2013;301982.
7. Keleş DV, Uslu H, Keleş ON, Unal B, ALP HH. Investigation of The Protective Effects of Beta-D-Glucan Against Invasive Encapsulated *Streptococcus pneumoniae* Sepsis in Splenectomized Rats. *Mikrobiyol Bul*. 2015;49;3:314-26.
8. Minutoli L, Puzzolo D, Rinaldi M. ROS-Mediated NLRP3 Inflammasome Activation in Brain, Heart, Kidney, and Testis Ischemia/Reperfusion Injury. *Oxidative Med Cellular Longevity*. 2016;2016;2183026.
9. Campolo M, Impellizzeri D, Bruschetta G, Casili G, Esposito E, Cuzzocrea S. Bergamot Juice Extract Exerts A Notable Anti-Inflammatory And Anti-Oxidant Effect In A Murine Model Of Intestinal Ischemia/Reperfusion. *Lippincott Williams and Wilkins two commerce sq, 2001 market st, Philadelphia*. 2015:9-9.

10. Ribaud G, Pagano MA, Pavan V. Semi-synthetic derivatives of natural isoflavones from *Maclura pomifera* as a novel class of PDE-5A inhibitors. *Fitoterapia*. 2015;105:132-8.
11. Cigsar G, Keles O, Can S. The protective effects of osajin on ischemia/reperfusion injury to rat ovaries: biochemical and histopathological evaluation. *Kafkas Universitesi Veteriner Fakultesi Dergisi* 2015;21;5:
12. Hosek J, Toniolo A, Neuwirth O, Bolego C. Prenylated and geranylated flavonoids increase production of reactive oxygen species in mouse macrophages but inhibit the inflammatory response. *J Natural Products*. 2013;76;9:1586-91.
13. Yang R, Hanwell H, Zhang J, Tsao R, Meckling KA. Antiproliferative activity of pomiferin in normal (MCF-10A) and transformed (MCF-7) breast epithelial cells. *J Agri Food Chem*. 2011;59;24:13328-36.
14. Vesela D, Kubinova R, Muselik J, Zemlicka M, Suchy V. Antioxidative and EROD activities of osajin and pomiferin. *Fitoterapia*. 2004;75;2:209-11.
15. Tsao R, Yang R, Young JC. Antioxidant isoflavones in Osage orange, *Maclura pomifera* (Raf.) Schneid. *J Agri Food Chem*. 2003;51;22:6445-51.
16. Diopan V, Babula P, Shestivska V. Electrochemical and spectrometric study of antioxidant activity of pomiferin, isopomiferin, osajin and catalposide. *J Pharmaceutical Biomed Analysis*. 2008;48;1:127-33.
17. Bartosikova L, Necas J, Bartosik T, Pavlik M, Frana P. Effect of pomiferin administration on kidney ischaemia-reperfusion injury in rats. *Interdisciplinary Toxicol*. 2010;3;2:76-81.
18. Florian T, Necas J, Bartosikova L. Effects of prenylated isoflavones osajin and pomiferin in premedication on heart ischemia-reperfusion. *Biomedical papers of the Medical Faculty of the University Palacky, Olomouc, Czechoslovakia*. 2006;150;1:93-100.
19. Abourashed EA, Abraha A, Khan SI, McCants T, Awan S. Potential of Horse Apple Isoflavones in Targeting Inflammation and Tau Protein Fibrillization. *Natural Product Commun*. 2015;10;9:1577-80.
20. Ohkawa H, Ohishi N, Yagi K. Assay for lipid peroxides in animal tissues by thiobarbituric acid reaction. *Analytical biochem*. 1979;95;2:351-8.
21. Sun Y, Oberley LW, Li Y. A simple method for clinical assay of superoxide dismutase. *Clinical chemistry* 1988;34;3:497-500.
22. Aebi H. Catalase in vitro. *Methods in enzymology*. Elsevier. 1984:121-6.
23. Bradley PP, Priebe DA, Christensen RD, Rothstein G. Measurement of cutaneous inflammation: estimation of neutrophil content with an enzyme marker. *J Investigative Dermatol*. 1982;78;3:206-9.
24. Eltzschig HK, Eckle T. Ischemia and reperfusion--from mechanism to translation. *Nature Med*. 2011;17;11:1391-401.
25. Sen S, Chakraborty R. The role of antioxidants in human health. *Oxidative stress: diagnostics, prevention, and therapy*. ACS Publications. 2011:1-37.
26. Ouyang L, Shi Z, Zhao S. Programmed cell death pathways in cancer: a review of apoptosis, autophagy and programmed necrosis. *Cell proliferation*. 2012;45;6:487-98.
27. Yoo MH, Gu X, Xu XM. Delineating the role of glutathione peroxidase 4 in protecting cells against lipid hydroperoxide damage and in Alzheimer's disease. *Antioxidants Redox Signaling*. 2010;12;7:819-27.
28. Oztay F, Kara-Kisla B, Orhan N, Yanardag R, Bolkent S. The protective effects of prostaglandin E1 on lung injury following renal ischemia-reperfusion in rats. *Toxicol Industrial Heal*. 2016;32;9:1684-92.
29. Kalogeris T, Bao Y, Korthuis RJ. Mitochondrial reactive oxygen species: a double edged sword in ischemia/reperfusion vs preconditioning. *Redox Biol*. 2014;2;702-14.
30. Cigremis Y, Kart A, Karaman M, Erdag D. Attenuation of ischemia-reperfusion injury with *Marrubium cordatum* treatment in ovarian torsion-detorsion model in rabbits. *Fertil Steril*. 2010;93;5:1455-63.
31. Van Golen RF, van Gulik TM, Heger M. The sterile immune response during hepatic ischemia/reperfusion. *Cytokine Growth Factor Rev*. 2012;23;3:69-84.
32. Bhattacharya S. Reactive oxygen species and cellular defense system. *Free radicals in human health and disease*. Springer. 2015:17-29.
33. Eefting F, Rensing B, Wigman J. Role of apoptosis in reperfusion injury. *Cardiovascular research* 2004;61;3:414-426.
34. Linkermann A, Brasen JH, Darding M. Two independent pathways of regulated necrosis mediate ischemia-reperfusion injury. *Proceedings National Academy Sci U S Am*. 2013;110;29:12024-9.
35. Eefting F, Rensing B, Wigman J. Role of apoptosis in reperfusion injury. *Cardiovascular Res*. 2004;61;3:414-26.
36. Broekmans FJ, Soules MR, Fauser BC. Ovarian aging: mechanisms and clinical consequences. *Endocr Rev*. 2009;30;5:465-93.
37. Ozler A, Turgut A, Soyuncu HE. The biochemical and histologic effects of adnexal torsion and early surgical intervention to unwind detorsion on ovarian reserve: an experimental study. *Reproduct Sci* 2013;20;11:1349-55.
38. Bristol-Gould SK, Kreeger PK, Selkirk CG. Fate of the initial follicle pool: empirical and mathematical evidence supporting its sufficiency for adult fertility. *Developmental Biol*. 2006;298;1:149-54.
39. Calis P, Bozdogan G, Karakoc Sokmensuer L, Kender N. Does ischemia-reperfusion injury affect ovarian reserve and follicle viability in a rat model with adnexal torsion? *Eur J Obstetr gynecol Reproduct Biol*. 2015;185:126-30.



40. Demir Caltekin M, Ozkut MM, Caltekin I. The protective effect of JZL184 on ovarian ischemia reperfusion injury and ovarian reserve in rats. *J Obstetr Gynaecol Res.* 2021;47;8:2692-704.

**Cite this article as:** Keleş ON, Erol HS, Keleş DV, Karaca M, Çakır A, Koç M et al. Protective effects of pomiferin isolated from *Maclura pomifera* on ischemia-reperfusion injury of rat ovary: biochemical and histopathologic evaluation. *Int J Res Med Sci* 2023;11:433-41.