

Review Article

Pseudoaneurysm due to femoral artery puncture: a review

Itaty C. González-Martínez¹, Juan José Granados-Romero², Jorge Montalvo-Hernández³,
Juan C. Vázquez-González², Patricia M. Palacios-Rodríguez⁴, Alondra Mendizabal-Velazquez⁵,
Ana L. Abundez-Pliego⁶, Alan I. Valderrama-Treviño¹, Baltazar Barrera-Mera^{5*}

¹Department of Angiology, Vascular and Endovascular Surgery, General Hospital of Mexico, Dr. Eduardo Liceaga, CDMX, Mexico

²Department of General Surgery, General Hospital of Mexico, Dr. Eduardo Liceaga, CDMX, Mexico

³Department of Surgery. Endocrine and Advanced Laparoscopic Surgery Service, North Central Hospital PEMEX, Mexico City, Mexico

⁴Department of Pediatrics, General Hospital of Mexico, Dr. Eduardo Liceaga, CDMX, Mexico

⁵Department of Physiology, Faculty of Medicine, UNAM, Mexico

⁶Department of Surgery, PEMEX General Hospital, Ciudad del Carmen, Mexico

Received: 20 July 2023

Accepted: 05 August 2023

*Correspondence:

Dr. Baltazar Barrera-Mera,

E-mail: baltazar.barrera.mera@gmail.com

Copyright: © the author(s), publisher and licensee Medip Academy. This is an open-access article distributed under the terms of the Creative Commons Attribution Non-Commercial License, which permits unrestricted non-commercial use, distribution, and reproduction in any medium, provided the original work is properly cited.

ABSTRACT

The femoral artery is the most used percutaneous access site for different endovascular therapeutic options, this being an excellent anatomical site to achieve adequate compression after its puncture, which frequently makes it the site with the highest incidence of complications associated with posterior to arterial puncture. The most frequent complications related to arterial puncture are: hematoma, pseudoaneurysm, retroperitoneal hematoma, and arterial occlusion. The pseudoaneurysm is defined as the interruption in the wall of the artery, product of the lesion of the wall, which causes blood leakage towards the surrounding tissues, remaining contained in a fibrin sac, therefore, the importance of an adequate diagnosis and treatment lies above all in the high risk of rupture or thromboembolism.

Keywords: Pseudoaneurysm, Femoral artery puncture, Endovascular treatment, Femoral pseudoaneurysm, Endovascular surgery

INTRODUCTION

The femoral artery is the most used percutaneous access site for different endovascular therapeutic options, this being an excellent anatomical site to achieve adequate compression after its puncture, which frequently makes it the site with the highest incidence of complications associated with posterior to arterial puncture.¹ The most frequent complications related to arterial puncture are: hematoma, pseudoaneurysm, retroperitoneal hematoma, and arterial occlusion.² The pseudoaneurysm is defined as the interruption in the wall of the artery, product of the lesion of the wall, which causes blood leakage towards the surrounding tissues, remaining contained in a fibrin sac, therefore, the importance of an adequate diagnosis

and treatment lies above all in the high risk of rupture or thromboembolism.³ Pseudoaneurysm is also known as false aneurysm and the presence of a pulsatile hematoma contained within a layer of fibrin and surrounding tissues is characteristic, which is communicated with the lumen of a damaged artery secondary to interruption of the three layers (intima, media and adventitia) of the arterial wall after puncture of the arterial vessel.⁴ Unlike aneurysms, pseudoaneurysms are contained only by the media and adventitia or only by the surrounding tissue.

ETIOLOGY

The common femoral artery is considered the most frequent site of presentation of post-puncture

pseudoaneurysms because it is an ideal site for puncture due to its larger size in relation to other sites and because it is located on the femoral head. This favors its palpation and compression plane after the puncture, Figure 1.

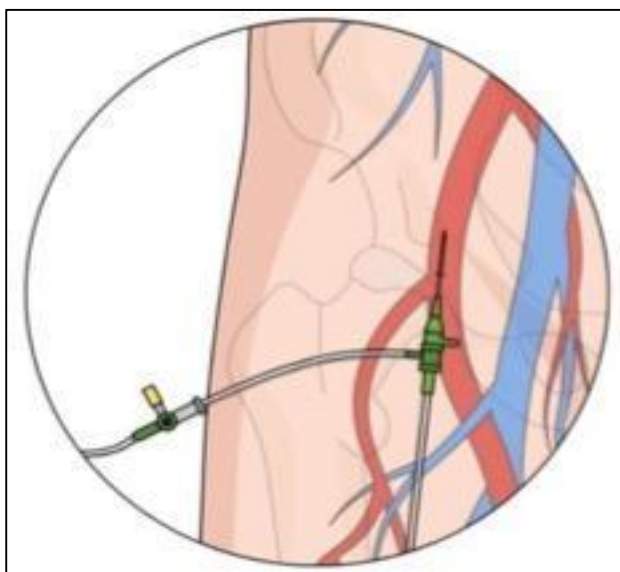


Figure 1: Anatomical relationship of the femoral artery and femoral head, proper puncture site.

Anatomically, the common femoral artery is the continuation of the external iliac artery and is the major source of blood supply to the lower extremity. It is located in the femoral sheath lateral to the femoral vein, which is located in the medial sheath, and the femoral nerve lies outside the sheath lateral to the artery. Distally, the common femoral artery divides into the superficial femoral artery and the deep femoral artery, Figure 2.

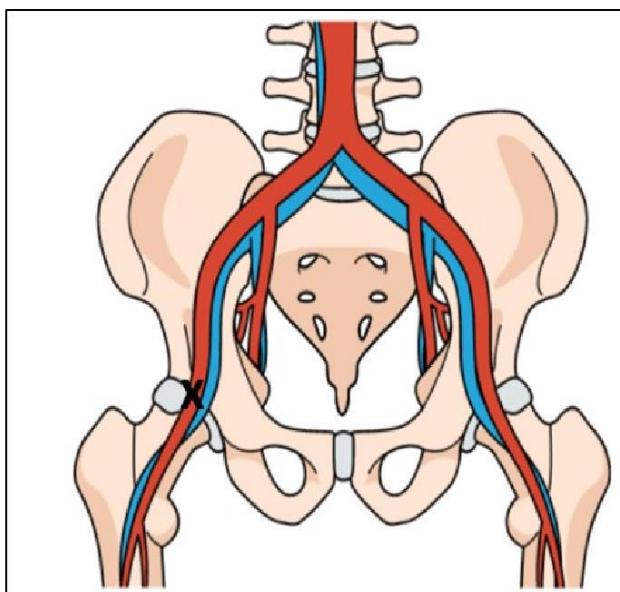


Figure 2: The ideal puncture site is marked with an “x”, on the femoral head and below the inguinal ligament.

Femoral artery pseudoaneurysms can especially occur when access is made in the wrong place, that is, below the bifurcation of the common femoral artery. Similarly, a puncture located above the inguinal ligament hinders arterial compression and favors the possibility of retroperitoneal bleeding, causing a retroperitoneal hematoma potentially expansive with high complication rates.²

Common femoral artery pseudoaneurysms occur when an arterial puncture site fails to close properly. At the puncture site there is bleeding towards the soft tissues and by pressure it dissects the tissue surrounding the injured artery, allowing the formation of long and narrow necks which allows the formation of the sac and walls of the pseudoaneurysm. Common femoral artery pseudoaneurysms are mainly generated by trauma, angiographic procedures, infections, and incorrect arterial puncture technique, generally associated with non-ultrasound-guided punctures; however, although less frequently, they can also be caused secondary to inflammatory pathologies of the vascular endothelium.³ An approximate incidence between 0.5 and 3.8% of femoral punctures is estimated.^{4,5} Therefore, it is essential to know the correct way to access the common femoral artery; which can be done guiding us in anatomical, radiographic or ultrasound-guided references.

ULTRASOUND-GUIDED ARTERIAL PUNCTURE

It is recommended that this procedure be performed with a linear vascular probe from 8 to 12 MHz. This method allows adequate visualization of the common femoral artery, its bifurcation into the superficial and deep femoral arteries, as well as the femoral head, which provides the main benefit of correct identification of the artery to be punctured during the procedure. Initially, the artery is assessed in its short or transversal axis. An image that gives the appearance of “Mickey Mouse” in the femoral head can be used as a reference, which can be viewed when the transducer is at the level of the common femoral vein (CFV), the common femoral artery and the great saphenous vein (GSV). Once the venous and arterial pathways are identified, ultrasound-guided anesthetic is infiltrated and puncture is performed prior to femoral artery bifurcation, at the height of the femoral head. Subsequently, the guide, dilator and introducer are placed to continue with the procedure to be performed. The most common cause of femoral artery pseudoaneurysms is related to the puncture technique of the artery itself, scant ultrasound training, poor identification of anatomical structures, patients in shock or with acute venous thrombosis where the vein becomes non-compressible, making puncture difficult. especially in medical residents. The use of introducers with the smallest possible diameter and imaging control followed by puncture are recommended. The safest access site is the upper medial quadrant of the femoral head in neutral anteroposterior views, Figure 3.

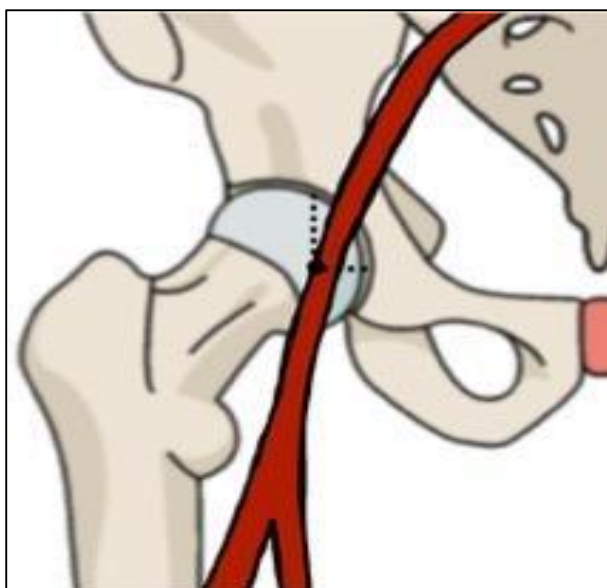


Figure 3: Anatomical representation of the ideal common femoral compression site, by performing a puncture on the femoral head, an adequate compression site is obtained.

EPIDEMIOLOGY

Common femoral artery pseudoaneurysm represents one of the most frequent local complications related to endovascular procedures. The incidence of iatrogenic pseudoaneurysms in the common femoral artery has increased in recent years, possibly in direct relation to the increase in endovascular procedures using this approach. The incidence is known to be 0.44 to 1.8% after diagnostic arterial catheterization and 3.2 to 7.7% after endovascular intervention.³ Angioplasty with coronary stent placement with femoral artery puncture has an incidence of 2 to 8% and 0.2 to 0.5% secondary to diagnostic arteriography. In general, the prevalence currently reported in adults is between 0.2 and 3.8%.⁴ However, the incidence can increase up to 16% in procedures with greater complexity, as well as with the use of larger caliber introducers as well as the combination of anticoagulation-antiplatelet therapy.⁶

RISK FACTORS

Risk factors possibly related to the formation of a femoral artery pseudoaneurysm can be classified as those related to the procedure, related to the technique, or related to the patient. The risk of presenting a femoral artery pseudoaneurysm following its puncture increases when there are factors related to the procedure, among which are the need to perform urgent therapeutic procedures, rather than diagnostic ones, the complexity of interventions such as stent placement coronary artery disease, atherectomy, intraprocedural thrombolytic therapy, and repeat coronary angioplasty; the duration of the procedure, inadequate compression after the procedure, catheterization of the femoral artery and vein

in the same procedure, low catheterization of the femoral artery (superficial or deep) and not of the common femoral artery, as well as catheterization at the level of the external iliac artery.⁵ Among the risk factors present in the patient that contribute to the formation of the pseudoaneurysm are: advanced age over 75 years, obesity, female sex, highly calcified arteries, hemodialysis patient, platelet abnormalities, early mobilization of the hindlimb to the procedure, systemic arterial hypertension, use of antiplatelet agents and anticoagulation.⁷ Risk factors related to the technique include low puncture (superficial or deep femoral artery), use of more complex devices that require the use of larger introducers, inadequate post-procedure compression, puncture guided by anatomical references without ultrasound.⁵

DIAGNOSIS

In some cases, the patient may be asymptomatic or may affect the distal circulation the presence of a pulsatile and painful local hematoma can be observed at the "puncture site", also depending on the size of the sac there may or may not be symptoms of venous, arterial or nerve compression.⁷ In cases that are accompanied by an arteriovenous fistula, it may present with a thrill or murmur on palpation. In a serious way, a pseudoaneurysm can present clinically with a continuous frank arterial hemorrhage with rapid expansion of the hematoma, or in a less serious way a temporary hemorrhage that remains stable.³

Initially, for an early diagnosis, a high index of clinical suspicion is required, which is why a directed physical examination is necessary, as well as evaluating the persistence of the patient's symptoms after the procedure, requiring additional diagnostic studies. Classically and early, patients present localized pain, edema and depending on the anatomical region there may or may not be an expansive hematoma at the puncture site or its surroundings. As the pseudoaneurysm grows, compression of nerve structures occurs, rarely causing deep vein thrombosis. In late stages of presentation, arterial compression manifests as absence of distal pulses as well as ischemia of the extremities. The D-dimer measurement may be elevated, the platelet counts less than 200,000 which have been associated with the presence of pseudoaneurysm.²⁻⁴ In case of suspected diagnosis of pseudoaneurysm, a confirmatory imaging study is required. Among the imaging studies to be requested initially is Doppler ultrasound, angiotomography or angiography. Currently, the gold standard for diagnosis of pseudoaneurysm of the femoral artery is real-time Doppler ultrasound due to its low cost, minimal invasiveness, and zero exposure to radiation and contrast. The sensitivity of Doppler ultrasound to identify pseudoaneurysms is 94%, with a specificity of 97%, the characteristics of the pseudoaneurysm can be evaluated: size, presence of hematoma in surrounding tissues, length of the neck

diameter, flow velocity in the femoral artery. and within the pseudoaneurysm, jet leakage, patency of surrounding vasculature. As well as the presence of compression of surrounding venous or arterial vascular structures. For its adequate visualization, a linear transducer from 4 to 8 MHz is used, in the B mode of ultrasound, the echotransparent sac can be visualized, which expands and contracts synchronously with cardiac contractions. Color Doppler can classically visualize “yin-yang” flow, which is present in most pseudoaneurysms, Figure 4. This characteristic ultrasonographic sign is created by the path of blood flow from the arterial lesion to the fibrin sac in

which it is contained; back and forth image. Placing the cursor on the neck a pulsed flow is observed “to and fro”, movement of blood from inside to outside the walls of the pseudoaneurysm, classically described as an eddy flow pattern, with turbulence in the chambers.⁸ The ultrasound diagnostic triad of femoral pseudoaneurysms is characterized by:⁵ 1. Hypoechoic sac in proximity to the vessel wall, 2. High flow resistance within the mass using Doppler and 3. Yin-yang flow pattern in the neck of the pseudoaneurysm or in the sac near the neck, which represents flow synchronous with the cardiac cycle.

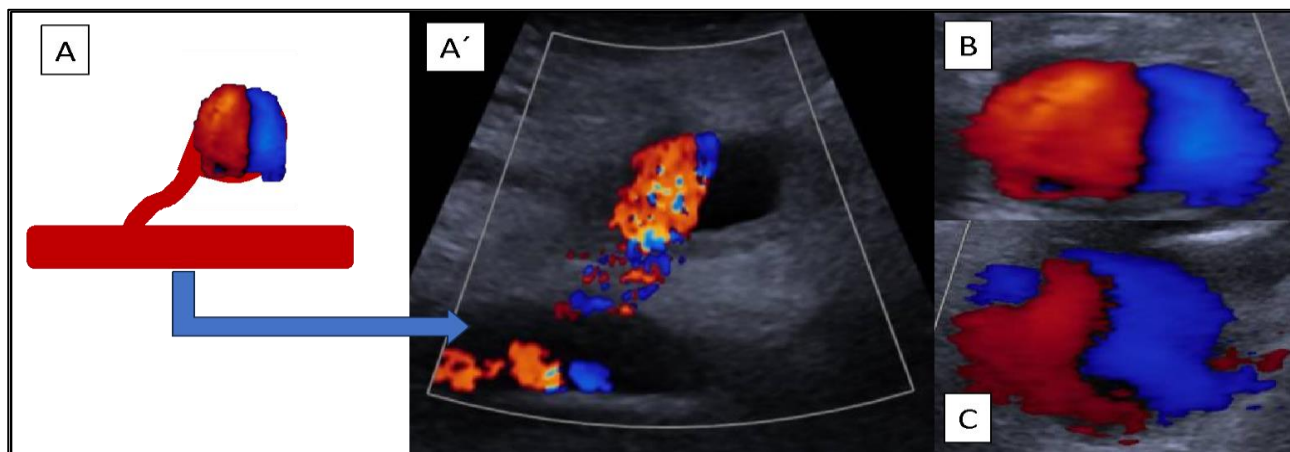


Figure 4 (A-C): Yin-yang images in patients with femoral artery pseudoaneurysm. Schematic representation of the pseudoaneurysm identified in.

Ultrasound, in addition to being a diagnostic study, has been used as initial therapy through compression or support for thrombin injection. Angiography allows us to identify the presence of pseudoaneurysms, as well as to evaluate the characteristics of the entire arterial tree distal to the pseudoaneurysm. Among the disadvantages it is considered that it is an invasive study since it implies a new puncture, increasing the risks of presenting a new pseudoaneurysm in addition to using contrast medium, it has a high cost. Regarding the evaluation of the venous system, it is not accurate and a new venipuncture could be required to perform a diagnostic phlebography.⁹ Magnetic resonance is a non-invasive diagnostic method, it uses non-nephrotoxic contrast such as gadoline, however it is expensive and is not available in all hospitals. CT angiography allows us to appreciate a contained area of blood as well as the site of arterial injury. However, using this study it is not feasible to assess the neck of the pseudoaneurysm. Among the disadvantages of this study, are the exposure to radiation, as well as intravenous contrast and the high cost that this entails.

TREATMENT

The importance of treating femoral artery pseudoaneurysms lies in the risk of free rupture as well as thromboembolism. Treatment of pseudoaneurysms may

include surveillance, as well as noninvasive procedures, endovascular intervention, or surgical management. Each of these therapeutic options presents risks and benefits, in addition, according to the time of evolution and clinical presentation, some are ideal for treatment.

OBSERVATION AND SURVEILLANCE

In pseudoaneurysms smaller than 2 cm, they can be watched and monitored with ultrasound. It is recommended to repeat the imaging study a week after the procedure performed, and if there is no evidence of expansion or worsening of symptoms, the patient can continue without requiring intervention. Subsequently, an ultrasound is recommended the following month, to assess whether or not it has thrombosed. Stone et al reviewed a series of studies of pseudoaneurysms in the femoral artery in the 1990s, where they demonstrated thrombosis rates of 58 to 100% with pseudoaneurysms with a size of 3.5 cm. With what they demonstrated that patients with anticoagulation after the procedure with neck lengths less than 0.9 cm and higher flow volumes had a greater probability of not thrombosing and ultimately requiring intervention.¹⁰ Toursarkissian et al demonstrate that a median time to thrombosis of a common femoral artery pseudoaneurysm with dimensions of at least 3 cm is 23 days.³ Most pseudoaneurysms with a maximum diameter of less than

3 cm resolve spontaneously in a period of approximately 4 weeks. Therefore, in these cases, resolution of the pseudoaneurysms can be expected with conservative management and surveillance in the case of asymptomatic presentation and in the absence of complications.

COMPRESSION TREATMENT

After arterial puncture, adequate compression is recommended, which can be manual or mechanical. In relation to manual compression of the puncture site, it is recommended that this be done using 2 to 3 fingers on the puncture site, with occlusive pressure for 10 to 15 minutes and 1 hour of bed rest followed by 1 hour of observation after ambulation.¹¹ Compression of 3-5 minutes is suggested for each French (Fr) used.

ULTRASOUND GUIDED COMPRESSION

Within non-invasive methods, the use of ultrasound-guided compression has been described. This has become the initial treatment method for common femoral artery pseudoaneurysms with dimensions greater than 2 cm but less than 4 cm. Likewise, it is recommended to perform it in acute or pseudoacute pseudoaneurysms, which are at least one month old. This technique was first described in 1991 by Fellmeth and his colleagues.⁶ In order to achieve closure of the pseudoaneurysm by means of ultrasound-guided compression, it is necessary that while the maneuver is performed, correct compression of the neck of the pseudoaneurysm is achieved, preventing the flow of the artery to the cavity, thus achieving thrombosis.⁹ The correct way to perform it is that once the

pseudoaneurysm, native artery and connecting neck have been identified, the ultrasound transducer is placed to view the neck, then force is applied with the transducer until the flow through is eliminated. of the tract without compromising flow through the native artery. Direct pressure is applied for approximately 30 minutes, followed by slow release of compression. Thrombosis can be monitored at 10-min intervals. In case of observing a persistent flow in the pseudoaneurysm, the process can be repeated until success is achieved with the elimination of the flow in the sac of the pseudoaneurysm. To achieve success, compression times vary from 10 to 150 minutes with a mean of 30 to 53 minutes reported in the literature. Subsequently, patients are kept on bed rest for up to 24 hours after the compression procedure.³ Among the contraindications to perform ultrasound-guided compression are evidence of infection at the puncture site, associated compartment syndrome, skin ischemia as well as the inability to occlude the tract or neck without occluding the native vessel, location of the puncture site in sites inaccessible by the transducer, pseudoaneurysms located above the inguinal ligament due to increased risk of rupture and uncontrollable bleeding, as well as ischemia of the compromised limb. A success rate using ultrasound-guided compression therapy of 60 to 93% has been identified.³ This procedure is considered ineffective in cases where pseudoaneurysms are large, with more than two weeks of evolution and in patients with current treatment with anticoagulant therapy. Disadvantages include increased therapeutic time, pain for the patient, prolonged hospital stay due to the requirement of multiple attempts, and required post-procedure surveillance, as well as increased anticoagulation failure rate.

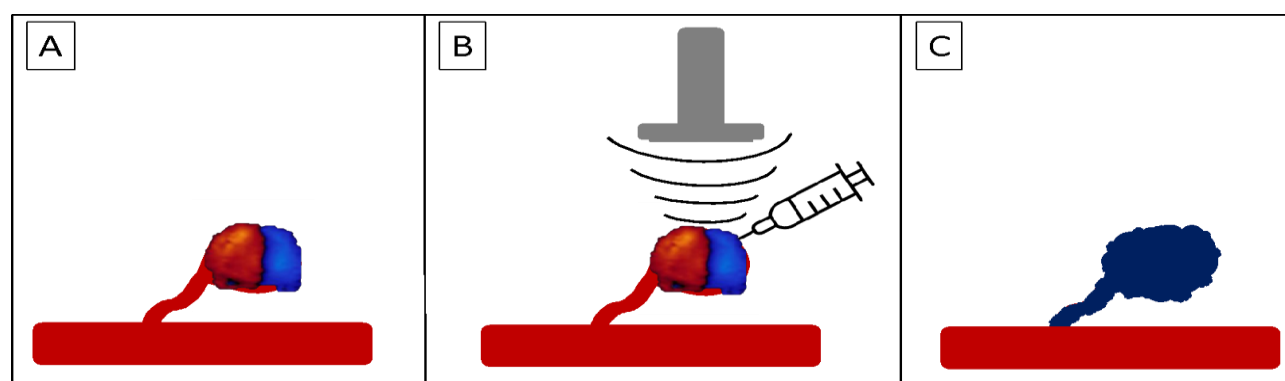


Figure 5 (A-C). Representation of thrombin infiltration in the sac of the pseudoaneurysm. Pseudoaneurysm with a long neck, ideal for injection with thrombin. Ultrasound-guided injection of thrombin. Pseudoaneurysm thrombosis.

ULTRASOUND-GUIDED THROMBIN APPLICATION

Percutaneous treatment can be performed by ultrasound-guided application of thrombin. It has recently become the standard of care in the treatment of pseudoaneurysm in stable patients with adequate anatomy. As a result of

this, a success rate of 93 to 100% has been evidenced.³ This procedure was initially described in the years from 1986 to 1998 by Cope and Zeit, Liao and Cols, as well as Kang and Cols.¹² It is a highly effective technique that produces little discomfort for the patient, does not restrict anticoagulation treatment and can be performed in a room with ultrasound. There are reports where it has been used

in pseudoaneurysms with 2 years of evolution.¹³ Thrombin (Factor IIa) converts fibrinogen to active fibrin, which in the presence of calcium binds to factor VIIIa causing thrombus formation. One of the two available forms of thrombin can be used, which are bovine and human thrombin.¹⁴ Therefore, when thrombin mixes with blood from the sac, it converts to a solid thrombus. Ideally, adequate ultrasonographic planning is required prior to thrombin embolization, so measurement of the neck of the pseudoaneurysm and the sac must be taken into account. Thrombin is prepared in a 1,000 IU/mL syringe. The amount of thrombin necessary to thrombose the pseudoaneurysm ranges from 300 to 4,000 units described in the literature. A more dilute concentration of 100 IU/mL has been shown to be effective, and therefore uses less thrombin, and is less likely to embolize into the native vessel. The site is aseptically and antiseptically, the pseudoaneurysm area is visualized with a linear transducer and punctured with a 20-22 G needle until pulsatile blood return is obtained from the puncture needle. The thrombin is injected slowly for approximately 5 seconds and compressed, (Figure 5) making sure that there is no leak jet when compromising the pseudoaneurysm with the transducer. Evidence of pseudoaneurysm thrombosis occurs practically after placement of human thrombin within the pseudoaneurysm sac.

Most of the published reports on the treatment of pseudoaneurysms by ultrasound-guided thrombin application are found in the common femoral, superficial femoral, and profunda femoral arteries. Recurrence rates of up to 3.4% have been described.¹⁵ Among the probable complications secondary to thrombin infiltration, there is an abrupt interruption of blood flow due to the extravasation of thrombin into the artery, as well as the probable rupture of the pseudoaneurysm.¹⁶ Among the advantages of ultrasound-guided thrombin injection versus ultrasound-guided compression, a success greater than 96% versus 74% is identified in the latter, it is considered a shorter procedure of 6 seconds versus 41.5 minutes, better patient tolerance, that is, less pain, does not require sedation, is effective in those patients who are under anticoagulant treatment, useful in pseudoaneurysms that are located above the inguinal ligament, and is less expensive.¹⁷ Contraindications to percutaneous thrombin injection are the presence of arteriovenous fistula, pregnancy, skin infection in groin, thrombin allergy, or previous failed thrombin injection.¹⁸

TIPS AND TRICKS IN ULTRASONOGRAPHIC EMBOLIZATION WITH THROMBIN

Within the recommendations to avoid the presentation of complications, it is suggested to inject the thrombin in the sac of the pseudoaneurysm as far away from the neck of the same, as well as infiltrating in minimal doses, avoiding compression of the neck during injection, as well as avoiding excessive manipulation in cases that are difficult to access (Table 1).¹⁹

Table 1: Tips and tricks in ultrasonographic embolization, with thrombin.

S. no.	Tips and tricks in ultrasonographic embolization.
1	Inject thrombin into the sac of the pseudoaneurysm as far away from the neck of the pseudoaneurysm as possible.
2	Infiltrate in minimal doses
3	Avoid neck compression during injection.
4	Avoid excessive manipulation in cases that are difficult to access.

Arteriography-guided thrombin injection

Targeted thrombin can be applied by arteriography or via angiography.²⁰ For this technique, it is recommended to use adequate radiation protection, angioplasty balloon is placed in the injured artery at the level of the neck of the pseudoaneurysm, in order to occlude the conduit in the artery wall during thrombin injection, trying to avoid thromboembolic complications.

Percutaneous saline injection

The application of saline solution can be performed with the support of ultrasound or angiography, its mechanism of action is associated with the compression maneuver. It is required that the neck of the pseudoaneurysm be fully compressed while performing the maneuver, in order to achieve an adequate seal of the pseudoaneurysm through compression and thus prevent the flow of the artery to the pseudoaneurysm cavity, waiting for a subsequent thrombosis of the pseudoaneurysm. Saline injection is performed followed by short duration manual compression. 30 to 35 ml of saline solution are applied, it is done as close as possible to the neck in order to cause edema in the region surrounding the neck. Thus, facilitating the occlusion of the neck.

ENDOVASCULAR TREATMENT

Percutaneous intervention is considered a less invasive option with a lower risk of complications. Endovascular management of pseudoaneurysms can be used in highly selected cases, for peripherally located pseudoaneurysms. As well as treatment in those patients in whom compression and/or thrombin injection have failed or who are not candidates for this procedure and have a high cardiovascular risk in open surgery.²¹ Recently, what has been described in this technique is the use of covered stents, direct coil embolization or bare stents with coils placed through them or endoluminal prostheses (by contralateral or ipsilateral femoral access). It is also recommended in those patients with arteriovenous fistula.²² In relation to embolization with coils, it can be done in two ways: a percutaneous route is accessed directly to the cavity of the pseudoaneurysm, where several coils are inserted, with thrombogenic capacity, waiting for the obliteration and thrombosis of the

pseudoaneurysm. Another way of handling with coils is by catheterization of the femoral artery, to proceed to insert the coils in the neck of the pseudoaneurysm, with the purpose of causing local thrombosis not only in the neck, but also in the cavity.²³ In narrow neck pseudoaneurysms, the use of compact stainless steel or platinum coils is an alternative with a high success rate, achieving local lumen thrombosis. Antonello et al performed the first randomized study that compares surgical resolution against the endovascular method, in which they recommend avoiding stent overexpansion, maintaining antiplatelet therapy, not superimposing stents, and avoiding the arterial area of the knee fold.²⁴

Since the first published case of resolution with covered stents in 1994, there are numerous case series that show a safe and effective clinical outcome in patients with surgical contraindications, in whom resolution was performed using covered stents with a low rate of stent occlusion if used. maintain adequate antiplatelet therapy. Tielliu et al it has one of the largest series of endovascular repair, and its results show that most occlusions of implanted stents occur in the first days after implantation. however, a substantial decrease in this complication was evidenced when adequate oral antiplatelet therapy is maintained.²⁵ The use of covered stents is a therapeutic alternative in cases of arteriovenous fistulas or cases of femoral or external iliac arterial rupture, with presence of massive uncontrollable bleeding and hemodynamic decompensation. Its use is not appropriate when pseudoaneurysm invades bifurcation of the common femoral artery, due to the risk of occlusion of the deep femoral artery; In addition to the fact that it is contraindicated to perform new arterial punctures in the segment of the endopthesis insertion, losing function of vascular access route.⁹ The disadvantage of endovascular management is the high cost. If there is persistent flow in the pseudoaneurysm after the procedure, there may be pain and skin necrosis when the coils are implanted close to the skin.²⁶ Among contraindications for endovascular management we find location of pseudoaneurysm near the bifurcation of the common femoral artery due to the risk of occlusion of the deep femoral artery, loss of a future access route due to the risk of stent perforation, skin infection in the segment to be punctured.

OPEN SURGICAL MANAGEMENT

Surgical repair was considered the treatment of choice for iatrogenic pseudoaneurysms until 1991.⁶ Currently it remains the definitive repair for pseudoaneurysms of the peripheral arteries. Surgical treatment is reserved for complex pseudoaneurysms with multiple lobes, short necks or no necks that have ruptured or with unstable patients, when the superimposed skin has been compromised, presents vascular or nervous compromise, and may imply the presence of infection, its etiology is related to trauma or for those pseudoaneurysms that have not responded to non-invasive therapies (Table 2). Surgical management is recommended when lesion site is

located at level of vascular anastomosis, compression of the underlying structures by an expanding pulsatile mass that causes claudication, neuropathy, or critical limb ischemia. However, open surgical treatment of pseudoaneurysms secondary to cardiac catheterizations is not very frequent.²⁷ Regarding the surgical technique, the surgeon often prefers to enter the pseudoaneurysm cavity directly, and through it, repair the artery, with digital angiographic control. In other cases, it is preferred to obtain blood flow control in the distal external iliac artery through a transverse incision in inferolateral abdominal wall, in order to proceed with pseudoaneurysm repair.⁹

Table 2: Indications for open surgical repair of pseudoaneurysms.

S. no.	Indications for open surgical repair of pseudoaneurysms
1	Infected femoral artery pseudoaneurysm
2	Rapid expansion of hematoma
3	Failure to use other therapies
4	Thrombin allergy
5	Presence of skin necrosis
6	Presence of compression syndromes
7	Neuropathic
8	claudication
9	Critical limb ischemia

Rarely, arterial reconstruction using prosthetic material or saphenous vein grafts is necessary. The disadvantages of surgical procedures are the need to use regional or general anesthesia as well as the need for an incision at the inguinal level, an area known to be easily infected. The risks associated with open surgery include bleeding, surgical wound infection, seromas, nerve structure injuries, as well as anesthetic complications.

CONCLUSION

There are different alternatives for the treatment of post femoral artery puncture pseudoaneurysms, the increasing use of thrombin has decreased the number of open procedures required. It is essential to train resident physicians in ultrasound-guided puncture skills with the use of simulators. In our experience, we always suggest ultrasound-guided arterial punctures and, if possible, in the catheterization room for immediate angiographic control.

Funding: No funding sources

Conflict of interest: None declared

Ethical approval: Not required

REFERENCES

- Robertson L, Andras A, Colgan F, Jackson R. Dispositivos de cierre vascular para la hemostasia del sitio de punción de la arteria femoral. Cochrane Database Systematic Rev. 2016;3:1-208.

2. Hernandez J, Casares T, Hernandez D, Moreno J, Mijandos W, Lagunasm J, Aguilar V et al. Reparación de trauma vascular femoral secundario a dispositivo de cierre vascular. *Revista Mexicana de Angiología. Hospital Regional Ignacio Zaragoza.* 2022;50(2):50-55.
3. Henry J, Franz RW. Pseudoaneurysms of the Peripheral Arteries. *Int J Angiol.* 2019;28(1):20-4.
4. Eisele G, Lascano F, Aboud G, Bendersky T. Pseudoaneurisma traumático de rama muscular de arteria femoral superficial en un paciente pediátrico. *Arch Argnt Pediatr.* 2020;118:396-9.
5. Ahmad F, Turner S, Torrie P, Gibson M. Iatrogenic femoral artery pseudoaneurysms- a review of current methods of diagnosis and treatment. *Clin Radiol.* 2008;63(12):1310-6.
6. Olsen DM, Rodríguez JA, Vranic M, Ramaiah V, Ravi R, Diethrich E, Jiménez C. Estudio prospectivo del tratamiento de los pseudoaneurismas de la arteria femoral con inyección de trombina guiada por ultrasonido: hacia una terapia menos invasiva. *Angiología.* 2007;59(6):421-6.
7. Stone PA, Campbell JE, AbuRahma AF. Femoral pseudoaneurysms after percutaneous access. *J Vasc Surg.* 2014;60(05):1359-66.
8. García M, Perez E, Fernández H. Compresión con guía ecográfica, como tratamiento del pseudoaneurisma femoral pos cateterismo. *Revista Peruana de Cardiología.* 2008;34(2):113-21.
9. Dos Santos Nogueira AC, González Salgado C, Dos Santos Nogueira FB, Do Amaral SI, Rabischoffsky A. Pseudoaneurismas: Cuándo y cómo tratarlos. *Arq Bras Cardiol: Imagem Cardiovasc.* 2013;26(4):289-307.
10. Toggweiler S, Leipsic J, Binder RK, Freeman M, Barbanti M, Heijmen RH et al. Management of vascular access in transcatheter aortic valve replacement: part 2: Vascular complications. *JACC Cardiovasc Interv.* 2013;6:767-76.
11. Thomas M, Tu M, Tremmel M. Management of Femoral Arterial Access: To Close or Hold Pressure? *Endovascular Today.* 2007;38-42.
12. Armendariz J, Llamas F, Nuño C. Embolización ecodirigida de pseudoaneurismas con trombina humana en pacientes del Servicio de Angiología del Centro Médico Nacional de Occidente del Instituto Mexicano del Seguro Social. Estudio de serie de casos. *Revista Mexicana de Angiología.* 2018;46(1):4-8.
13. Seto AH, Abu-Fadel MS, Sparling JM, Zacharias SJ, Daly TS, Harrison AT et al. Real-time ultrasound guidance facilitates femoral arterial access and reduces vascular complications: FAUST (Femoral Arterial Access with Ultrasound Trial). *JACC Cardiovasc Interv.* 2010;3:751-8.
14. Tisi P, Callam M. Tratamiento para el pseudoaneurisma femoral. Revisión. *Cochrane Collaboration.* 2013;11:3-24.
15. Cuneo T, Pedemera G, Spaletta P, Avegliano G, Perea G, Candiello A et al. Tratamiento del pseudoaneurisma femoral mediante la inyección local de trombina. *Rev Argent Cardiol.* 2017;85:235-40.
16. Romero H, Fuentes A, Salinas R, Muñoz G. Pseudoaneurisma de la arteria femoral profunda secundario a traumatismo penetrante. Informe de caso. *Revista De Cirugía.* 2021;73:91-4.
17. Sanmartín M, Goicolea J, Mantilla R, Ruiz R, Calvo F, Bravo M. Inyección percutánea de trombina para el cierre de pseudoaneurismas femorales: experiencia preliminar. *Servicio de Cardiología Intervencionista y sección de cardiología.* 2012;55:771-4.
18. Carrillo M, Quintanilla J. Tratamiento de pseudoaneurisma femoral mediante inyección percutánea de trombina guiada por ultrasonido. *Anales de Radiología México.* 2005;4:311-414.
19. Privitera D, Mazzone A, Pierotti F, Airoidi C, Galazzi A, Geraneo A et al. Ultrasound-guided peripheral intravenous catheters insertion in patient with difficult vascular access: Short axis/out-of-plane versus long axis/in-plane, a randomized controlled trial. *J Vasc Access.* 2021;23(4):589-97.
20. Wyss CA, Anliker O, Gämperli O, Sürder D, Biaggi P, Buhler I et al. Closure of Large Percutaneous Femoral Venous Access Using a Modified "Figure-of-Eight" Suture. *Innovations (Phila).* 2018;13:147-51.
21. Patrón M, Russo A, De Sosa F, González G, Al Esperón. Experiencia en el tratamiento endovascular de pseudoaneurismas arteriales infecciosos: presentación de tres casos clínicos. *SEACV y Aran. Ediciones SL. Angiología.* 2021;73(2):95-9.
22. Escobar A, Alonso H, Artaza E, Franceda A. Pseudoaneurisma de la arteria femoral derecha posterior a cateterismo cardíaco. *Revista Cubana de Angiología y Cirugía Vascular.* 2021;22:2-9.
23. González D, Hasbun S, Tapia R, Herrera J, Tepper P, Molina G et al. Tratamiento de pseudoaneurisma iatrogénico con compresión ecoguiada. *Revista Chilena de Cirugía.* 2018;70:354-357.
24. Girassolli A, Rattagan P, Garre L, Cimadevilla A, Perez P, Leiva G, Payaslian M. Manejo endovascular de un pseudoaneurisma gigante de la arteria femoral superficial. *Revista Argentina de Cardioangiología Intervencionista.* 2017;8(2):86-8.
25. Redecilla MB, Cantero RP, Romero S, Bendahan VDL. Pseudoaneurismas iatrogénicos: manejo mínimamente invasivo. *Sociedad Española de Radiología Médica.* 2014;1092:7-9.
26. Kufner S, Cassese S, Groha P, Byrne R, Schunkert H, Kastrati A et al. Covered stents for endovascular repair of iatrogenic injuries of iliac and femoral arteries. *Cardiovasc Revasc Med.* 2015;16(03):156-62.
27. Huseyin S, Yuksel V, Sivri N, Gur O, Gurkan S, Canbaz S et al. Surgical management of iatrogenic femoral artery pseudoaneurysms: a 10-year experience. *Hippokratia.* 2013;17(04):332-6.

Cite this article as: González-Martínez IC, Granados-Romero JJ, Montalvo-Hernández J, Vázquez-González JC, Palacios-Rodríguez PM, Mendizabal-Velazquez A et al. Pseudoaneurysm due to femoral artery puncture: a review. *Int J Res Med Sci* 2023;11:3521-8.