

## Research Article

# Accuracy of frozen section analysis in correlation with surgical pathology diagnosis

Parikshit Patil\*, Samarth Shukla, Arvind Bhake, Kishore Hiwale

Department of Pathology, Jawaharlal Nehru Medical College, Sawangi (Meghe), Wardha, Maharashtra, India

**Received:** 14 December 2014

**Accepted:** 15 January 2015

**\*Correspondence:**

Dr. Parikshit Patil,

E-mail: parikshitpatil@gmail.com

**Copyright:** © the author(s), publisher and licensee Medip Academy. This is an open-access article distributed under the terms of the Creative Commons Attribution Non-Commercial License, which permits unrestricted non-commercial use, distribution, and reproduction in any medium, provided the original work is properly cited.

### ABSTRACT

**Background:** Intra-operative consultation by frozen section is a high risk procedure with important consequences. Therefore it is critical to determine efficiency of frozen section performance periodically. This study was performed to determine accuracy of frozen section.

**Methods:** In this prospective study, we compared the results of 100 consecutive cases of frozen section with their final permanent section diagnosis in a teaching hospital of Jawaharlal Nehru Medical College, Wardha, Maharashtra during July 2012 to June 2014.

**Results:** A total of 100 cases were studied on frozen section while one case was deferred for permanent paraffin section (deferral rate 01%). The overall accuracy of frozen section was 96.96% with false positive and false negative rates of 1.01% and 2.02% respectively. Sensitivity, specificity, positive predictive value and negative predictive value were 97.22%, 96.30%, 98.59% and 92.86% respectively. The turn-around time of 18 minutes was observed in the present study.

**Conclusions:** The accuracy of frozen section diagnosis at our institute can be interpreted as comparable with most international quality control statistics for frozen sections. The overall error rate and deferral rates are within the range previously published studies. The results suggest specific measures should be taken to reduce the number of discrepancies.

**Keywords:** Intra-operative consultation, Frozen section, Accuracy, Turnaround time, Quality assurance

### INTRODUCTION

Tissue specimen taken from a patient by doing biopsy or an operation is usually assessed by the pathologist on the following day after the specimen is adequately fixed in formalin. However, occasionally surgeons need pathologic information more urgently thus, they will request for an intra-operative consultation on the tissue that is being taken out. The examination is made while the patient is under anesthesia on the operating table. The examination report will then be conveyed as soon as possible to the operating surgeon via telephone or intercoms and the result will greatly influence the surgeon's intra-operational decision.<sup>1</sup>

The main purpose of frozen section is to provide rapid diagnosis to guide intra or perioperative patient management. The indications of frozen section are identification of tissue and unknown pathological processes, evaluation of margins, identification of lymph node metastasis, confirmation of presence of representative samples for paraffin section diagnosis and to determine the nature of a lesion that may require ancillary test. Frozen section is chiefly performed to determine whether the tissue being sampled is malignant or benign. It should not be used to merely to satisfy a surgeon's curiosity, to compensate for inadequate preoperative evaluation, or a mechanism to communicate information more quickly to the patient or patient's family.<sup>1</sup>

Periodic review of the correlation between frozen section diagnosis and final diagnosis is useful to identify the potential causes of errors and thus measures can be implemented to help prevent similar occurrences. Long term monitoring of frozen-permanent section correlation is associated with sustained improvement in performance.<sup>2</sup>

This study aims to assess the degree of diagnostic accuracy of frozen section examination of various anatomical sites, the overall accuracy, sensitivity, specificity and turn-around time of the frozen section technique.

## METHODS

The present study was carried out in the Frozen Section and Histopathology Division of Department of Pathology, Jawaharlal Nehru Medical College, Sawangi (Meghe), Wardha, Maharashtra from 1st July 2012 to 31st July 2014. During this study period, a total of 100 patients underwent surgery with intra-operative pathologic consultation for various malignant and non-malignant conditions.

For frozen section, fresh tissue was sent from the operation theater to the frozen section room and the gross specimens were inspected, dissected and blocks were cut on the cryostat (Leica CM 1510S) using Optimal Cooling Temperature (OCT) compound as embedding medium followed by rapid Hematoxylin-Eosin staining.

Surgeons were immediately informed of frozen section diagnosis orally in the operation room or through the interphone.

Frozen tissue as well as any remaining non frozen tissue were then fixed in 10% formalin solution and sent to Histopathology section where they were processed for routine paraffin section and followed by conventional Hematoxylin-Eosin staining on next day as per standard protocols and further reporting was done.

The impression of the pathologist as given to the surgeon at the time of surgery was compared to the final histopathology report of the permanent sections. The accuracy rate, sensitivity, specificity and the turn-around time of the frozen section reporting was determined in comparison to the routine histopathology reporting.

## RESULTS

In this group of 100 patients, 44 were male and 56 were female. The age range was wide and varied from 02 years to 76 years.

The most common indications for frozen section encountered in our institute were:

- i) Primary diagnosis (55%),

- ii) Assessment of margins of tumor excision (34%) and
- iii) Assessment of nodal status (11%) mostly in breast and oral malignancies.

From the point of tissue origin, the common organs sent for frozen section diagnosis were Oral cavity- 23 (23%), Breast-16 (16%), CNS-12 (12%), Ovary-11 (11%), Lymph node-11 (11%), Thyroid-09 (09%), GIT- 06 (06%), Skin and adnexa- 04 (04%), Soft tissue- 02 (02%), Uterus-01 (01%), Testis-01 (01%), Penis-01 (01%) and Miscellaneous-03 (03%) in descending order.

Out of 100 cases, 01 case was deferred for permanent section, this gave a deferral rate of 01%. Deferred diagnosis involved specimen from the Pancreas. The case was deferred due to inadequate material sent for the frozen section.

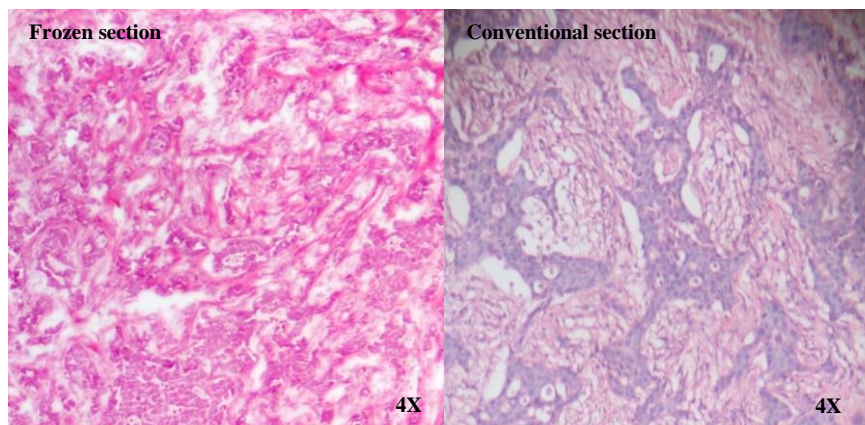
Excluding one deferred case, remaining ninety nine cases were analyzed based on basic diagnosis given on frozen section and conventional histopathology.

**Oral cavity** comprised 23 cases of all frozen sections. Squamous cell carcinoma was the diagnosis on both frozen section as well as conventional histopathology section. This gave 100% accuracy rate. The frozen section was mostly done to evaluate the adequacy of surgical margin resection in these cases.

**Breast** comprised sixteen cases; Infiltrating ductal carcinoma (13 cases), benign phyllodes (02 cases) and fibroadenoma (01 case). Infiltrating ductal carcinoma was the most common diagnosis on frozen section (Figure 1). In one case, the diagnosis of Benign phyllodes (benign) on frozen section turned out to be Malignant phyllodes (malignant) on conventional histopathology. This case comprised false negative diagnosis on frozen section. The accuracy of frozen section diagnosis for breast was found to be 93.75%.

**Brain** comprised eleven cases of all frozen sections. The diagnoses were- astrocytoma (05 cases), meningioma (03 cases), and schwannoma, malignant round cell tumor, haemangioblastoma, choroid plexus carcinoma (01 case each). All the frozen sections were performed for the diagnosis of tumor type. On comparing the frozen section diagnoses with conventional histopathology, all results were concordant except for one. In one case, the diagnosis of Choroid plexus carcinoma (malignant) on frozen section turned to be Choroid plexus papilloma (benign) on conventional histopathology. This case comprised single false positive diagnosis on frozen section. The accuracy rate of frozen section for brain lesions found to be 91.66%.

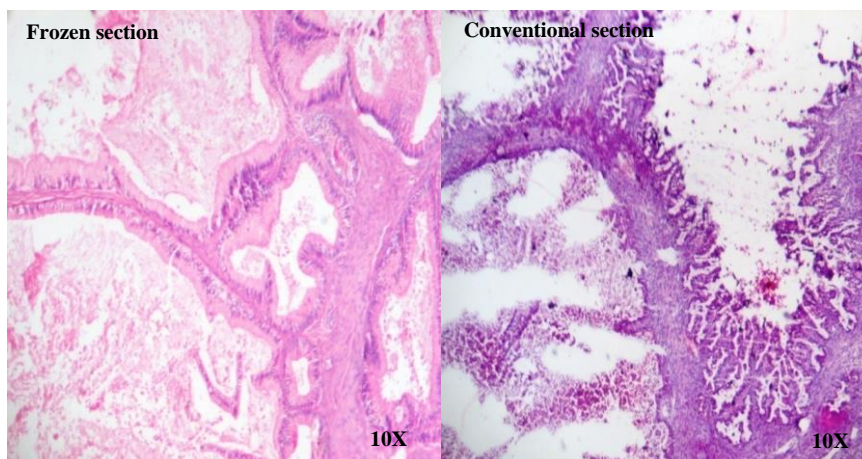
Eleven **lymph nodes** were subjected for frozen section to assess the nodal status in cases of malignancy. There was 100% concordance between frozen section and conventional histopathology diagnosis.



**Figure 1: 4X view of rapid H&E stained slide of Frozen section and 4X view of routine H&E stained slide of Conventional histopathology section shows infiltrating ductal carcinoma of breast.**

**Ovary** comprised eleven cases of all frozen sections. The most common diagnosis was mucinous cystadenocarcinoma (Figure 2) and serous cystadenoma which constituted three cases each. The remaining cases were serous cystadenocarcinoma (02 cases), mucinous cystadenoma (01 case), haemorrhagic cyst (01 case) and tuberculosis (01 case). Out of eleven cases from ovary,

ten cases showed concordance with conventional histopathology diagnosis. In one discordant case, diagnosis of serous cystadenocarcinoma (malignant) was given on conventional histopathology which was reported as serous cystadenoma (benign) on frozen section; which constituted false negative diagnosis. This gave an accuracy rate of 90.90%.



**Figure 2: 10X view of rapid H&E stained slide of Frozen section and 10X view of routine H&E stained slide of Conventional histopathology section shows mucinous cystadenocarcinoma of ovary.**

**Thyroid** comprised nine cases of all frozen sections. Out of nine cases, goiter was diagnosed in four cases, papillary carcinoma in three cases and thyroiditis, follicular adenoma in one case each. All the nine cases from thyroid showed concordance with conventional histopathology diagnosis. This gave an accuracy rate of 100%.

**Gastrointestinal tract** comprised six cases; two from colon and one each from stomach, rectum, appendix and pancreas. The diagnosis adenocarcinoma was given in cases from stomach and colon while Gastrointestinal Stromal Tumor (GIST) and Mucocele were given respectively in rectum and appendix. The diagnosis of pancreas was deferred for the permanent section due to

inadequate material sent for frozen section. Out of six cases from GIT, the deferred case of pancreas was excluded from analysis. The remaining five cases showed 100% concordance with conventional histopathology diagnosis which gave an accuracy of 100%.

Statistical analysis was not carried out for specimens from tissues other than oral cavity, breast, brain, ovary, lymph nodes, thyroid and GIT because of small numbers of specimen in each group. Frozen section diagnosis from all these cases showed 100% concordance with conventional histopathology diagnosis.

Out of 99 cases, the diagnosis of 96 cases was concordant with conventional histopathology diagnosis while three

were discordant. This gave overall accuracy rate of 96.96% and discordant rate of 3.04%. The overall sensitivity and specificity was 97.22% and 96.30%. The positive predictive and negative predictive value was 98.59% and 92.86% respectively. Out of three discordant diagnoses one was false positive and two were false negative (False positive rate- 1.02% and False negative rate-2.02%).

We also evaluated the accuracy of frozen section according to the anatomic site, which is shown in Table 1.

**Table 1: Organ wise accuracy of frozen section.**

Anatomical site/Organ	Number of cases	Concordant cases	Discordant cases	Accuracy
Oral cavity	23	23	00	100%
Breast	16	15	01	93.75%
CNS	12	11	01	91.66%
Ovary	11	10	01	90.90%
Lymph node	11	11	00	100%
Thyroid	09	09	00	100%
GIT	05	05	00	100%
Skin and adnexa	04	04	00	100%
Soft tissue	02	02	00	100%
Uterus	01	01	00	100%
Testis	01	01	00	100%
Penis	01	01	00	100%
Miscellaneous	03	03	00	100%
Total	99	96	03	96.96%

The average turn-around time for diagnosis of frozen section in our study was 18 minutes. The turn-around time included the time from the receipt of specimen to interpretation communicated to the surgeon with exclusion of transport time prior to receipt of specimen by laboratory.

## DISCUSSION

Frozen section is generally considered an accurate and reliable mode of diagnosis to assist the surgeon on the surgical procedure performed during the surgery itself. However, it is costly and technically limited; and thus available only in major hospitals that house sufficient staff who have the technical knowledge, skill and adequate equipment to perform the service. Frozen section is also more difficult to interpret than examination of paraffin-embedded sections. The procedure itself, even in the best hands of the medical laboratory technician, makes the lesion appear worse than a paraffin section of the fixed tissue would. Thus, a good and competent pathologist should know what to expect, what to look for and make a reasonable conclusion without being overtly "clever".<sup>3</sup>

The organ wise accuracy of frozen section ranged from 90.90% in ovary to 100% in oral cavity, lymph nodes, thyroid and GIT.

The cause of error in the three discordant cases was:

1. Interpretation error- 66.66% (01 from brain and 01 from breast)
2. Gross sampling error-33.34% (01 from ovary).

A general diagnosis rather than an exact diagnosis should be given to assist the surgeon to proceed in choosing the best therapeutic approach for his patient. The frozen diagnosis can be fairly commented as inflammatory, benign or malignant rather than giving exact subtype, which hardly alter the diagnostic modality.<sup>4</sup>

The pathologist should also know the limitations of frozen section, the ability of his or her technicians in the respective laboratory. The Pathologist should not be afraid to defer in his or her diagnosis when the situation warrants it. Whenever a deferred diagnosis is made, it should be ignored and the surgeon should proceed as though the frozen section had never been performed.<sup>3</sup>

The overall accuracy of frozen section diagnosis reported in the literature varies from 92% to 97.98%.<sup>5,6,7</sup> Our study shows an accuracy rate of 96.96%. This falls within the range reported. The sensitivity of frozen section reported in various studies ranges from 84.6% to 97.98%.<sup>6,7,8</sup> We observed sensitivity of 97.23%, which is within the range. The reported specificity of frozen section in literature ranges from 94.55% to 100%.<sup>6,7,8</sup> We reported the specificity of 96.30%, which is also within the range.

When we compared the overall accuracy of frozen section with other studies from India and different parts of the world, we observed the results as shown below in table 2.

Out of 100 cases subjected for frozen section, 01 case from pancreas was deferred for the permanent section due to inadequate material sent for frozen section diagnosis.

This gave the deferral rate of 01%. Various studies have reported deferral rate ranging from 0.65% to 06%. The most common reasons for higher deferral rate are inexperienced pathologist, sampling mistake by surgeon, technical imperfection during section cutting, poor staining quality and lack of clinical information about the case.<sup>3,7</sup>

**Table 2: Comparison of various studies with present study on overall accuracy, sensitivity and specificity.**

Sr. No.	Name of Study	Country	Study Period	No. of cases	Accuracy	Sensitivity	Specificity
01.	Junn-Liang et al. <sup>5</sup>	China	01 Year	1084	97.7%	96.16%	99.43%
02.	Farah-Klibi F. et al. <sup>6</sup>	France	03 Years	1207	97.5%	84.6%	99.8%
03.	Shrestha S. et al. <sup>7</sup>	India	05 Years	404	94.6%	94.56%	94.55%
04.	Fariba Abbasi et al. <sup>8</sup>	Iran	07 Years	200	96.5%	93.1%	97.7%
05.	Peter J. H. et al. <sup>9</sup>	North America	01 Year	1952	96.5%	-	-
06.	Chandramouleeswari K. et al. <sup>10</sup>	India	01 Year	51	92%	-	-
07.	Present study	India	02 Years	100	96.96%	97.23%	96.30%

Interpretation error was the most common error in our study which constituted 66.66% while gross sampling error constituted 33.34%. There was no clinically significant error due to sectioning, staining and technical imperfection in our study. The type of error varies in each study depending upon the method used for freezing, type of specimens most commonly received, type of procedure adopted and focal nature of the lesion.<sup>3</sup>

The case of phyllodes diagnosed as benign turned to be malignant on conventional histopathology. Phyllodes tumor tend to have a spectrum of neoplastic behavior which ranges from benign, borderline to malignant. Histopathological diagnosis of phyllodes is based on stromal cellularity rather than individual cells. As the frozen section tends to alter the cell and stromal architecture, the pathologist always has difficulty in diagnosis. Thus the frozen section tend to amplify diagnostic dilemma which even in conventional histopathology difficult to distinguish benign and malignant behavior of phyllodes tumor.

In one case, choroid plexus carcinoma reported on frozen section turned out to be choroid plexus papilloma on conventional paraffin section. The erroneous diagnosis attributed to interpretation error by pathologist which is the most common type of error while reporting frozen section slides. Soft and edematous nature of neurosurgical specimens, freezing artifact, blotted cell morphology alters the cellular and nuclear morphology leading to misinterpretation by pathologist. The interpretation error was partly due to technical imperfection in this case. Another most important source of error is the experience of the pathologist dealing with

neurosurgery specimens and relative infrequency of CNS lesions like choroid plexus neoplasm.<sup>11</sup>

One case from ovary, reported as serous cystadenoma on frozen section turned out to be a serous cystadenocarcinoma. The cause for this false negative diagnosis was gross sampling error. In this, due to the focal nature of lesion; despite cutting sections from several frozen blocks, diagnostic area was not present in the blocks submitted for frozen section. Eventually the true nature of lesion was revealed on conventional histopathology after through sampling of the specimen.

The average turn-around time required for entire frozen section procedure varies from 20 to 25 minutes.<sup>12</sup> The average turn-around time observed in the present study is 18 minutes, which is comparable with the range reported by other studies.

The reason for shorter turn-around time of present study are- i) Frozen section room in the centre of operation theater complex ii) Expertise of pathologist, iii) Well trained technicians iv) Availability of Picture Archiving and Communication System (PACS) within the frozen section room which is essential for knowing the clinical history of the case and easy access to radiological and other clinico-pathological reports v) Good interdepartmental communication.

## CONCLUSIONS

The frozen section is an accurate and reliable method when it is used for tumor resection margins, metastasis of lymph nodes, and tissue recognition.

The pathologist should obtain more clinical information and make himself or herself available for intra-operative observation to appreciate the clinical situation.

In clinically suspected malignancy, more than one sample must be examined in order to decrease the false-negative diagnosis on frozen section.

Methodological gross/macrosopic examination, accurate sampling by pathologist, avoiding technical errors in sectioning and staining, a interpersonal coordination with the operating surgeon can reduce the limitation and provide rapid, reliable and cost effective details necessary for rapid diagnosis and on table patient management.

Continuous monitoring should be performed in every pathology department, to recognize the reasons of errors and, if possible, to reduce them and improve frozen section turn-around time.

*Funding: No funding sources*

*Conflict of interest: None declared*

*Ethical approval: The study was approved by the institutional ethics committee*

## REFERENCES

1. Jaafar H. Intra-operative frozen section consultation: concepts, applications and limitations. *Malays J Med Sci.* 2006;13(1):4-12.
2. Raab SS, Tworek JA, Souers R, Zarbo RJ. The value of monitoring frozen section-permanent section correlation data over time. *Arch Pathol Lab Med.* 2006;130(3):337-42.
3. Khoo JJ. An audit of intraoperative frozen section in Johor. *Med J Malaysia.* 2004;59(1):50-5.
4. Taxy JB. Frozen section and the surgical pathologist: a point of view. *Arch Pathol Lab Med.* 2009;133(7):1135-8.
5. Chang J-L, Tseng H-H, Sheu L-F, Lee W-H, Tu Y-C. Diagnostic Accuracy of Frozen Sections in Surgical Pathology-A Retrospective Analysis of 1084 Frozen Sections. *Journal of Medical Sciences.* 1992;13(2):133-42.
6. Farah-Klibi F, Neji O, Ferjaoui M, Zaouche A, Koubaa A, Sfar R, et al. Accuracy of frozen section diagnosis: an analysis of 1695 consecutive cases. *Tunis Med.* 2008;86(7):693-7.
7. Shrestha S, Lee MC, Dhakal H, Pun CB, Pradhan M, Shrestha S, et al. Comparative Study of Frozen Section Diagnoses with Histopathology. *Postgraduate Medical Journal of NAMS.* 2009;3(2):1-5.
8. Abbasi F, Yekta Z, Aryan A. Accuracy of Frozen Sections. *Iranian Journal of Pathology.* 2012;7(1): 3-8.
9. Howanitz PJ, Hoffman GG, Zarbo RJ. The accuracy of frozen-section diagnoses in 34 hospitals. *Arch Pathol Lab Med.* 1990;114(4):355-9.
10. Chandramouleeswari K, Yogambal M, Arunalatha P, Bose JC, Rajendran A. Frozen and paraffin sections- Comparative study highlighting the concordance and discordance rates in a tertiary care centre. *IOSR Journal of Dental and Medical Sciences.* 2013;12(5):26-30.
11. Ud Din N, Memon A, Idress R, Ahmad Z, Hasan S. Central nervous system lesions: correlation of intraoperative and final diagnoses, six year experience at a referral centre in a developing country, Pakistan. *Asian Pac J Cancer Prev.* 2011;12(6):1435-7.
12. Novis DA, Zarbo RJ. Interinstitutional comparison of frozen section turnaround time. A College of American Pathologists Q-Probes study of 32868 frozen sections in 700 hospitals. *Arch Pathol Lab Med.* 1997;121(6):559-67.

DOI: 10.5455/2320-6012.ijrms20150203

**Cite this article as:** Patil P, Shukla S, Bhake A, Hiwale K. Accuracy of frozen section analysis in correlation with surgical pathology diagnosis. *Int J Res Med Sci* 2015;3:399-404.