

## Research Article

# Morphological status of assimilated atlas vertebra with occipital bone and its clinical significance

Krishna Gopal<sup>1\*</sup>, Alok Kumar Choudhary<sup>1</sup>, Jolly Agarwal<sup>2</sup>, Sadakat Ali<sup>1</sup>

<sup>1</sup>Department of Anatomy, Shri Guru Ram Rai Institute of Medical and health Sciences (SGRRIM&HS), Dehradun, Uttarakhand, India

<sup>2</sup>Department of Anatomy, SRMSIMS, Bareilly, Uttar Pradesh, India

**Received:** 23 December 2014

**Accepted:** 6 January 2015

### \*Correspondence:

Dr. Krishna Gopal,

E-mail: drkrish2007@gmail.com

**Copyright:** © the author(s), publisher and licensee Medip Academy. This is an open-access article distributed under the terms of the Creative Commons Attribution Non-Commercial License, which permits unrestricted non-commercial use, distribution, and reproduction in any medium, provided the original work is properly cited.

## ABSTRACT

**Background:** Atlas is the first cervical vertebra. Sometimes there is partial or complete fusion of atlas with basal part of the occipital bone known as assimilation of atlas or atlanto-occipital fusion. It is normally congenital. It may be associated with the constriction of foramen magnum which may compress the spinal cord or brain stem.

**Methods:** The 1000 human dry skulls were selected from the anthropology museum of department of anatomy, GSVM medical college, Kanpur. The age and sex of the skulls were not taken into consideration. The skulls were examined for the bony union between the atlas and skull and other variations in assimilated atlas.

**Results:** Fused atlas with skull was seen in 20 skulls (2.0%). Partial fusion of anterior arch of atlas with the occipital bone was seen in 1 specimen (5%) and in 10% it was found complete fusion. In 10% skulls the posterior arch fused with the occipital bone. Bilateral fusion of transverse process with occipital bone was noted in 2 (10%) specimen. The incomplete foramen transversarium was found in 1 skull (5%) {bilateral} and in 2 skulls (10%), the transverse process was noted without the foramen transversarium {bilateral}.

**Conclusion:** Out of 1000 examined skulls, fusion of atlas with the occipital bone was noted in 20 skulls (2%). The knowledge of incidence of assimilation of atlas and its variations may be helpful for the embryologist, neurosurgeons and orthopedic surgeons.

**Keywords:** Atlas, Transverse process, Atlanto-occipital

## INTRODUCTION

Atlas is the first cervical vertebra. It does not have a body like other cervical vertebrae. It forms ellipsoidal synovial joints with the condyles of the occipital bone above and articulates with the axis vertebra below. It plays an important role in movement of the skull and the neck. Rarely, it gets fused with the basal part of the occipital bone (atlanto-occipital fusion). This condition is named as occipitalization of atlas/assimilation of atlas with occipital bone.<sup>1,2,4</sup> The atlas is normally formed by three primary ossification centres: one for each neural arch and one for the body. Failure of segmentation of the basal

occipital sclerotome and first spinal sclerotome lead to osseous fusion between the atlas and the occipital bone.<sup>3-5</sup> Macalister<sup>6</sup> reported that a midline defect can result from the failure of the ossification centres either anterior or posterior. Mac Rae et al.,<sup>7</sup> Al-Motabagani MA et al.<sup>8</sup> demonstrate that bony union between the atlas and the skull (occipitalization of atlas) usually involves the anterior arch, posterior arch, the lateral masses, the superior articular facets, transverse processes or entire atlas. The various complications with atlanto-occipital fusion/assimilation of atlas have reported by Gladstone et al.,<sup>9</sup> Green et al.,<sup>10</sup> Lanier et al.,<sup>11</sup> and Al-Motabagani et al.<sup>8</sup> R. Shane Tubbs et al.<sup>12</sup> stated that the occipitalisation

of atlas is normally congenital but in rare cases it may be the result of a disease such as osteomyelitis, arthritis, syphilis or tuberculosis.

Yochum TR et al.<sup>13</sup> explained this variations due to the developmental disorder. S. Nayak (2005)<sup>4</sup> observed that fusion of the atlas with the occipital bone, also called assimilation atlas. He reported that the individuals with occipitalization of atlas may cause low hairline torticollis, restricted neck movement and or abnormal short neck. R. Shane Tubbs et al. (2006)<sup>12</sup> & Ranadev AV et al. (2007)<sup>2</sup> explained that constriction of foramen magnum also associated with occipitalization of atlas which may compress the spinal cord or brain stem.

Mayhew IG et al (1978),<sup>14</sup> Van Nie CJ et al. (1977)<sup>15</sup> reported the incidence of atlanto-occipital fusion in animals such as the horse, dog and sheep. Rarely occipitalization of atlas may compress the vertebral artery and produce a series of disorder such as headache, vertigo, paralysis of the extremities.<sup>12</sup>

These congenital anomalies have clinical importance because of risk of compression of 1<sup>st</sup> cervical nerve and the vertebral artery.<sup>13</sup> There is not much attention to atlanto-occipital fusion in the anatomy text books and in the research fields. The aim of our study was to observe the incidence of fusion of atlas to occipital bone in order to contribute awareness of this condition. The knowledge of variations in the foramen transversarium observed in present study is important to the understanding and diagnosis of pathological conditions related to the vertebral artery and its sympathetic plexus.

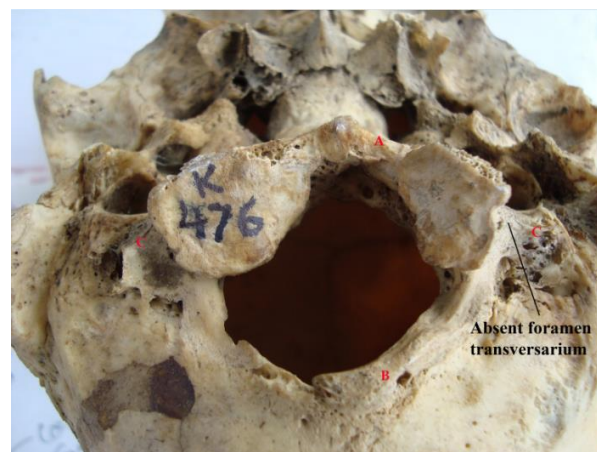## METHODS

The present study is based on the observation 1000 dry human skulls, belonging to North India, present in the anthropology museum of department of anatomy, GSVM medical college, Kanpur.

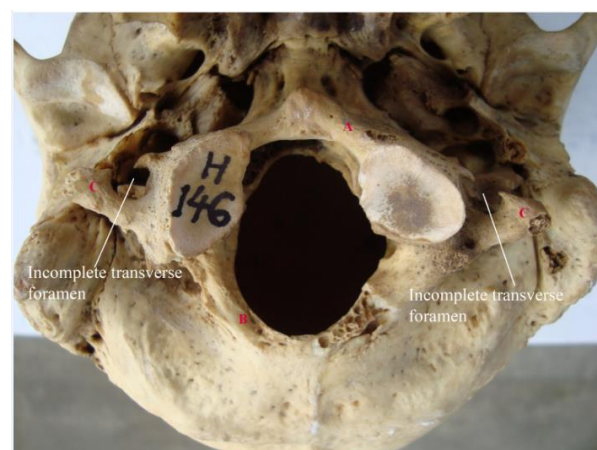
The macerated skulls were randomly selected. The age and sex of the skulls were not taken into consideration. The skulls were cleaned properly and examined for the bony union between the atlas and the skull/assimilation of atlas vertebra with the occipital bone.

We observed for fusion of superior articular facets of atlas with occipital condyles and also noted the status of anterior arch, posterior arch, lateral masses, transverse processes, or entire atlas.

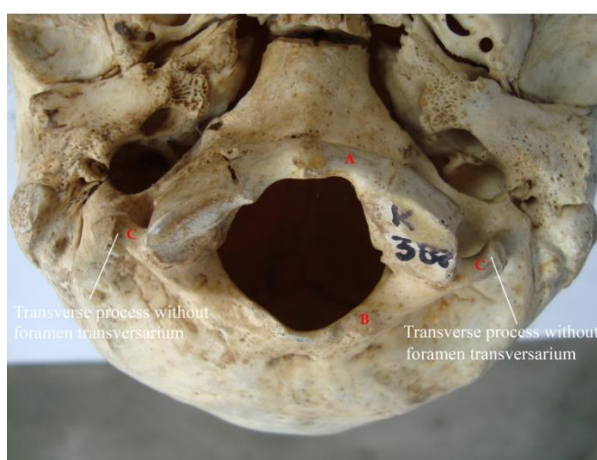
We also observed and recorded the malformed foramen transversarium, its anterior and posterior bar or absent of it in the assimilated atlas vertebra. All these non-metric variants were carefully noted in observation table and inference were made from them. The photographs of inferior view of skulls were taken with the help of digital camera.



**Figure 1: Fusion of atlas with occipital bone. A) Fused anterior arch B) Fused posterior arch C) Bilateral fusion of transverse process without foremen transversarium.**



**Figure 2: Fusion of atlas with occipital bone. Bilateral incomplete transverse foremen. A) Fusion of left part of anterior arch of atlas B) Fusion of posterior arch C) Transverse process.**



**Figure 3: Fusion of atlas with occipital bone. A) Anterior arch B) Posterior arch C) Transverse process without foremen transversarium (Bilateral).**

## RESULTS

The 1000 macerated human skulls belonging to the state of North India were observed. The incidence of assimilation of atlas was seen in 20 skulls (2.0%). In all the cases superior articular facets were fused with occipital condyles. Out of the 20 skulls the incidence of partial fusion (left half) of anterior arch of atlas with the basal part of occipital bone was found in 1 specimen

(5%) and in 10% it was found complete fusion. In 2 (10%) skulls the posterior arch fused with the occipital bone. Out of the 20 skulls the bilateral fusion of transverse process with occipital bone were noted in 2 (10%) specimen. The bilateral incomplete foramen transversarium was found in 1 skull (5%) and in 2 skulls (10%), the transverse process was noted without the foramen transversarium (bilaterally).

**Table 1: Incidence of various parameters of atlas, fused with skull in present study.**

No. of skull (atlanto-occipital fusion)	Anterior arch fusion	Posterior arch fusion	Fused transverse process (Tr. process) bilaterally	Bilateral incomplete transverse foramen (bilateral)	Tr. process without transverse foramen (bilateral)
20 (2%)	10% (complete) 5% (only left part)	10%	10%	5%	10%

## DISCUSSION

Fusion of atlas with the occipital bone is an osseous anomaly of the craniovertebral junction. R. Shane Tubbs et al.<sup>12</sup> explain that the occipitalization of atlas is normally congenital but in rare cases it may be the result of a disease such as osteomyelitis, arthritis, syphilis or tuberculosis. The incidence of atlanto-occipital fusion varies from 0.32% to 2.85%. (Table 2). Yochum TR<sup>13</sup> reported the incidence of atlanto-occipital fusion ranges from 0.14% to 0.75%. Jayanthi V (2003)<sup>1</sup> reported the incidence of occipitalization of atlas in 2 cases with spina bifida he also reported the unilateral fusion of transverse process with occipital bone along with the partial anterior arch fusion with the basilar part of occipital bone in one skull and complete anterior arch fusion in other skull. S. Nayak (2005)<sup>4</sup> observed that fusion of the atlas with the occipital bone, so called atlas assimilation in 1% of cases. He reported that the individuals with occipitalization of atlas may cause low hairline torticollis, restricted neck movement and or abnormal short neck. R. Shane tubbs<sup>12</sup> found the five adult human cranium in which occipitalization of atlas was found. In their observation they found that constriction of foramen magnum also associated with occipitalization of atlas in all of 5 cases. In a series of 214 South African skeletons, Taiz C (2000)<sup>16</sup> identified two specimens with occipitalization of atlas. Lang J. (1986)<sup>17</sup> stated that this phenomenon (occipitalization of atlas) occurs in between 0.1-0.8% of population. Mayhew IG,<sup>14</sup> Van Nie CJ et al.<sup>15</sup> reported the incidence of atlanto-occipital fusion in animals such as the horse, dog and sheep. The present study was based on human skulls; discussions regarding animals still remain inadequate. Bergnan P. (1967)<sup>18</sup> reported that the atlas may be fused with the occipital bone in varying degree. The assimilation of atlas with occipital bone may occur in about 0.5-1.0% skulls. Smith and Tuan (1994)<sup>19</sup> described fusion of atlas with occipital bone had a genetic basis but the present study is

inadequate to comment upon genetic basis of occipitalization of atlas. Ranade AV et al.<sup>2</sup> reported incidence of assimilation of atlas in 2% Indian population. Vineeta Saini et al.<sup>20</sup> observed 126 human skulls and recorded the incidence of occipitalization of atlas only in two skulls (1.59%) specimens. She also reported the fusion of anterior arch, posterior arch, left side incomplete and right side absent foramen transversarium in one skull and in the other skull she reported fusion of left part of anterior arch, posterior arch with the occipital bone and also left sided assimilation of transverse process with occiput. Al-Motabagani MA et al. 2006<sup>8</sup> reported occipitalization of atlas in 0.92% skulls of Asian origin.

**Table 2: Incidence of fusion of atlas with occipital bone as reported in the literature.**

Authors	Total No. of observed skull	Total No. of skull fused with atlas	Percentage
AL-Motabagani MA <sup>8</sup>	109	1	0.91%
Ranade AV <sup>27</sup>	98	2	2.04%
Anu Vinod <sup>27</sup>	98	2	2.04%
M. Sharma <sup>21</sup>	70	2	2.85%
Vineeta Saini <sup>20</sup>	126	2	1.58%
Surekha Jadhav <sup>28</sup>	150	1	0.66%
K. Khamanarong <sup>22</sup>	633	2	0.32%
Present study	1000	2	2.0%

In our study the incidence of occipitalization of atlas was found in 20 skulls (2.0%) in Indian population (Table 1). The low percentages of incidences (0.14%-2.04%) recorded by other workers (Table 2) may be due to population, or material differences or may be due to low number of material. In all the skulls, the superior articular



facets of atlas were fused with occipital condyles in the same coronal plane. Out of the 20 skulls the incidence of fusion of left part of anterior arch of atlas with the basal part of occipital bone (basi-occiput) was found in the 1 specimen (5%) (Table 1/Figure 2). The same result was also recorded by Vineeta Saini et al.<sup>20</sup> In two cases (10%) it was found complete fusion of anterior arch with basal part of occipital bone (Table 1/Figure 1). In 2 (10%) skulls we observed the complete fusion of the posterior arch of atlas with the squamous part of the occipital bone (Table 1/Figure 1). The bilateral fusion of transverse process with occipital bone was noted in 2 (10%) specimen (Table 1/Figure 1). Bilateral incomplete developed costal element of foramen transversarium (anterior bar) was found in 5% of specimens and in 2 skulls (10%), the transverse processes were present without the foramen transversarium bilaterally (Table 1/Figure 2), which is not cited in the literature. The variations in the assimilation of observed skull is similar to the report given by M. Sharma,<sup>21</sup> K. Khamanarong<sup>22</sup> & Hussain S.<sup>23</sup> Atlanto-occipital fusion reduces the foramen magnum dimension leading to neurological complication due to compression of spinal cord.<sup>24</sup> These variants may produce a series of disorder such as headache, vertigo, paralysis of the extremities.<sup>27</sup> The knowledge of occipitalization of atlas may be of importance to orthopedic surgeons dealing with the pathologies of upper cervical spine. It may be the cause of a failure of a cisternal puncture and thus may be of importance for the anesthetist. The neurosurgeons dealing with the tumor of cerebellum also be aware of this occipitalization of atlas vertebra.

## CONCLUSION

We studied 1000 skulls in which fusion of atlas with the occipital bone was noted in 20 skulls (2%). The absence of foramen transversarium was noticed in 10% cases which are not cited in the literature. Anterior incomplete foramen transversarium was found in 5% of specimen. Atlanto-occipital fusion reduces the foramen magnum dimension leading to neurological complication due to compression of spinal cord. These variants of the Atlas and skull may produce a series of disorder such as headache, vertigo, paralysis of the extremities. The knowledge of these variants may be helpful for the embryologist, neurosurgeons, anthropologists, and physiotherapist and also for the radiologists dealing with the abnormalities of the cervical spine.

## ACKNOWLEDGEMENTS

We sincerely thank the colleagues and staff of the anatomy department for their helpful assistance.

*Funding: No funding sources*

*Conflict of interest: None declared*

*Ethical approval: The study was approved by the institutional ethics committee*

## REFERENCES

- Jayanthi V, Kulkarni R. Atlanto-occipital fusion. Report of two cases. J Anat Soc India. 2003;52(I):71-3.
- Ranade AV, Rai R, Prabhu LV, Kumaran M, Pai MM. Atlas assimilation: a case report. Neuroanatomy. 2007;6:32-3.
- Goel A, Sharma P, Dange N, Kulkarni AG. Techniques in the treatment of craniovertebral instability. Neurol India. 2005;53:525-33.
- Nayak S, Vollala V, Raghunathan D. Total fusion of atlas with occipital bone. Neuroanatomy. 2005;4:39-40.
- Ugar DA, Semb. The prevalence of anomalies of the upper cervical vertebrae in subjects with cleft lip, cleft palate, or both. Cleft Palate Craniofac J. 2001;38:498-503.
- Macalister A. Notes on the development and variations of the atlas. J Anat Physiol. 1893;27:519-42.
- McRae, Barnum AS. Occipitalisation of atlas. Am J Roentgen. 1953;70:23-46.
- AL-Motabagani MA, Surendra M. Total occipitalization of the atlas. Anat Sci Int. 2006;81:173-80.
- Gladstone RJ, Erichsen-Powel W. Manifestation of occipital vertebrae and fusion of atlas with the occipital bone. J Anat Phy. 1915;59:190-209.
- Green HLHH. An unusual case of atlanto-occipital fusion. J Anat. 1930;65:140-4.
- Lanier RR Jr. An anomalous Cervico-occipital skeleton in man. Anat Rec. 1939;73:189-201.
- Shane Tubbs R, Gearage Salter E, Jerry Oakes W. The intracranial entrance of the atlantal segment of the vertebral artery in crania with Occipitalisation of the atlas. Journal of neurosurgery. Spine. 2006 Apr;4:4.
- Yochum TR, Rowe LJ. Developmental disorder. In: Yochum TR, Rowe LJ, eds. Essentials of Skeletal Radiology. 2nd ed. Baltimore: William and Wilkins; 1987: 3.
- Mayhew IG, Watson AG, Heissan JA. Congenital occipitoatlanto axial malformation in the horse. Equine Vet J. 1978;10:103-13.
- Van Nie CJ, Folkerts, JF. Occipitalisation of the atlas in a sheep. Acta Morphol Neere Scand. 1977;15:325.
- Taitz C. Bony observation of some morphological variation and anomalies of the cranio-vertebral region. Clin Anat. 2000;13:354-60.
- Lang J. Craniocervical region osteology and articulation. Neuro-orthopedics. 1986;1:67-92.
- Bergman P. Varieties of atlas in man. Folio Morphol Warsaw. 1967;26:129-39.
- Smith CA, Tuan RS. Human PAX gene expression and development of vertebral column. Clin Orthop Relat Res. 1994;302:241-50.
- Vineeta Saini, Royana Singh, Manimay Bandopadhyay, Sunil Kumar Tripathi, Satya

- Narayan Shamal. Occipitalization of atlas: its occurrence and embryological basis. *Int J Anat Variat.* 2008;2:85-8.
21. Sharma M, Singh B, Abhaya A, Kumar H. Occipitalization of atlas with other associated anomalies of skull. *Eur J Anat.* 2008;12(3):159-67.
  22. Kimaporn Khamanarong, Worawut Woraputtaporn, Somsiri Ratanasuwan, Malivalaya Namking, Wunnee Chaijaroonkhanarak, Surachai Sae-Jung. Occipitalization of the atlas: its incidence and clinical implications. *Acta Medica Academica.* 2013;42(1):41-5.
  23. Hussain Saheb S, Mavishetter GF, Thomos ST, Prasanna LC, Muralidhar P. Occipitalization of atlas: a case report. *J Biomed Sci Res.* 2010;2(2):73-5.
  24. Satheesha Nayak. Asymmetric atlas assimilation and potential danger to the brainstem: a case report. *Int J Biol Anthropol.* 2008;1(2):4.
  25. Gholve PA, Hosalkar HS, Ricchetti ET, Pollock AN, Dormans JP, Drummond DS. Occipitalization of the atlas in children. Morphologic classification, associations, and clinical relevance. *J Bone Joint Surg Am.* 2007;89(3):571-8.
  26. Gholve PA, Hosalkar HS, Ricchetti ET, Pollock AN, Dormans JP, Drummond DS. Occipitalization of the atlas in children. Morphologic classification, associations, and clinical relevance. *J Bone Joint Surg Am.* 2007;89(3):571-8.
  27. Anu Vinod Ranade, Rajalakshmi Rai, Latha Venkatraya Prabhu, Mangala Kumaran, Mangala M. Pai. Atlas assimilation: a case report. *Neuroanatomy.* 2007;6:32-8.
  28. Surekha Jadhav, Manoj Ambali, Raosaheb Patil, Megha Doshi, Priya Roy. Assimilation of atlas in Indian dry skulls. *J Krishna Inst Med Sci Univ. (JKIMSU).* 2012;1:102-6.

DOI: 10.5455/2320-6012.ijrms20150207

**Cite this article as:** Gopal K, Choudhary AK, Agarwal J, Ali S. Morphological status of assimilated atlas vertebra with occipital bone and its clinical significance. *Int J Res Med Sci* 2015;3:420-4.