

Case Report

Pulmonary blastomycosis on autopsy: a rare case report

Shweta Rana*, Puja Sharma, Rahul N. Satarkar, Shivani Kalhan, Shilpa Garg

Department of Pathology, SHKM, GMC, Nalhar, Mewat, Haryana, India

Received: 20 December 2014

Accepted: 15 January 2015

***Correspondence:**

Dr. Shweta Rana,

E-mail: drshwetarana15@gmail.com

Copyright: © the author(s), publisher and licensee Medip Academy. This is an open-access article distributed under the terms of the Creative Commons Attribution Non-Commercial License, which permits unrestricted non-commercial use, distribution, and reproduction in any medium, provided the original work is properly cited.

ABSTRACT

A case of pulmonary blastomycosis on autopsy in a middle aged male from rural background is presented herewith. Blastomycosis is a pyogranulomatous disease caused by the dimorphic fungus *blastomyces dermatitidis*. Blastomycosis is endemic in regions of North America that border the Great Lakes. It is one of the great mimickers in medicine. Pulmonary blastomycosis has a broad range of clinical presentations, varying from completely asymptomatic pulmonary infiltrates to diffuse and massive parenchymal involvement that can lead to Acute Respiratory Distress Syndrome (ARDS). Human infection occurs when soil containing microfoci of mycelia is distributed and airborne conidia are inhaled. If natural defences in the alveoli fail to contain the infection, lymphohematogenous dissemination ensues. Diagnosis is based on culture and direct visualization of round, multinucleated yeast forms that produce daughter cells from a single broad-based bud. Most of the cases of blastomycosis reported in India are imported from the endemic areas of the World except a few autochthonous cases in North India.

Keywords: Autopsy, Blastomycosis, Pulmonary, Dimorphic fungi

INTRODUCTION

Blastomycosis is an uncommon, geographically restricted, pulmonary and systemic mycosis, caused by the thermally dimorphic fungus *blastomyces dermatitidis*.¹ The illness was previously called Gilchrist's disease in the honour of the man who first recognized it in Baltimore in 1895. Blastomycosis is predominantly a disease of North America. It is endemic in the southern and south-eastern states that border the Ohio and Mississippi river valleys of the United States as well as mid-western states and Canadian provinces that border the great lakes and the Saint Lawrence river way.² *Blastomyces* has also been described in Africa.³ In India, autochthonous cases of blastomycosis in humans have been reported mainly from the states of Uttar Pradesh and Madhya Pradesh in northern and central India respectively.^{4,5} Most other cases of blastomycosis have been imported cases acquired through travel to endemic

areas in U.S.A.^{1,6} There is a strong possibility that blastomycosis is endemic in India but its epidemiology and ecology in India is yet to be studied in detail. Our case report of pulmonary blastomycosis on autopsy of a middle aged man of rural background further strengthens this possibility. There is no mention of pulmonary blastomycosis on autopsy in India in the literature.

CASE REPORT

We received viscera of a 40 years old male from rural background found dead besides railway tracks near his village in Haryana, North India for post-mortem analysis. No external injuries were found on the body. His relatives did not suspect any foul play and gave history that the deceased maintained poor health since many years and was a chronic smoker. His immune status was not known. We received pieces of both the lungs along with other viscera (brain, heart, liver, spleen and kidney). Grossly,

cut surface of both the lung pieces showed patchy consolidation of parenchyma and numerous small firm grey white nodules scattered throughout. Microsections from pieces of left and right lungs showed focally hemorrhagic necrotizing pneumonia. The alveoli and interstitium were filled with yeast forms of Blastomycosis and acute inflammatory cells. The organism was present both intracellularly and extracellularly. Few giant cells and ill-defined granuloma formation were also seen. The yeast forms were rounded to oval, 8-15 μm in diameter, with broad base budding and a double contour cell wall. The thick, refractile cell walls were easily seen in tissue sections stained with hematoxylin and eosin. Occasional hyphal forms were also seen (Figure 1a, 1b, 1c & 1d). Periodic Acid Schiff's (PAS) and Gomori Methenamine Silver (GMS) stains also provided excellent contrast (Figure 2a and 2b). The other viscera submitted were unremarkable on histopathology.

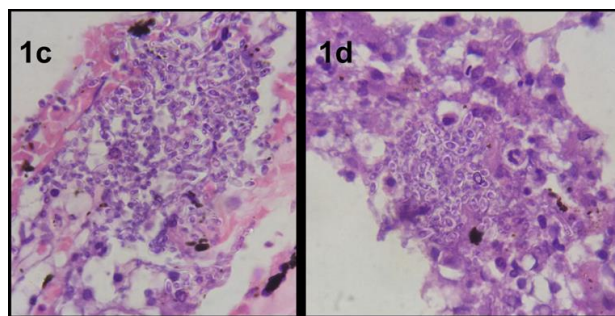


Figure 1c & 1d: Microphotographs show round to oval yeast forms, 8-15 μm with double contour cell walls and broad based budding (H&E; 1000x).

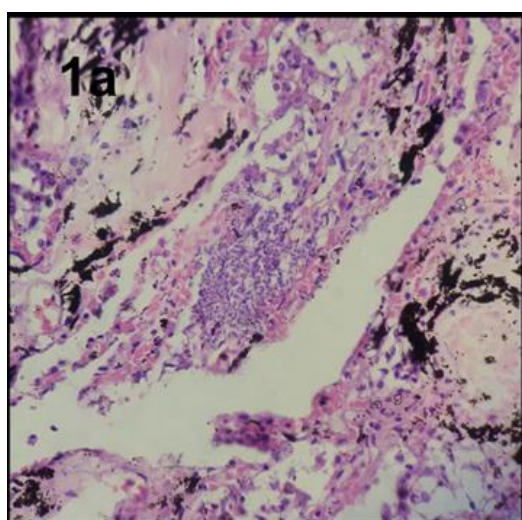


Figure 1a: Microphotograph shows cluster of yeast forms of *B. dermatitidis* (H&E; 100x).

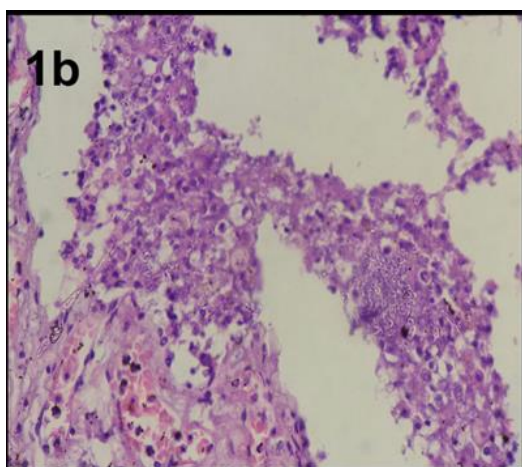


Figure 1b: Microphotograph shows yeast forms of *B. dermatitidis* clustered within a microabscess. Occasional hyphal forms also seen (H&E; 400x).

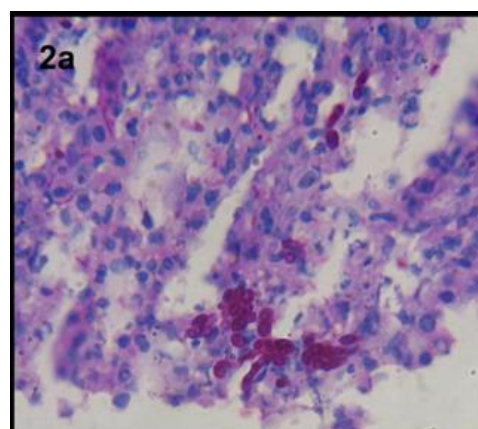


Figure 2a: Microphotograph shows budding yeast forms of *B. dermatitidis* (PAS stain; 1000x).

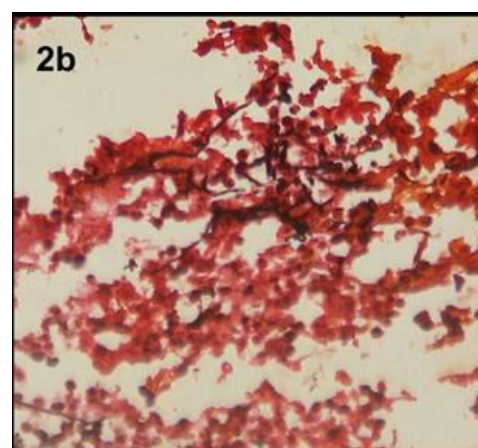


Figure 2b: Microphotograph shows budding yeast forms and hyphal forms of *B. dermatitidis* (GMS stain; 1000x).

DISCUSSION

B. dermatitidis is a dimorphic fungus. The mycelial form is found in warm moist soil, rich in organic debris. Disruption of the soil is probably necessary for spore (conidia) aerosolization and dissemination. After inhalation and incubation at body temperature, the spores

transform into the pathogenic yeast forms and cause a local pyogranulomatous reaction.⁷ In the lung, the phagocytic actions of alveolar macrophages, neutrophils and monocytes provide natural resistance to infection with conidia of *B. dermatitidis*. The yeast form possesses a thick capsule and is very difficult for phagocytes to ingest and kill.⁸ Proliferation of yeast forms in the alveoli signals the failure of natural resistance to *B. dermatitidis*. The pyogranulomatous response seen in blastomycosis and the presence of yeast cells inside or in contact with monocytes, macrophages and giant cells suggest a potent cellular immune response.⁹

Pulmonary blastomycosis presents clinically as a flu like illness, acute pneumonia, chronic pneumonia or as a rapidly progressive respiratory distress syndrome.^{9,10} Fever, chills and productive cough, with or without hemoptysis, characterize acute pneumonia. An illness lasting for 2 to 6 months with weight loss, fever, night sweats, cough with sputum and chest pain typifies chronic pneumonia.⁹ Mass like pulmonary infiltrates may be seen in chronic pneumonia.¹¹

Miliary blastomycosis or endobronchial spread of infection can cause the adult respiratory distress syndrome (ARDS) with diffuse bilateral pulmonary infiltrates and non-cardiogenic pulmonary edema.¹² ARDS caused by pulmonary blastomycosis is associated with high mortality.¹³ In a series from Mississippi, 9 of 107 patients with pulmonary blastomycosis had ARDS; 78% of these died.¹² When blastomycosis does occur in immunocompromised patients, the disease is more aggressive than in immunocompetent hosts. In one series, 30% of patients died of blastomycosis, disseminated disease and involvement of the CNS were relatively common.¹⁴ According to Meyer et al.,¹³ 6 out of 10 patients in their series revealed diffuse pyogranulomatous inflammation with massive infiltration of alveolar spaces by large number of *B. dermatitidis* organisms. Hyaline membranes consistent with the presence of ARDS were also seen in lung specimens of these patients.

No clinical or radiographic abnormalities are pathognomonic of blastomycosis. The spectrum of disease that *B. dermatitidis* causes overlaps with those of other fungal pathogens and malignancy, and the clinical picture may be indistinguishable from tuberculosis. Therefore, visualization of characteristic yeast forms or growth of the fungus in culture is necessary to diagnose blastomycosis definitely.² Schwarz et al.¹⁵ in a review of 152 cases of blastomycosis noted a wide variation in the morphology of blastomyces including size, shape, staining and wall thickness with variation in different fields of same specimen. It was noted in the review that the number of organisms varied greatly. Cases with large number of organisms showed the greatest variation in morphology within the same specimen.

For mild to moderate cases of non-disseminated pulmonary blastomycosis in immunocompetent patients,

the 2008 updated clinical practice guidelines recommend a 6-12 month course of oral itraconazole. For more severe cases, a 1-2-week course of intravenous lipid amphotericin B prior to itraconazole is recommended.¹⁶ Broad-spectrum azoles, like voriconazole or posaconazole, could also be used in this context.¹⁷

CONCLUSION

As there is scarcity of published data on blastomycosis in India, its epidemiology needs to be studied in detail and clinicians must be aware of this condition, its predisposing factors, newer diagnostic modalities, variation in morphologic forms and treatment. The present case highlights that blastomycosis is extremely rare in India but not unknown.

Funding: No funding sources

Conflict of interest: None declared

Ethical approval: Not required

REFERENCES

1. Randhawa HS, Chowdhary A, Kathuria S, Roy P, Misra SD, Jain S, et al. Blastomycosis in India: report of an imported case and current status. *Med Mycol.* 2013;51(2):185-92.
2. Saccante M, Woods GL. Clinical and laboratory update on blastomycosis. *Clin Microbiol Rev.* 2010;23:367-81.
3. Baily GG, Robertson VJ, Neill P, Garrido P, Levy LF. Blastomycosis in Africa: clinical features, diagnosis and treatment. *Rev Infect Dis.* 1991;13(5):1005-8.
4. Randhawa HS, Khan ZU, Gaur SN. Blastomycosis dermatitidis in India: first report of its isolation from clinical material. *Sabouraudia.* 1983;21:215-21.
5. Jambhekar NA, Shrikhande SS, Advani SH, Rao RS. Disseminated blastomycosis: a case report. *Indian J Pathol Microbiol.* 1988;31:330-3.
6. Savio J, Muralidharan S, Macaden RS, D'Souza G, Mysore S, Ramachandran P, et al. Blastomycosis in a South India patient after visiting an endemic area in USA. *Med Mycol.* 2006;44:523-9.
7. Kralt D, Light B, Cheang M, Mac Nair T, Wiebe L, Limerick B, et al. Clinical characteristics and outcomes in patients with pulmonary blastomycosis. *Mycopathology.* 2009;167:115-24.
8. Drutz DJ, Frey CL. Intracellular and extracellular defences against blastomyces dermatitidis conidia and yeasts. *J Lab Clin Med.* 1985;105(6):737-50.
9. Bradsher RW. Blastomycosis. *Infect Dis Clin North Am.* 1988;2(4):877-98.
10. Sarosi GA, Davies SF, Phillips JR. Self-limited blastomycosis: a report of 39 cases. *Semin Respir Infect.* 1986;1(1):40-4.
11. Patel RG, Patel B, Petrini MF, Carter RR, Griffith J. Clinical presentation, radiographic findings and diagnostic methods of pulmonary blastomycosis: a

- review of 100 consecutive cases. *South Med J.* 1999;92(3):289-95.
12. Lemos LB, Baliga M, Guo M. Acute respiratory distress syndrome and blastomycosis: presentation of 9 cases and review of literature. *Ann Diagn Pathol.* 2001;5(1):1-9.
 13. Meyer KC, McManus EJ, Maki DG. Overwhelming pulmonary blastomycosis associated with the adult respiratory distress syndrome. *N Engl J Med.* 1993;329(17):1231-6.
 14. Pappas PG, Threlkeld MG, Bedsole GD, Cleveland KO, Gelfand MS, Dismukes WE. Blastomycosis in immunocompromised patients. *Medicine.* 1993;72:311-25.
 15. Schwarz J, Salfelderk. Blastomycosis: a review of 152 cases. *Curr Top Pathol.* 1977;65:165-200.
 16. Chapman SW, Dismukes WE, Proia LA, Bradsher RW, Pappas PG, Threlkeld MG, et al. Clinical practice guidelines for the management of blastomycosis: 2008 update by the infectious diseases society of America. *Clin Infect Dis.* 2008;46:1801-12.
 17. Bariola JR, Perry P, Pappas PG, Proia L, Shealey W, Wright PW, et al. Blastomycosis of the central nervous system: a multicenter review of diagnosis and treatment in the modern era. *Clin Infect Dis.* 2010;50:797-804.

DOI: 10.5455/2320-6012.ijrms20150223

Cite this article as: Rana S, Sharma P, Satarkar RN, Kalhan S, Garg S. Pulmonary blastomycosis on autopsy: a rare case report. *Int J Res Med Sci* 2015;3:498-501.