

Case Report

Amyand's hernia: an uncommon entity

Jorge Silva-Zamora^{1*}, Arturo Romero Macias¹, Luis A. Baigts Arriola¹,
Cristian A. Dámazo Escobedo¹, Adriana G. Vizcarra Rendón², Jose G. Sevilla Flores¹

¹Department of General Surgery, Hospital Regional Lic. Adolfo López Mateos, Ciudad de México, México

²Department of Radiology, Hospital Regional Lic. Adolfo López Mateos, Ciudad de México, México

Received: 24 January 2024

Revised: 05 March 2024

Accepted: 16 March 2024

*Correspondence:

Dr. Jorge Silva-Zamora,

E-mail: jorge.silzam@gmail.com

Copyright: © the author(s), publisher and licensee Medip Academy. This is an open-access article distributed under the terms of the Creative Commons Attribution Non-Commercial License, which permits unrestricted non-commercial use, distribution, and reproduction in any medium, provided the original work is properly cited.

ABSTRACT

A 60-year-old male case whose condition began 6 months prior to admission to the emergency department, presenting an increase in volume in the right inguinal region, with intermittent pain, colic type, with an intensity rating of 8-10/10. On physical examination we found increased volume in the right inguinal region when standing, tumor measuring approximately 5x5 cm, hernia defect approximately 4 cm in diameter, non-painful and reducible. Patient was diagnosed clinically as direct right inguinal hernia and ultrasound confirmed the diagnosis with the presence of the appendix in the sac. A pre-operative diagnosis of right inguinal hernia was made and was planned for hernia mesh repair, during surgery under spinal blockage, the hernia sac was found to contain an appendix without signs of inflammation, so we decided to close the defect and repair with a Lichtenstein mesh hernioplasty without doing an appendectomy. In this case we treated a rare clinical entity called Amyand's hernia. This case highlights the importance of considering Amyand's hernia in the differential diagnosis of inguinal pathologies and the role of imaging modalities in pre-operative diagnosis. Various classification systems have been proposed, including those by Losanoff and Bason, later modified by Rikki et al offering insights into surgical management strategies based on the condition of the appendix and concomitant pathologies. Despite efforts to standardize treatment approaches, consensus on the optimal management strategy remains elusive, necessitating further research to refine diagnostic and therapeutic guidelines.

Keywords: Amyand's hernia, Appendicitis, Losanoff and Bason classification, Lichtenstein mesh hernioplasty

INTRODUCTION

The term 'Amyand's hernia' refers to a protrusion of the vermiform appendix within an inguinal hernia sac.¹ It received that name in honor of Claudius Amyand, a surgeon who described in December 6, 1735, the case of a 11-year-old boy with a fistula between the scrotum and thigh secondary to a perforated appendix containing in an inguinal hernia.² The incidence of Amyand's hernia varies between 0.19-1.7%, when is a concomitant acute appendicitis is even rarer, with an estimated rate at 0.07-0.13%; is more frequent in males and in children. The

rate of diagnosis of Amyand's hernia also has been reported to be 3 times higher in children than in adults due to failure of the processus vaginalis to obliterate during development.^{3,4}

Most of the time, is an incidental finding intra-operatively, and there is no consensus on the optimal operative management approach.^{5,6} The mortality rate is calculated in a range of 6-15% probably because of the delayed diagnosis.⁵⁻⁸ The pathophysiology of this clinical entity is still not well understood, however there is an important number of theories proposed.¹

CASE REPORT

60-year-old male, with only positive history of smoking, at a rate of 20 cigarettes a day for 40 years. The condition began 6 months prior to admission to the emergency department, presenting an increase in volume in the right inguinal region, with intermittent pain, colic type, with an intensity rating of 8-10/10 to be reported by the patient, without irradiation, triggered due to effort, without exacerbators, attenuated by self-medicated analgesia based on NSAIDs.

On physical examination we found an appearance consistent with age and sex, without characteristic facies, adequate mucotegumentary coloration, and normally hydrated oral mucosa. Flat, normoperistaltic abdomen, tympanism in a colonic setting, soft, depressible, not painful on medium or deep palpation without signs of peritoneal irritation, increased volume in the right inguinal region when standing, tumor measuring approximately 5x5 cm, hernia defect approximately 4 cm in diameter, non-painful and reducible.

Patient was diagnosed clinically as direct right inguinal hernia. Hematological workup was within normal limits. Ultrasound reported right inguinal region with adequate thickness and echogenicity of soft tissues; medial to the vessels, a wall defect of up to 36 mm is observed, where homogeneous echogenic tissue runs in relation to mesenteric fat, intestinal loops, which retain diameter and peristalsis (Figure 1), as well as presence of cecal appendix, which presents a diameter of up to 6 mm, with air content inside and after compression maneuvers presents complete collapse, after the application of color Doppler they present vascularity; Valsalva maneuvers are performed where protrusion of the already mentioned structures is observed, increasing the diameter up to 41 mm with spontaneous reduction. In USG we can observe ovoid structure with the appearance of concentric rings of alternating echogenicity that represent the appendicular signature with gas inside.

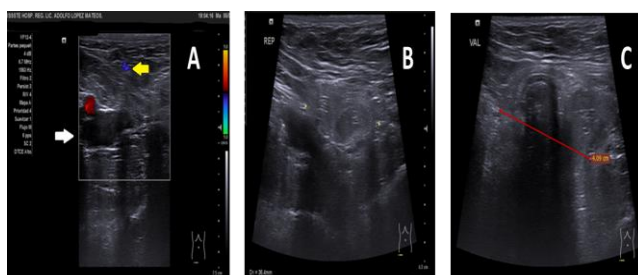


Figure 1: A) Right inguinal region: femoral vessels (white arrow) and right epigastric vessels (yellow arrow) are observed, in the middle of both echogenic image runs in relation to mesenteric fat, B) USG at rest at the level of the right inguinal region with defect of medial wall to the femoral vessels of up to 36mm which contains mesenteric fat, C) USG after Valsalva maneuver at the level of the right inguinal region.

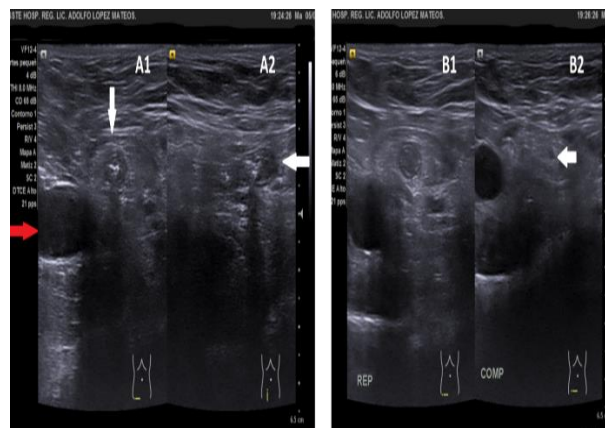


Figure 2: A1) In a cross-section medial to the femoral vessels (red arrow) is identified the appendicular signature with gas inside represented by echogenic images inside, A2) finding tubular image ending in blind sac fundus, with intestinal signature suggestive of vermiform appendix, B1) is observed a wall defect through which mesenteric fat and appendix run, B2) the appendix collapses after compression with the transducer (white arrow), a sign that suggests that it does not present inflammation.

A pre-operative diagnosis of right inguinal hernia was made and was planned for hernia mesh repair, during surgery under spinal blockage, the hernia sac was found to contain an appendix (Figure 3). The appendix was not inflamed (Figure 4), It was decided to face the borders of the hernial sac with absorbable suture and then placed back into the peritoneal cavity (Figure 5); finally, Lichtenstein mesh hernioplasty was done (Figure 6).

The post-operative period was uneventful. The patient post-operatively received fluid therapy, oral fluids were administered after 6 hours along with soft diet and was discharged on post-operative day 1 without antibiotic therapy.

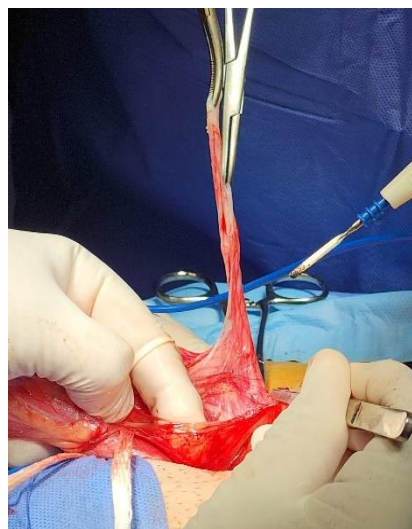


Figure 3: Hernia sac containing the appendix.

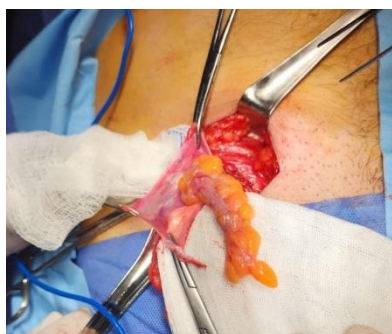

Figure 4: Appendix without signs of inflammation.

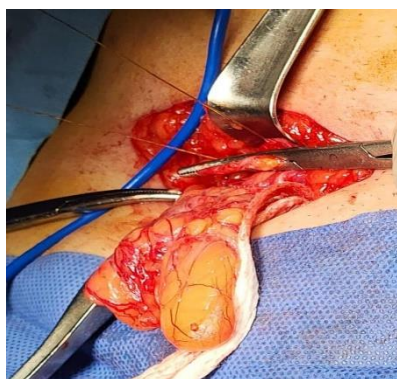

Figure 5: Close the hernia sac.

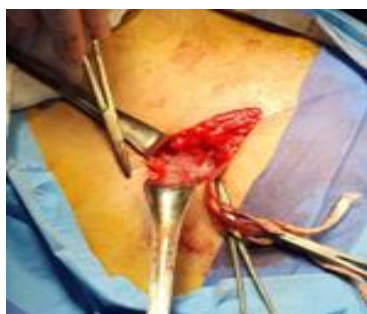

Figure 6: Lichtenstein mesh hernioplasty.

Table 1: Losanoff and Bason classification.

Classification	Salient features	Surgical management
Type 1	Normal appendix	Reduction or appendectomy, mesh hernioplasty
Type 2	Acute appendicitis localized in the sac	Appendectomy through hernia, endogenous repair
Type 3	Acute appendicitis, peritonitis	Appendectomy through laparotomy, endogenous repair
Type 4	Acute appendicitis, other abdominal pathology	Appendectomy, diagnostic workup and other procedures as appropriate

Table 2: Classification of Amyand hernia after Rikki modification.

Classification	Salient features	Surgical management
Type 1	Normal appendix	Reduction or appendectomy, mesh hernioplasty
Type 2	Acute appendicitis localized in the sac	Appendectomy through hernia, endogenous repair
Type 3	Acute appendicitis, peritonitis	Appendectomy through laparotomy, endogenous repair
Type 4	Acute appendicitis, other abdominal pathology	Appendectomy, diagnostic workup and other procedures as appropriate
Type 5A	Normal appendix, within an incisional hernia	Reduction, mesh hernioplasty
Type 5B	Acute appendicitis within an incisional hernia without peritonitis	Appendectomy through hernia, endogenous repair
Type 5C	Acute appendicitis within an incisional hernia with peritonitis or abdominal wall sepsis or in relation to previous surgery	Appendectomy, diagnostic workup and other procedures as appropriate

DISCUSSION

Various abdominal organs and tissues have been found within inguinal hernias, this included fat, bowel, colon, omentum, ovary, bladder, and appendix.⁹ Also, this clinical entity has been used to describe clinical conditions that include: inflamed appendix in the hernia sac, perforated appendix in the hernia sac, and non-inflamed appendix in an irreducible inguinal hernia.⁹ The true incidence of this clinical entity is difficult to establish, however some large retrospective studies calculated in 0.14-0.13%, other studies calculated between 0.19-1.7%; whereas the incidence of concomitant acute appendicitis was calculated in 0.07-0.13%.¹ The incidence of perforated appendix incarcerated within an inguinal hernia was reported at 0.1% of all cases of appendicitis.⁶ Generally, in 90% of the cases are in males, with a preponderance in pediatric patients, the relation men: women are 28:1 in the childhood whereas in adults is 7:1.¹ Also there exist a

bimodal age distribution, the first age goes to 1 month to 1 year old, and the second age is after 70 years. This is explained because at birth, the internal inguinal ring is relatively large, whereas a patent processus vaginalis probably fails to close during the first year or even more; also in the midlife, the internal inguinal ring starts to enlarge again.¹ Thus, this clinical entity has been reported in patients ranging in age from 3 weeks to 92 years.⁶ Amyand's hernia generally occur on the right side however there are cases with unusual left-side presentation probably associated with situs inversus, intestinal malrotation or with a mobile cecum.^{1,5-9} The pathophysiology is still not well understood; however, two theories have been proposed: the first one mentions that the main event is represented by an appendiceal inflammation which progressively leads to a severe edema; in advanced stages, the edema initially causes venous stasis but later takes to an insufficient arterial supply until a bacterial necrosis and superinfection supervene. The second one, on the other hand, states that the appendix engaged into the hernial sac exposes itself to small traumas that give rise to an inflammatory reaction with the formation of adhesions that entrench the retention of the appendix in the hernial sac. The physiologic contraction of the abdominal muscles can suddenly increase the abdominal pressure; abdominal hypertension causes compression of the appendix resulting in a further inflammation that compromises blood supply.¹⁰ All of them have in common the migration of the appendix into the inguinal canal that leads to a greater vulnerability to inflammation and infection. Some of these theories are: incarceration of the appendix in the inguinal hernia, protrusion of the appendix in the sac hernia and development adhesions, contraction of the anterolateral abdominal musculature causing external compression of the appendix and obstruction of the lumen, inflammatory swelling of the appendix.¹

The non-complicated Amyand's hernias generally are asymptomatic or present with non-specific symptoms, usually this clinical entity is an incidental finding. In complicated Amyand's hernia, a variety symptoms and signs like right lower quadrant pain, scrotal pain, tender and irreducible groin lump, etc.; can be found on the exploration. As a result, is difficult to established the diagnosis and the management can be delay. Generally, the diagnosis is discovered intraoperatively and only 1 of 60 cases are diagnosed pre-operatively.^{1,6} Various complication has been reported in the literature, such as abdominal abscess, inflamed right testicle and spermatic cord, testicular ischemia, necrotizing fasciitis of the anterior abdominal wall.⁶ It's important to known the differential diagnosis, in patients with such an unspecific symptoms and signs, some of this diagnosis span complicated inguinal hernia, acute appendicitis, urological emergencies like testicular torsion, orchiepididymitis or acute hydrocele, also some cutaneous complications like inguinal abscess or lymphadenopathy. In some cases, McBurney's sign is

negative, since the appendix is not in its habitual location.¹ The use of complementary studies such as ultrasound and CT can increase the possibility to obtain a prompt and accurate diagnosis.⁸ In ultrasonography, the appearance of a thick-walled tubular structure in the hernia sac, wich is connecting with the cecum and ending with the blind end, is highly suggestive for making the diagnosis.¹¹ CT scan is more sensitive and specific than the ultrasound because allows the direct visualization of the appendix inside the inguinal canal, however CT is not routinely performed as a first step evaluation tool, and some diagnosis can be missed, besides this fact, is considered to be the best imaging tool for the evaluation of acute abdomen and abdominal hernias.^{8,9} CT diagnosis is more often incidental.⁶ A definitive pre-operative diagnosis of Amyand's hernia is rare since the diagnosis is usually made during surgery.¹² The tomography findings depend on the stage disease classified by Losanoff and Bason. In type 1, a normal appendix in the inguinal canal can be find; in type 2 an enlarged and thickened appendix with an inflammation of the surrounding fat is found. In type 3 there are inflammatory changes intra-abdominal, and in type 4 is present other intra-abdominal findings.⁸ In 2008 Losanoff and Bason decide to make a classification for Amyand hernia (Table 1), to standardized the surgical management.^{3,4}

In type 1 the option of removing or leaving behind a normal appendix is based upon the patient's characteristics (age, life expectancy, lifelong risk to developing acute appendicitis). In type 2 where there is an inflammatory process confined in the hernia sac, there exists a high risk of mesh infection, thereby is a better option to realize a hernioplasty with endogenous tissue. Type 3 require a more extensive surgery like exploratory laparotomy for source control, orchiectomy, right hemicolectomy or debridement of necrotizing fasciitis; it is possible to defer the hernioplasty in all the patient which are hemodynamically unstable. In type 4, in addition to the inflammatory process, there exist other medical condition such as appendiceal mucocele, colon cancer, diverticulitis, adenocarcinoma of the vermiform appendix or inguinal appendicocele with pseudomyxoma peritonei.³ In addition, the classification of Losanoff and Bason was modified by Rikki et al they added to the classification the type 5 that described patient who has an incisional hernia (Table 2).⁷

The primary management for Amyand's hernia with a non-inflamed appendix is hernia repair without appendectomy. Some clinicians believe that this will decrease the occurrence of post-operative complications because appendectomy will convert a clean surgery into a clean-contaminated surgery.¹³ Management of Amyand's hernia, for patients who need both appendectomy and hernia repair, it's prefer to perform appendectomy first, disinfect the stump of the appendix, cover the stump of the appendix with purse suture, absorb the exudate from the abdominal cavity, and then repair the hernia.¹³ Mesh repair is recommended when a non-inflamed appendix,

mesh repair should be conducted after removal of the appendix regarding an inflamed appendix without perforation or abscess. As for the perforated appendix, the synthetic mesh repair should be avoided.¹³

CONCLUSION

The Amyand's hernia is an extremely rare entity, however with a high mortality. The signs and symptoms vary within presentation, and can be unspecific, the use of lab studies and imaging tool in most part of the time is not helpful in the differential diagnosis. It's difficult to establish a pre-operative diagnosis, and generally is incidental. There is still no consensus about the optimal management approach to this entity; however, Losanoff and Basson classified and give an interesting management approach, even so, there is no much evidence about the plausible of this recommendation, and we think more studies are necessary to standardized the optimal approach.

Funding: No funding sources

Conflict of interest: None declared

Ethical approval: Not required

REFERENCES

1. Manatakis DK, Tasis N, Antonopoulou MI, Anagnostopoulos P, Acheimastos V, Papageorgiou D, et al. Revisiting Amyand's Hernia: A 20-Year Systematic Review. *World J Surg.* 2021;45(6):1763-1770.
2. Milanchi S, Allins AD. Amyand's hernia: history, imaging, and management. *Hernia.* 2008;12(3):321-2.
3. Okita A, Yoshida O, Murakami M. Incarcerated Amyand's Hernia. *Acta Med Okayama.* 2020;74(2):171-4.
4. Guler I, Alkan E, Nayman A, Tolu I. Amyand's Hernia: Ultrasonography Findings. *J Emerg Med.* 2016;50(1):e15-7.
5. Gao Y, Zhang T, Zhang M, Hu Z, Li Q, Zhang X. Amyand's hernia: a 10-year experience with 6 cases. *BMC Surg.* 2021;21(1):315.
6. Nowrouzi R, Gupta R, Kuy S. Left-Sided Amyand Hernia: Case Report and Review of the Literature. *Fed Pract.* 2021;38(6):286-90.
7. Elgazar A, Awad AK, Mandal D, Faddah RM, Elder Z, Elseidy SA. Sliding Amyand's hernia: a case report and review of literature. *J Surg Case Rep.* 2021;2021(7):288.
8. Ivanschuk G, Michalinos A, Moris D, Vernadakis S. Amyand's hernia: a review. *Am J Surg.* 2014;207(6):989-95.
9. Desai G, Suhani, Pande P, Thomas S. Amyand's hernia: our experience and review of literature. *Arq Bras Cir Dig.* 2017;30(4):287-8.
10. Montali F, Baldinu M, Annicchiarico A, Virgilio E, Costi R. Amyand's hernia: which oncologic risk can be hidden in the sac? *Acta Biomed.* 2022;93(S1):e2022273.
11. Fezoulidi G, Argyrouli V, Adamopoulos E, Makridis KG, Zourntou SE, Fezoulidis IV. Amyand's hernia: presumptive diagnosis by CT and literature review. *Radiol Case Rep.* 2021;16(4):911-5.
12. Losanoff JE, Basson MD. Amyand hernia: a classification to improve management. *Hernia.* 2008;12(3):325-6.
13. Shekhani HN, Rohatgi S, Hanna T, Johnson JO. Amyand's Hernia: A Case Report. *J Radiol Case Rep.* 2016;10(12):7-11.

Cite this article as: Silva-Zamora J, Macias AR, Arriola LAB, Escobedo CAD, Rendón AGV, Flores JGS. Amyand's hernia: an uncommon entity. *Int J Res Med Sci* 2024;12:1259-63.