

Case Report

Anomalous origin of the left coronary artery with origin in the right coronary artery from a single coronary ostium associated with multivessel coronary artery disease: case report and literature review

Jovany Castro-Lara^{1*}, Sara S. Herrera-Lemus², Sandra Sánchez-Cassio³,
Manuel A. Vera-Fuentes⁴, Marco G. Vivas-Baizabal², Erick G. Andrade-Torres⁴

¹Department of Internal Medicine, Regional General Hospital No. 1 “Ignacio García Téllez” IMSS, Facultad de Medicina-Universidad Autónoma de Yucatán, Mérida, Yucatán, México

²Department of Diagnostic and Therapeutic Imaging, High Specialty Medical Unit, National Medical Center “Ignacio García Téllez” IMSS, Mérida, Yucatán, México

³Department of Cardiology, Regional General Hospital No. 1 “Ignacio García Téllez” IMSS, Mérida, Yucatán, México

⁴Department of Cardiology, High Specialty Medical Unit, National Medical Center “Ignacio García Téllez” IMSS, Mérida, Yucatán, México

Received: 18 January 2024

Revised: 02 February 2024

Accepted: 03 February 2024

*Correspondence:

Dr. Jovany Castro-Lara,

E-mail: castrolarajovany@gmail.com

Copyright: © the author(s), publisher and licensee Medip Academy. This is an open-access article distributed under the terms of the Creative Commons Attribution Non-Commercial License, which permits unrestricted non-commercial use, distribution, and reproduction in any medium, provided the original work is properly cited.

ABSTRACT

The anomalous origin of the coronary arteries is a group of rare congenital heart conditions in which there has been an increase in its diagnosis thanks to more accessible and less invasive imaging techniques such as coronary angiotomography, which allows visualization of the arteries in its entire path in a short exploration interval, with adequate spatial and temporal resolution. The clinical presentation is variable, up to 80% are asymptomatic and the remaining 20% may present arrhythmias, myocardial infarction, heart failure and sudden death. We present the case of a patient with unstable angina in whom an anomalous origin of the left coronary artery (LCA) with origin in the right coronary artery (RCA) from a single coronary ostium associated with multivessel coronary artery disease was diagnosed.

Keywords: Anomalous LCA, Coronary anomalies, Coronary artery disease

INTRODUCTION

Coronary artery anomalies (CAA) are a group of congenital heart conditions characterized by an abnormal origin or course of either of the two coronary arteries.¹ They are often discovered as an incidental finding during the diagnostic approach in ischemic heart disease.

We present the case of a patient with an anomalous origin of the LCA that was detected in the context of multivessel coronary artery disease.

CASE REPORT

A 63-year-old man with cardiovascular risk factors as hypertension, tobacco use and sedentary behavior who was admitted to the emergency department due to acute coronary syndrome-unstable angina. An electrocardiogram was performed, with the presence of atrial fibrillation, complete right bundle branch block and low lateral subendocardial injury therefore impregnation with amiodarone was performed, obtaining successful cardioversion. The transthoracic echocardiogram reported abnormal mobility of the left ventricle characterized by

hypokinesia of the basal and middle segment of the inferior wall, type I diastolic dysfunction, left ventricular ejection fraction (LVEF) of 60% and dilation of the left atrium; he received treatment based on beta-blocker, high-intensity statins, antiplatelet and anticoagulation. The patient clinical evolution was favorable.

As part of diagnostic workup, coronary CT angiography (CTA) was performed revealing an anomaly of the LCA, which originates from RCA with retro aortic course with a single coronary ostium type R-IIp (Figure 1).

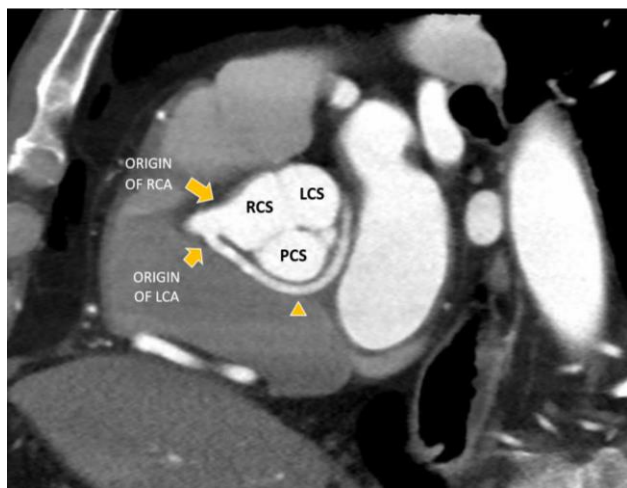


Figure 1: Oblique sagittal reconstruction of coronary CT angiography where an anomaly of the LCA is identified originating in the trunk of the RCA and retro-aortic path (arrowhead).

LCS-Left coronary sinus and PCS-Posterior coronary sinus.

Left main of the LCA with non-significant calcified plaques (Figure 2); the anterior descending artery (ADA) with an 100% proximal obstruction, proximal circumflex artery (CX) with the presence of partially calcified plaques that produces >70% luminal obstruction, and posterior descending artery (PDA) with 40-50% involvement with an Agatston score of 270, CAD-RADS 5; also exist collateral circulation from the RCA to the anterior wall of the heart, (Figure 3).

Coronary angiography was also performed, revealing a long left main coronary artery (LMCA), with adequate caliber, which arises from the RCA with a retro-aortic course, without significant angiographic stenosis (Figure 4). The ADA with 2.5 mm diameter, which is occluded from the middle segment receiving collateral circulation from the RCA. Non-dominant CX, with severe stenosis at ostium and proximal segment. A dominant RCA, with a posterolateral branch of 2.25 mm with a severe distal stenosis of 80%. An aortogram was performed and allowed visualization of just the right coronary ostium from what LMCA emerges.

Due to the complex cannulation because significant arterial tortuosity and the amount of contrast used after

multiple failed attempts to perform coronary angioplasty, the intervention was aborted. The case was discussed in association with the surgical medical team and medical treatment option due to high risk was concluding. Eight months after initial symptoms, patient is asymptomatic.

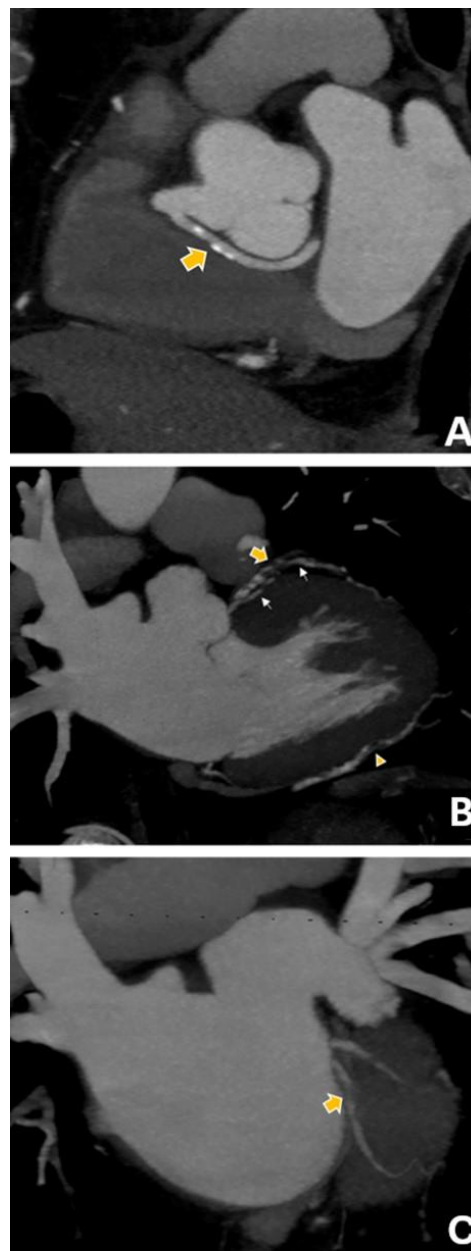


Figure 2 (A-C): Coronary CT angiography with maximum intensity projection in sagittal oblique and coronal oblique reconstruction where atherosclerotic plaques are evident in the retro-aortic path of the LCA with non-significant obstruction; as well as atherosclerotic plaques throughout the course of the ADA (arrow) and in the distal segment of the PDA (arrowhead), causing total occlusion and approximate 50% obstruction respectively. The circumflex artery shows proximal involvement with 70% obstruction. The white arrows indicate the accessory artery that provides collateral circulation to the anterior wall.

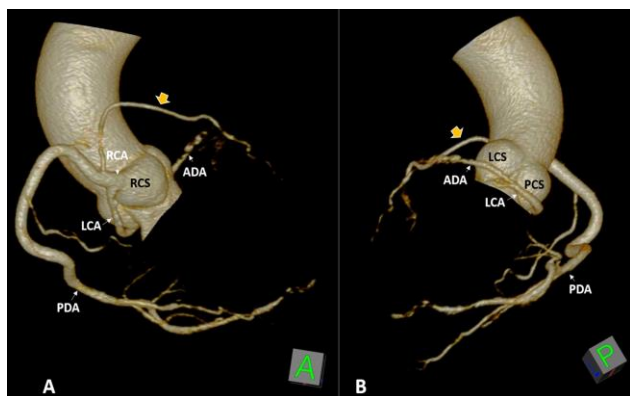


Figure 3 (A and B): 3D reconstructions of coronary CT angiography, anterolateral and posterolateral views, where the anomalous origin of the LCA is evident with origin in the RCA and a single coronary ostium, and its retro-aortic course is also observed. Artery that arises from the RCA and provides collateral circulation to the anterior wall (yellow arrow).

RCS-Right coronary sinus), LCS-Left coronary sinus) and PCS-Posterior coronary sinus. RCA and LCA (Right and Left coronary artery), ADA and PDA-anterior and posterior descending artery.

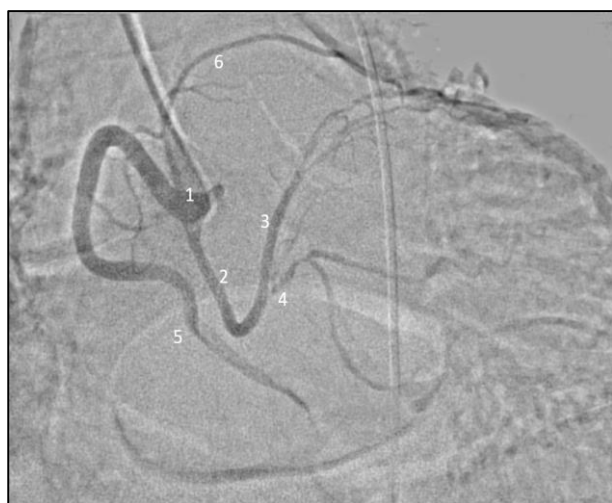

Figure 4: Coronary angiography with digital subtraction where the anomalous origin of the LCA with origin in the RCA of a single coronary ostium is identified.

RCA (1), LCA (2), ADA (3), Circumflex Artery (4), PDA (5) and accessory artery that provides collateral circulation to the anterior wall (6).

DISCUSSION

CAA are the result of processes that alter the normal differentiation and specialization of the primitive heart tube. The position of the endothelial buds or the septation of the truncus arteriosus can give rise to anomalous origins.² In the case of LCA, which classically arises from the ascending aorta just above the left cusp of the

aortic valve, it can mainly give rise to two anomalies: LCA originating in the pulmonary artery and LCA originating in the RCS. A third anomaly has been reported in which the LCA arises from the RCA.³

The variant of an anomalous LCA arising from the RCS occurs in only 0.0024 to 0.02% of the population; although the exact prevalence is unknown, it is likely that the variant of LCA arising from RCA is even rarer.⁴ The prognosis of CAA is poorly known, and the therapeutic decisions recommended by the guidelines are supported by a low level of evidence.

The clinical presentation is variable, 80% are asymptomatic and diagnosed incidentally, the remaining 20% present arrhythmias, myocardial infarction, heart failure, syncope and sudden death.^{5,6} Currently, thanks to non-invasive methods such as CTA of the coronary arteries, which has adequate spatial and temporal resolution, it allows visualization of the entire course of the coronary arteries in a short scanning interval, which is why it is currently considered the gold standard for the detection of these anomalies.^{1,6}

There are three therapeutic modalities for CAA: surgical treatment, percutaneous coronary intervention (PCI) and medical treatment. Surgical treatment will depend on the characteristics of the CAA, with the objective of restoring a dual coronary system through reimplantation of the anomalous vessel in the ascending aorta, with direct translocation of the anomalous artery being the technique of choice.¹ As a surgical alternative, revascularization surgery can be chosen. The postoperative outcome depends on the degree of left ventricular dysfunction at the beginning of the study.¹ Another therapeutic option is PCI; however, its evidence is low because it has high stent failure rates.

In the literature, a series of cases have been described where the heterogeneity of therapeutic options is observed for patients with anomaly of the LCA originating in the RCS or directly from the RCA associated with obstructive coronary disease, for example, patients who had surgical resolution in the cases reported by Shtembari et al and Cocceani et al.^{7,8} Although there are other cases that required PCI, or that were only managed with pharmacological treatment and cardiological follow-up.^{4,9-11}

CONCLUSION

We present the case of a patient in the seventh decade of life who presented with multivessel coronary artery disease in the context of an anomalous origin of the LCA detected in CT angiography. Management in the case of coexisting ischemic heart disease must be individualized with a multidisciplinary approach; rarely the obstructive lesions affect the anomalous course segment of the coronary artery. To our knowledge, this is the first reported case in Latin América of a patient with

anomalous origin of LCA which originates from RCA and coexists with multivessel coronary artery disease and lesions within the course of the anomalous segment.

Funding: No funding sources

Conflict of interest: None declared

Ethical approval: Not required

REFERENCES

1. Gentile F, Castiglione V, De Caterina R. Coronary Artery Anomalies. *Circulation*. 2021;144(12):983-96.
2. Keswani AN, Dann K, Ramee S. Anomalous Right Coronary Artery: A Case Report. *Ochsner J*. 2014;14(2).
3. Carter YM, Wehrle CJ, Mahajan K. Anatomy, Thorax, Heart Anomalous Left Coronary Artery. In: *StatPearls*. StatPearls Publishing. 2023.
4. Kilic A, Kilic A, Sultan I. Anomalous Origin of the Left Main Coronary Artery from the Right Coronary Artery. *Circ: Cardiovascular Imaging*. 2018;11(12):e008452.
5. Martínez-Cano CA, Aguilar-Arias A, Arango-Rivas AM, Baena-Gómez C. Origen «maligno» de arteria coronaria izquierda, reporte de caso. *Arch Cardiol Mex*. 2021;92(1):6303.
6. Balaguer-Malfagón JR, Estornell-Erill J, Vilar-Herrero JV, Pomar-Domingo F, Federico-Zaragoza P, Payá-Serrano R. Anomalous Left Coronary Artery from the Right Sinus of Valsalva Associated With Coronary Atheromatosis. *Rev Esp Cardiol*. 2005;58(11):1351-4.
7. Shtembari J, Shrestha DB, Oli PR, Munagala A, Mullaj E, Shehata K et al. Anomalous Origin of the Left Coronary Artery From the Right Coronary Cusp: A Case Report. *Cureus*. 2023;15(3):e35711.
8. Coceani M, Ciardetti M, Pasanisi E, Schlueter M, Palmieri C, Neglia D et al. Surgical Correction of Left Coronary Artery Origin From the Right Coronary Artery. *Ann Thoracic Surg*. 2013;95(1):e1-2.
9. Lee JH, Park JS. Successful percutaneous coronary intervention in the setting of an aberrant left coronary artery arising from the right coronary cusp in a patient with acute coronary syndrome: a case report. *BMC Cardiovasc Disord*. 2017;17(1):186.
10. Yildiz O, Karabay KO, Akman C, Aytekin V. Anomalous Origin of the Left Main Coronary Artery from the Right Coronary Artery with a Preaortic Course. *Texas Heart Institute J*. 2015;42(3):243-5.
11. Tanrivermis Sayit A, Celenk V, Celenk C. Anomalous origin of the left coronary artery from the right coronary artery with trans-septal course: a rare case report. *Coronary Artery Dis*. 2021;32(4):356-8.

Cite this article as: Castro-Lara J, Herrera-Lemus SS, Sánchez-Cassio S, Vera-Fuentes MA, Vivas-Baizabal MG, Andrade-Torres EG. Anomalous origin of the left coronary artery with origin in the right coronary artery from a single coronary ostium associated with multivessel coronary artery disease: case report and literature review. *Int J Res Med Sci* 2024;12:935-8.