

Case Series

A clinical study on reconstruction of traumatic auricular defects

A. Ravi Chandra Mohan, Jyostna Poldas, Jada Mabu, Vaibhav Thobbi*

Department of Plastic and Reconstructive Surgery, Siddhartha Medical College and Government General Hospital, Vijayawada, Andhra Pradesh, India

Received: 21 March 2024

Revised: 04 April 2024

Accepted: 05 April 2024

***Correspondence:**

Dr. Vaibhav Thobbi,

E-mail: vaibhavthobbi@gmail.com

Copyright: © the author(s), publisher and licensee Medip Academy. This is an open-access article distributed under the terms of the Creative Commons Attribution Non-Commercial License, which permits unrestricted non-commercial use, distribution, and reproduction in any medium, provided the original work is properly cited.

ABSTRACT

The auricle or external ear is an important aesthetic subunit of the face. The intricate anatomy due to multiple convolutions along with the thin integument poses a challenge to the reconstructive surgeon. The prominent position of the ear on either side of the face and over a bony prominence makes it more prone for injury. The objective of the study is to describe various traumatic auricular defects and their subsequent reconstructive methods. A retrospective analysis of 15 patients with traumatic auricular defects was carried out over a period of 2 years between the time period of January 2022 and December 2023. Various reconstructive methods such as Primary closure, use of chondral grafts and chondrocutaneous flaps, local flaps were employed depending on the size of the defect and according to the reconstructive ladder. Out of 15 patients, 12 were male and 3 were female, with traumatic ear defects secondary to road traffic accidents (12) and human bite (3). The site of the defect was upper 1/3d (8), upper+middle 1/3rd (3), lower+middle third (2), middle third (1) and lower 1/3rd (1) of the auricle. They were managed by debridement and primary closure in 5 cases, post auricular flap in 5 cases, preauricular flap in 2 cases, peninsular conchal island flap+postauricular flap in 1 case, and bilobed flap in 1 case. All the flaps settled well. 4 patients needed secondary procedures in the form of flap division and contour corrections. This study employed a variety of reconstruction methods of the auricle as per the reconstructive ladder. Some of the patients required secondary procedures. All patients in this study had a satisfactory end aesthetic outcome with no major complications.

Keywords: Auricle, External ear, Trauma, Reconstruction, Primary repair, Local flaps

INTRODUCTION

The auricle is an important aesthetic subunit of the face. Its prominent location on either side of the face makes it prone for injury.¹ The auricle may also be involved in a number of congenital deformities, benign and malignant conditions. The goal of ear reconstruction is creation of a normal looking and aesthetically pleasing auricle. The auricle is located at the lateral aspect of the face and is far away from the facial triangle (eye-nose-eye) where the attention of people is most focused.² Hence the need for reconstruction is indicated in cases with auricular deformity. The aim of reconstruction is to construct a

natural looking auricle with balance and harmony. Auricle reconstruction may be achieved by any number of described methods as per the reconstructive ladder.

CASE SERIES

A retrospective analysis of 15 patients with traumatic auricular defects was carried out over a period of 2 years between the time period of January 2022 and December 2023. These include the use of various reconstructive methods as per reconstructive ladder such as Primary closure, use of chondral grafts and chondrocutaneous flaps, local flaps defects.

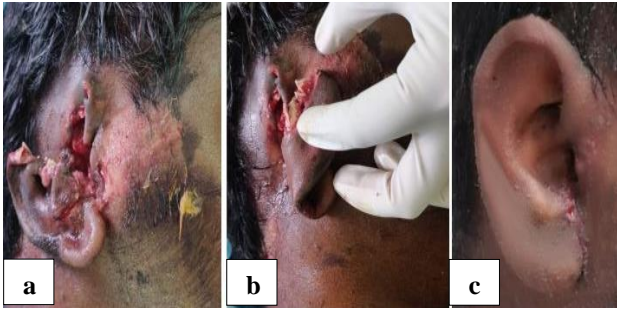

Figure 1 (a-c): Near total avulsion injury managed with debridement and primary closure.

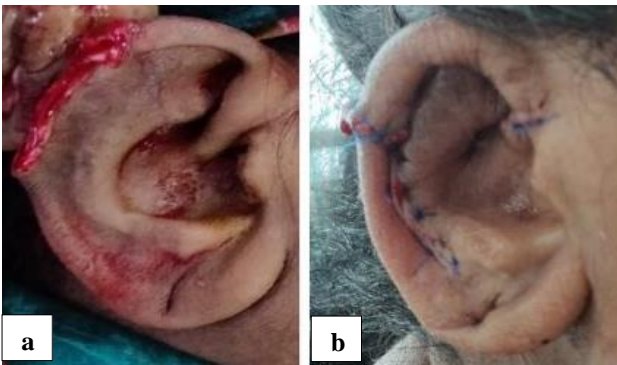


Figure 2 (a and b): Upper 1/3rd defect managed with antia-buch bilateral chondrocutaneous advancement flap.

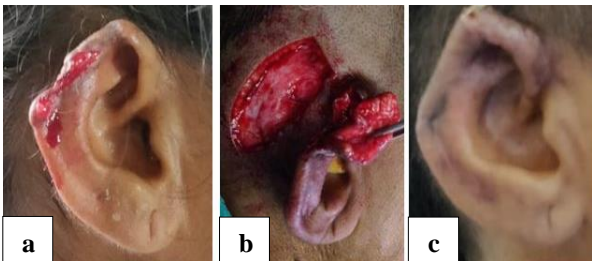


Figure 3 (a-c): Upper 1/3rd defect managed with postauricular flap.

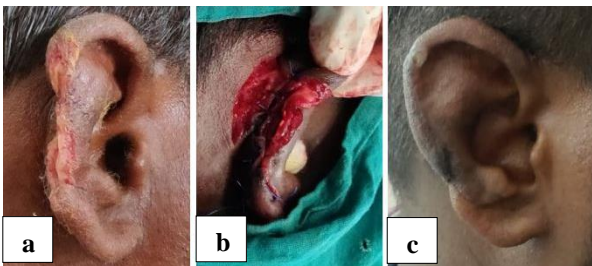


Figure 4 (a-c): Middle third defect managed with postauricular banner flap.

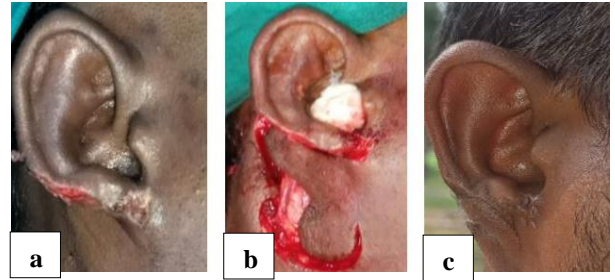


Figure 5 (a-c): A case of human bite of lower 1/3rd of ear managed with bilobed flap.

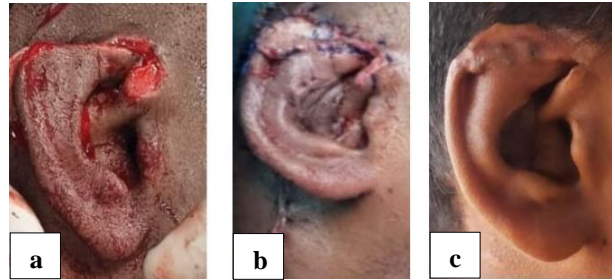


Figure 6 (a-c): Case of human bite upper 1/3rd defect managed by peninsular conchal island flap and postauricular flap cover.

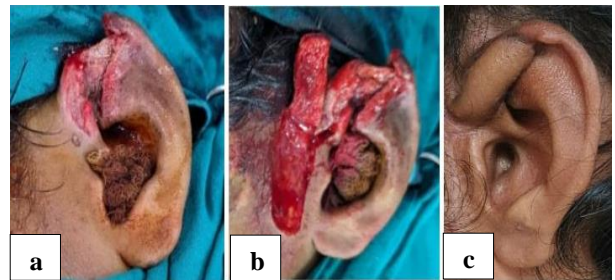


Figure 7 (a-c): Case of post traumatic upper 1/3rd defect managed by preauricular flap.

Pre-operatively all patients were assessed with a complete surgical profile and anaesthetic fitness was taken. Consent for staged surgical procedures was taken in cases which required flap cover via local flaps or staged reconstruction of congenital defects.

Inclusion criteria

All patients with post traumatic defects of the auricle were included in this study.

Exclusion criteria

Patients with auricular defects secondary to congenital anomalies, post excision of benign or malignant lesions and post infective defects were excluded from this study.

Table 1: Patient and auricular defect characteristics.

S. no	Patient age (years)	Patient sex	Aetiology of defect	Anatomical location	Side involved	Reconstructive method
01	28	Male	Road traffic accident	Upper 1/3rd	Right	Debridement and primary closure
02	19	Male	Road traffic accident	Middle 1/3rd	Right	Postauricular flap
03	40	Female	Road traffic accident	Upper 1/3rd	Left	Antia buch unilateral flap
04	20	Male	Road traffic accident	Upper 1/3rd	Right	Postauricular flap
05	25	Male	Human bite	Upper 1/3rd	Right	Debridement+primary closure
06	38	Female	Road traffic accident	Middle 1/3rd	Right	Banner flap
07	22	Male	Human bite	Upper 1/3rd	Right	Conchal peninsular island flap+postauricular flap
08	30	Male	Road traffic accident	Upper+middle 1/3rd	Left	Debridement and primary closure
09	22	Male	Road traffic accident	Middle+lower 1/3rd	Right	Debridement and primary closure
10	40	Female	Road traffic accident	Middle+lower 1/3rd	Left	Debridement and primary closure
11	20	Male	Road traffic accident	Upper+middle 1/3rd	Right	Postauricular flap
12	30	Male	Human bite	Lower 1/3rd	Right	Bilobed flap
13	13	Male	Road traffic accident	Upper 1/3rd	Right	Postauricular flap
14	16	Male	Road traffic accident	Upper 1/3rd	Left	Preauricular flap
15	40	Male	Road traffic accident	Upper 1/3rd	Right	Preauricular flap

DISCUSSION

All patients underwent surgical repair under local anaesthesia when possible and compliant, or under general anaesthesia. Post-operative period was uneventful for all patients in this study. Patients were followed up postoperatively for a period of 6 months and were found to have no complications.

With respect to a study conducted by Heshamaly et al, 14 patients in their study were treated with conchal cartilage graft for defects of only the upper 1/3rd of the auricle and temporoparietal flap.⁹

Another study by Li Datao et al which was conducted on 60 patients showed patients treated using conchal cartilage and posterior auricular flaps in 4 cases. In 51 ears, costal cartilage and posterior auricular flaps were used. In five instances of severe posterior auricular cutaneous scarring, temporoparietal fascial flaps were used.¹⁰

With respect to a study conducted by Michel et al, a series of 105 patients were analysed, out of which 78% underwent reconstruction using costal cartilage and the rest were treated with conchal cartilage grafts followed by pedicled postauricular flap or temporoparietal fascial flap.¹¹

Table 2: Summary of results.

Parameters	Results
Median age	27 years
Males: females	12 males, 3 females
Etiology	Road traffic accident-12, human bite-3
Location of defect	Upper 1/3rd-8, middle third-1, upper+middle 1/3rd -3, middle+lower 1/3rd -2, lower 1/3rd -1
Reconstructive method	Debridement+primary closure-5, postauricular flap- 4, preauricular flap-2, banner flap-1, bilobed flap-1, peninsular conchal island flap+postauricular flap-1

CONCLUSION

Reconstruction of the external or auricle is aesthetically demanding. Various techniques are used according to the defect size, location, and tissues involved and the surgeon's preference. The armamentarium for reconstruction of these defects can be varied, ranging from primary closure, to local flaps, chondral grafts and complete staged ear reconstruction. It is essential to adhere to the anatomical subunits and principles of reconstruction while planning anatomical repairs in order to achieve an aesthetically pleasing final post-operative result.

Funding: No funding sources

Conflict of interest: None declared

Ethical approval: Not required

REFERENCES

1. Armin BB, Ruder RO, Azizadeh B. Partial auricular reconstruction. *Semin Plast Surg.* 2011;25:249-56.
2. Ebrahimi A, Kazemi A, Rasouli HR, Kazemi M, Kalantar Motamedi MH. Reconstructive Surgery of Auricular Defects: An Overview. *Trauma Mon.* 2015;20:e28202.
3. Stella C, Adam MF, Edward L. Helical Rim Reconstruction: Antia-Buch Flap. *Eplasty.* 2015;15:ic55.
4. Tanzer RC. Total reconstruction of the external auricle. *Arch Otolaryngol.* 1961;73:64-8.
5. Siegert R, Magritz R. Reconstruction of the auricle. *GMS Curr Top Otorhinolaryngol Head Neck Surg.* 2007;6:Doc02.
6. Shaye D, Sykes JM. Reconstruction of acquired auricular deformity. *Oper Tech Otolaryngol Head Neck Surg.* 2011;22:47-52.
7. Kaufman AJ. Helical rim advancement flaps for reconstruction. *Dermatol Surg.* 2008;34:1229-32.
8. Gault D. Post traumatic ear reconstruction. *J Plast Reconstr Aesthet Surg.* 2008;61:5-12.
9. Helal HA, Mahmoud NA, Abd-Al-Aziz AA. Reconstruction of post-traumatic full-thickness defects of the upper one-third of the auricle. *Plast Surg (Oakv).* 2014;22:22-5.
10. Li D, Xu F, Zhang R, Zhang Q, Xu Z, Li Y, et al. Surgical Reconstruction of Traumatic Partial Ear Defects Based on a Novel Classification of Defect Sizes and Surrounding Skin Conditions. *Plast Reconstr Surg.* 2016;138:307e-16e.
11. Kolodzynski MN, Kon M, Egger S, Breugem CC. Mechanisms of ear trauma and reconstructive techniques in 105 consecutive patients. *Eur Arch Otorhinolaryngol.* 2017;274:723-8.

Cite this article as: Mohan ARC, Poldas J, Mabu J, Thobbi V. A clinical study on reconstruction of traumatic auricular defects. *Int J Res Med Sci* 2024;12:1690-3.