International Journal of Research in Medical Sciences
Sosa MC et al. Int J Res Med Sci. 2024 Oct;12(10):3892-3896
www.msjonline.org
pISSN 2320-6071 | eISSN 2320-6012

DOI: https://dx.doi.org/10.18203/2320-6012.ijrms20242956

Case Report

Laparoscopic mirror cholecystectomy: gallbladder lithiasis in a patient with situs inversus

Monica Castro Sosa*, Reyger Hernandez Sosa, Yazmin G. González

Department of General Surgery, Hospital General Regional Mérida T1-Instituto Mexicano del Seguro Social, Mérida, Yucatán, México

Received: 18 August 2024
Revised: 12 September 2024
Accepted: 13 September 2024

***Correspondence:**
Dr. Monica Castro Sosa,
E-mail: reyger_hernandez@hotmail.com

Copyright: © the author(s), publisher and licensee Medip Academy. This is an open-access article distributed under the terms of the Creative Commons Attribution Non-Commercial License, which permits unrestricted non-commercial use, distribution, and reproduction in any medium, provided the original work is properly cited.

ABSTRACT

The location of the organs with respect to the midline of the body is known as situs, situs inversus refers to the sagittal inversion of the thoracoabdominal organs with an incidence of 0.01% of the population. A 51-year-old female with a history of SIT, refers colic in the left hypochondrium associated with the intake of cholecystokinetic food, vesicular lithiasis is diagnosed by ultrasound, laparoscopic cholecystectomy was performed with placement of 12 mm trocars in the umbilical and subxiphoid region slightly lateralized to the left, 5 mm trocars below the costal margin left midclavicular line and on the left flank anterior axillary line. Deletion of the Pitx2 transcription factor disrupts normal morphogenesis and develops visceral asymmetry. The risk of developing gallstones is the same as the rest of the population; which presents classic symptoms, 30% will present epigastric pain, 10% will present pain in the right hypochondrium and the rest will present pain in the left upper quadrant, laparoscopic cholecystectomy is the gold standard treatment. In this genetic anomaly, it is important to know the changes in the clinical presentation for a timely diagnosis. Modifications in the technique and anatomical arrangement represent a challenge for the surgical team, which is why an experienced team with extensive knowledge of biliary anatomy is required to avoid the risk of injury.

Keywords: Gallbladder lithiasis, Genetic malformations, Laparoscopic cholecystectomy, Situs inversus totalis

INTRODUCTION

The location of the organs with respect to the midline of the body is known as situs, which can present in 3 ways, situs solidus, refers to the normal arrangement of the organs as we know it, ambiguous situs is the random arrangement of the internal organs and situs inversus refers to the sagittal inversion of the thoracoabdominal organs.[1,2]

Situs inversus is a rare genetic disease that can affect one or more organs. When it affects both organs of the thoracic cavity and the abdominal cavity, it is called situs inversus totalis (SIT), which is due to an alteration in embryonic development in the gastrulation stage around the third week. This condition may be associated with other genetic malformations, sometimes incompatible with life, so its incidence is difficult to evaluate. However, it has been estimated that it occurs in 0.01% of the population, in 1/10,000-20,000 births.[1,3]

The presence of SIT without other associated malformations does not represent a health problem for patients with this condition; however, due to the inverted arrangement of the organs, the clinical presentation and diagnosis of pathologies can represent a challenge for health professionals.[2,3] Gallbladder lithiasis is a chronic and multifactorial disease that has a high incidence worldwide, and laparoscopic cholecystectomy is among the 5 most frequent surgeries in our country. It mainly

affects women and despite having a genetic component, environmental factors such as obesity and diet can also influence its presentation. However, in the case of STI, no relationship has been found between those who have it and are more predisposed to suffering from the disease.[4,5]

Due to its high incidence worldwide, the clinical presentation of gallbladder lithiasis is well known, so for health professionals the set of symptoms, laboratories and imaging studies can provide a certain diagnosis of this disease, however, in patients with SIT it is difficult to reach a diagnosis due to a misleading clinical presentation. For patients requiring surgery, it is essential to be aware of this situation, as it requires a more complex surgical approach and a high level of surgical experience to successfully address these scenarios.[1,3]

We present the case of a female patient in her sixth decade of life who came to our clinic with a history of multiple episodes of colic pain in the left hypochondrium. USG was performed, which reported the presence of gallstones, due to a previous clinical history the patient was aware of her condition with SIT. The surgical protocol was completed and a laparoscopic cholecystectomy was scheduled with a mirror arrangement of the trocars.

CASE REPORT

Female patient, 51 years old, normal weight according to BMI, denies a history of chronic degenerative disorders, allergies, or drug addictions, G2A1P1, during pregnancy the presence of SIT is discovered, without association with other malformations or any symptoms that affect daily life. For the past 3 years, she has reported having multiple symptoms of pain in the left hypochondrium associated with the ingestion of cholecystokinetic, sometimes accompanied by nausea, without vomiting, without other accompanying symptoms. She has required admission to the emergency area where the pain subsides with analgesics.

However, USG is performed, which reports the presence of gallbladder stones, without signs of exacerbation, surgical protocol is carried out with laboratories control, which are reported without alterations, evaluations are requested by cardiology that reports a normal electro cardiogram in dextrocardia as an anatomical variant, without cardiac structural malformation, granting low surgical risk, without contraindication for the procedure, simple and contrasted CT is requested to document the presence of the SIT, since the patient only had a chest X-ray where dextrocardia was observed. At the appointment prior to surgery, imaging studies are reviewed and during the physical examination it is confirmed that the heart sounds are present without alterations but on the right side, on abdominal palpation no visceromegaly is found and an intentional attempt is made to palpate the edge of the liver, finding it towards the left side, the rest of the examination was found without alterations. Having a complete protocol, a laparoscopic cholecystectomy was scheduled. For the surgical procedure, general anesthesia was administered without complications, the layout of the operating room was changed, placing the laparoscopy tower on the left of the patient, the surgeon and the camera assistant were placed on the right side of the patient, the second assistant and the surgical nurses stood on the left side. The surgeon in charge of performing the cholecystectomy was left-handed, the rest of the surgical team were right-handed.

Prophylactic antibiotics are administered 30 minutes before the incision, with the patient in the supine position and under balanced general anesthesia asepsis, antisepsis and placement of sterile fields are performed in a standardized manner. Subsequently, a supraumbilical incision and pneumoperitoneum are performed using the verse technique and the first 12 mm port is placed, the cavity is entered and under direct vision organs are observed in an abnormal position, finding the spleen, stomach and segments of the liver on the right side, gallbladder and rest of the liver on the left side, thus confirming the diagnosis of SIT.

The rest of the laparoscopic trocars are placed under direct vision, in the subxiphoid portion slightly lateralized to the left, approximately 2 cm with respect to the midline, a 12 mm trocar is inserted, two 5 mm lateral trocars are placed below the edge costal left midclavicular line and on the left flank anterior axillary line.

Once the trocars are placed, the exploration proceeds and the gallbladder fundus is located, which is taken with a grasper clamp by the second assistant and pulled towards the cephalic portion in the direction of the patient's midline, with the Maryland clamp in the dominant left hand of the surgeon and grasper clamp in the right hand to traction Hartmann's pouch, the anterior and posterior sheet of the peritoneum is dissected until the structures are correctly identified, a critical safety view is performed, a short cystic duct and the presence of 2 cystic arteries are found, 2 staples are placed in the cystic arteries, one proximal and one distal, 3 staples are placed in the cystic duct, one proximal and two distal, and they are sectioned with scissors.

The gallbladder is dissected from the liver with electrocautery and hemostasis is performed. A 10×5 cm gallbladder was extracted, with multiple 4 mm stones per subxiphoid port with extractor forceps, the anatomical specimen was prepared and sent for histopathological study. Without complications, discharged 24 hours after surgery due to adequate post-surgical evolution. In the follow-up consultation carried out 10 days later, the patient reported an adequate recovery and not presented symptoms after surgery. Trocar wounds were observed in an adequate healing process, with no alterations to the physical exploration.

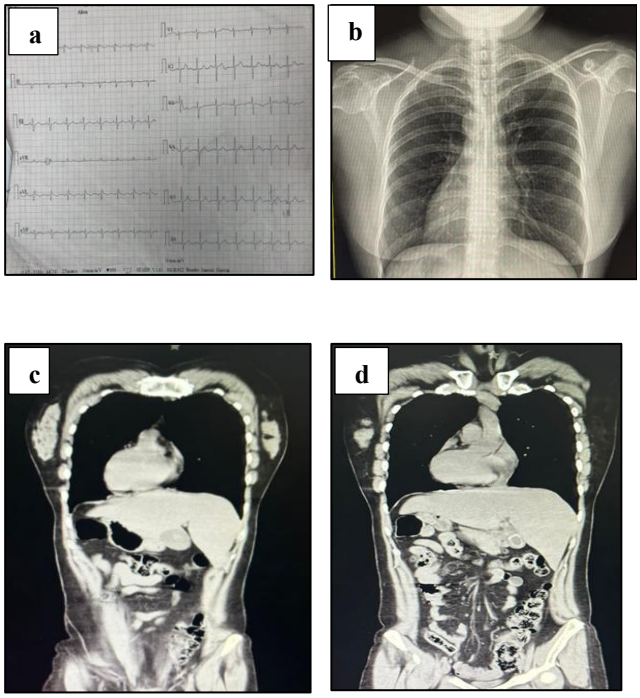

Figure 1 (a-d): Preoperative studies.

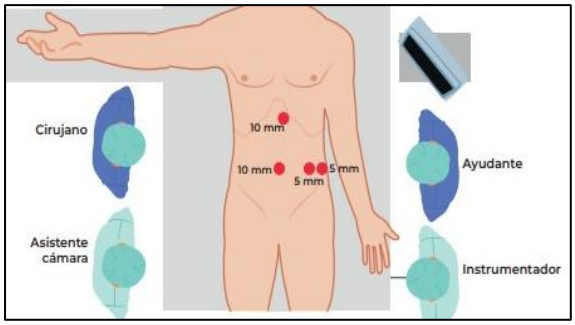

Figure 2: Distribution of surgical team.

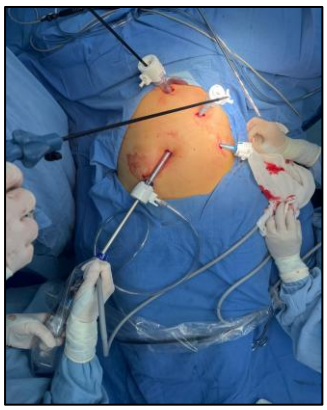

Figure 3: Trocar placement. 12 mm umbilical and epigastric, 5 mm subcostal left midclavicular line and left flank anterior axillary line.

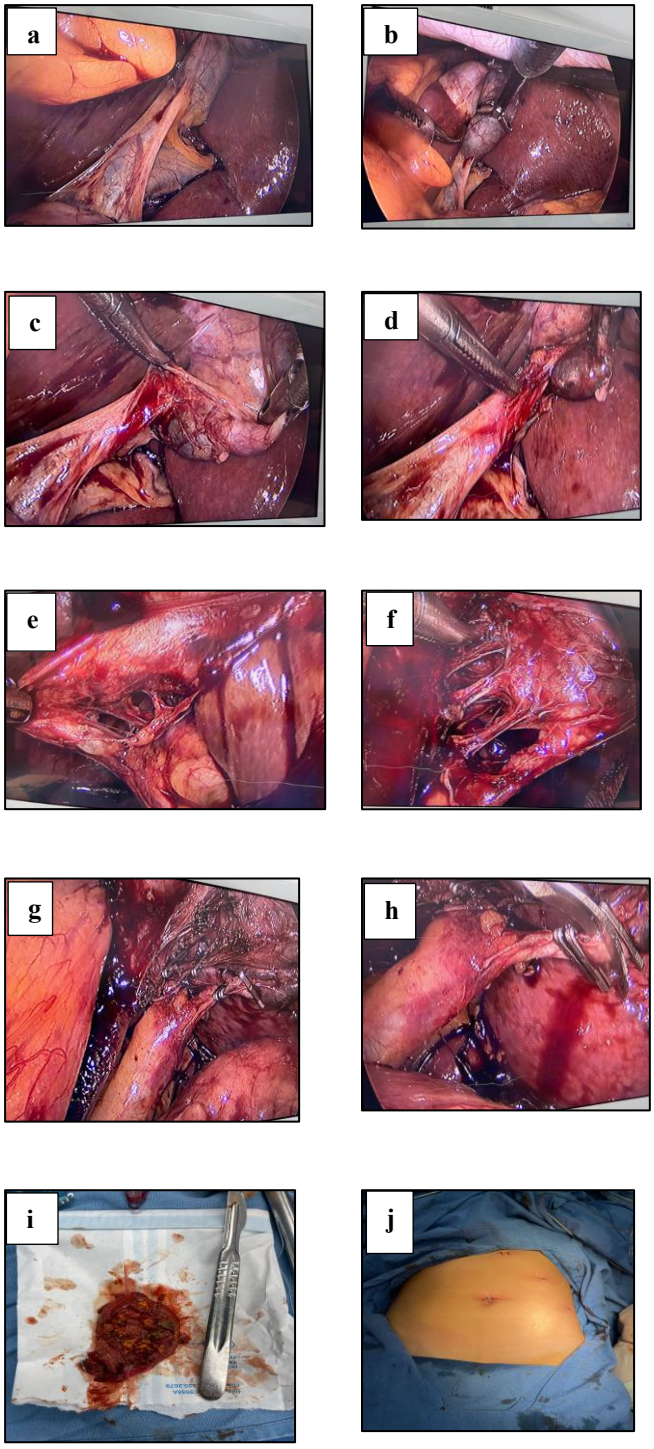

Figure 4: Procedure. (a and b) Cephalic traction of the gallbladder fundus and the arrangement of the dissection clamps. (c and d) Traction of Hartmann's pouch with grasper clamp at the right hand and the dissection of the anterior leaf and adhesions with Maryland clamp at the left hand. (e and f) Visualization of the structures and the entrance to the gallbladder of 3 structures, thus finding 2 cystic arteries. (g and h) Clipping and cutting of structures. (i and j) Gallbladder and abdominal area at the end of the surgery where the distribution of the trocars through the sutures can be observed.

DISCUSSION

SIT is an extremely rare entity, developed during embryogenesis with the transcription factor Pitx2 involved, establishing the left-right axis in the lateral mesoderm and contributing to the asymmetric development of organs such as the heart, small intestine and stomach. When Pitx2 is deleted, normal morphogenesis is disrupted, leading to asymmetric development on the left side of specific visceral organs. The diagnosis of SIT without association with other malformations can be difficult to make and must be confirmed through imaging studies.[3,6,7]

Biliary colic is among the main reasons for consultation worldwide. The diagnosis of patients with cholelithiasis and SIT can be guided by the clinical history and the findings of the physical examination. However, when this is not conclusive or is contradictory, the approach becomes a challenge for health professionals.[1,2] It has not been found that the presence of SIT predisposes to the development of cholelithiasis and the risk of presenting any disease is the same as the rest of the population; however, the characteristics of the presentation are those that represent a challenge for the diagnostic approach.[3,8]

Ten percent to 15% of the population has asymptomatic gallstones. Of these, 20% are symptomatic (biliary colic). Of the 20% who are symptomatic approximately 1% to 4% will manifest complications (acute cholecystitis, gallstone pancreatitis, choledocholithiasis, gallstone ileus), it has been documented that in patients with SIT and lithiasis, 30% will present pain only at the level of the epigastrium, 10% present pain in the right hypochondrium and the rest will present pain in the left upper quadrant, this pain may or may not be associated with nausea, vomiting, fever, organic and biochemical alterations, depending on whether it is chronic or acute and the degree of severity.[2,9,10]

The gold standard treatment for symptomatic gallstones is laparoscopic cholecystectomy, so even in the presence of SIT, this continues to be the treatment of choice. Over the years, a technique has been established that indicates the positioning of the patient, the position of the trocars and safety steps to follow to make this procedure, despite the surgical findings, a safe procedure for the patient and reduce the risks of bile duct injury. Therefore, following all these recommendations, laparoscopic cholecystectomy is considered safe for patients with SIT, but it represents technical challenges.[1,3] The main change in the technique of this procedure is the placement of the trocars and due to its low incidence, there is no established technique. However, different studies report the placement of 12 mm trocars at the umbilical and subxiphoid levels and the 5 mm lateral trocars on the left side, variations to these techniques are documented with the placement of the 5 mm trocar at the subxiphoid level and the 10 mm trocar in the midclavicular line below the costal margin, as well as in the surgeon's place in the French position, placing oneself between the patient's legs. Other challenges to the technique are the dissection due to the change in the trajectory of the bile duct, reporting difficulties due to the interposition of the clamps when trying to dissect with the right hand and with the left traction on Hartman's pouch, so one of the most important variables is the surgeon's ability to be able to perform this dissection with the non-dominant hand in the case of right-handed doctors.[1,3,4]

Different techniques have been tried to describe for performing laparoscopic cholecystectomy in patients with SIT, the most used and the one performed in this case has been reported with the use of 4 trocars, umbilical and epigastric 12 mm and two left laterals of 5 mm, traction by the second assistant of the gallbladder fundus with grasper clamps and traction of Hartman's pouch in the subcostal port with the right hand and dissection with the left hand in the epigastric port, which has been reported as an advantage for left-handed surgeons, as is the case presented in this report. Despite the different variables regarding the approach, an adequate view of the anatomy must be established and a critical safety view performed to reduce the risk of injury to the bile duct, as described in the conventional technique.[1,3,4]

CONCLUSION

In the SIT, special attention must be paid to the physical examination and paraclinical studies to avoid delays in diagnosis, despite the challenge that this may represent, and thus offer the best possible treatment to the patient. Laparoscopic cholecystectomy is considered a safe and effective treatment for patients with cholelithiasis and SIT, however, according to the literature and experience in this case, modifications to the technique and anatomical arrangement represent a challenge for the surgical team. Therefore, an experienced team with extensive knowledge of biliary anatomy is required to avoid the risk of injury. In our case, prior knowledge of the patient's SIT diagnosis allowed us to perform a thorough preoperative evaluation, which ultimately led to a challenging but successful surgical outcome.

Funding: No funding sources
Conflict of interest: None declared
Ethical approval: Not required

REFERENCES

1. Meza MDA, Palomino PJA, Andrade OSJ, Fematt-Rodriguez BJ, Muñuzuri CMA, Gonzalez QA. Overcoming anatomical challenges: laparoscopic cholecystectomy in situs inversus totalis. Cureus. 2023;15:10.
2. Ortega M, Vallecilla G, Mosquera A, Quiñones C. Colecistectomía en paciente con situs inversus totalis. Presentación de caso y revisión de la literatura. Medicina. 2023;45(3):525-32.

3. Enciu O, Toma E, Tulin A, Georgescu D, Miron A. Look beyond the mirror: laparoscopic cholecystectomy in situs inversus totalis-a systematic review and meta-analysis (and report of new technique). Diagnostics. 2023;12(5):1265.
4. Hernández J, Guevara H. Consideraciones técnicas para colecistectomía laparoscópica en paciente con situs inversus totalis: presentación de caso y revisión de la literatura. Cirugía y cirujanos. 2020;88:5-8.
5. García L, Soto L, Payro L, Cabello R. Laparoscopic cholecystectomy in situs inversus: the disadvantage of being right-handed. Revista de Gastroenterología de México. 2008;73(3):149-52.
6. Aljure V, Álvarez C, Ávila N, Coley A, Ángel O. Situs inversus totalis: revisión de tema con aproximación a la Genética reporte de casos. Revista Colombiana de Cardiologia. 2017;24(1):40-7.
7. Franco D, Sedmera D, Lozano E. Múltiples funciones de Pitx2 en el desarrollo y la enfermedad cardíaca. J Cardiovas Develop Dis. 2017;4(4):16.
8. Pak M, Lindseth G. Risk Factors for Cholelithiasis. Gastroenterol Nurs. 2016;39(4):297-309.
9. Hassler KR, Collins JT, Philip K, Jones MW. Laparoscopic cholecystectomy. StatPearls Publishing. 2023. Available at: https://www.ncbi.nlm.nih.gov. Accessed on 17 March 2024.
10. Schirmer B, Winters K, Edlich R. Cholelithiasis and cholecystitis. J Long Term Eff Med Implants. 2005;15(3):329-38.

Cite this article as: Sosa MC, Sosa RH, González YG. Laparoscopic mirror cholecystectomy: gallbladder lithiasis in a patient with situs inversus. Int J Res Med Sci 2024;12:3892-6.