

## Case Report

# Massive nodular melanoma scalp: a case report

A. Bhagya Lakshmi<sup>1\*</sup>, P. V. Sudhakar<sup>2</sup>, M. Shamili<sup>1</sup>, R. Subhash<sup>1</sup>

<sup>1</sup>Department of Pathology, Andhra Medical College, Visakhapatnam, Andhra Pradesh, India

<sup>2</sup>Department of Plastic Surgery, Andhra Medical College, Visakhapatnam, Andhra Pradesh, India

**Received:** 02 February 2015

**Accepted:** 19 February 2015

**\*Correspondence:**

Dr. A. Bhagya Lakshmi,

E-mail: dr.a.bhagyalaxmi@gmail.com

**Copyright:** © the author(s), publisher and licensee Medip Academy. This is an open-access article distributed under the terms of the Creative Commons Attribution Non-Commercial License, which permits unrestricted non-commercial use, distribution, and reproduction in any medium, provided the original work is properly cited.

### ABSTRACT

Melanoma is responsible for 1% to 2% of all cancer deaths around the world. Nodular melanoma often carries a poor prognosis because of no prodromal radial growth phase, early distant metastasis and significant tumour volume. We present a case of nodular melanoma measuring 20x10x8 cm in 28 year old tribal women.

**Keywords:** Nodular, Scalp, Melanoma

### INTRODUCTION

Melanoma is a neoplasm derived from melanocytes of the skin and other sites. It accounts for 1% to 3% of all malignancies and 1% to 2% of all cancer deaths worldwide. The worldwide incidence rate is increasing much more rapidly than for any other malignancies.<sup>1</sup> Nodular melanoma is known to present with greater thickness than the other subtypes of melanoma, therefore, it often carries a poorer prognosis.<sup>2</sup> We present a case of nodular melanoma in 28 year female patient presented with rapid increase in the size of the lesion associated with metastasis to the regional lymph nodes.

### CASE REPORT

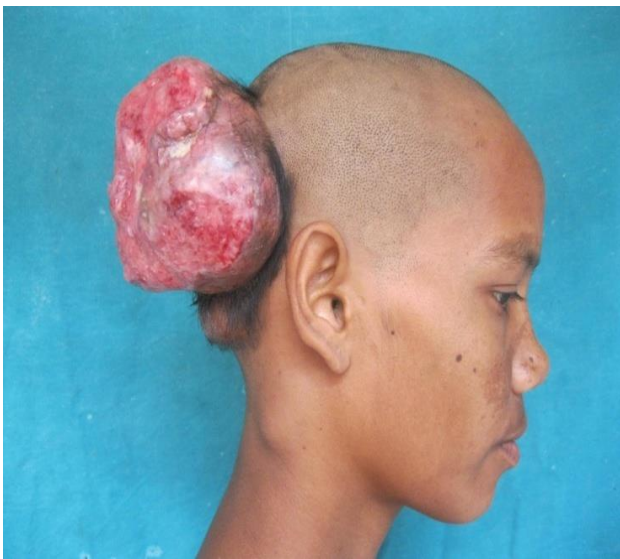A 28 year old tribal woman presented with swelling over the occipital region towards right side for two years. The swelling increased rapidly for the last two months associated with pain and ulcerated one month prior to admission.

Examination revealed ulceroproliferative growth of 20x10 cm occupying the occipital region predominantly on the right side and fixed to underlying bone (Figure 1).

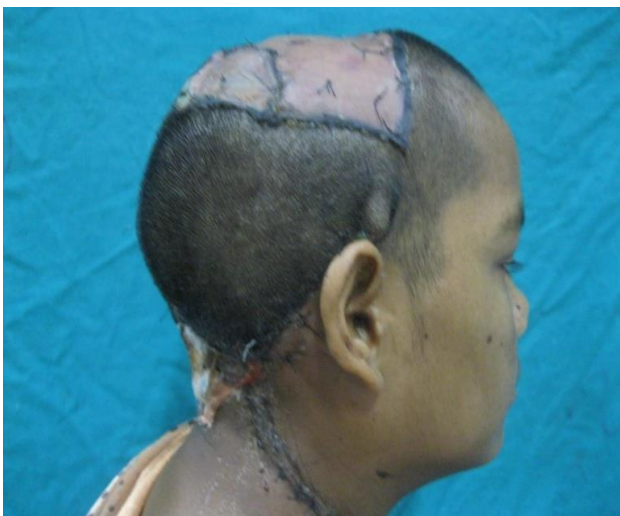There is a 3x5 cm swelling in the neck indicating the involvement of posterior group of cervical lymph nodes. CT scan revealed adherence of the tumour to occipital bone but there was no intracranial extension. FNAC of cervical lymph nodes revealed sheets of pleomorphic malignant cells in the background of lymphocytes and red cells. The possibility of poorly differentiated carcinoma or melanoma was offered. Patient was duly investigated and was negative for distant metastatic work up. The lady was taken up for surgery. Wide excision of the tumour was done under general anesthesia along with craniotomy, duroplasty and radical neck dissection was carried out. Reconstruction was performed by scalp transposition flap and skin grafting (Figure 2). Post-operative period was uneventful. Patient was discharged two weeks after surgery in a fair condition. Advised regular follow up. We could follow the case for two months as the patient was lost to follow up.

The excised gross nodular mass was measuring 20x10x8 cm with surface ulceration and adjacent skin (Figure 3). Cut section is grey white with foci of brownish black areas (Figure 4). Radical neck dissection mass was measuring 12x8x5 cm with muscle and lymph nodes with largest lymph node measuring 4x3x2 cm. Cut section of

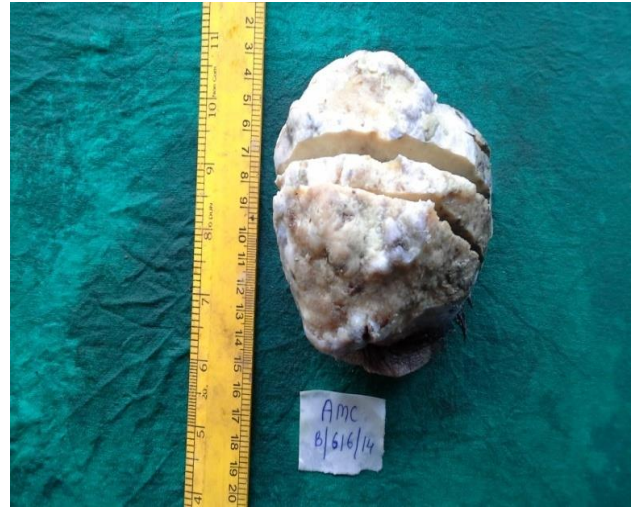the lymph node is grey white with foci of brownish black areas (Figure 5). Multiple sections from the nodular mass and neck dissection specimen are processed. Sections from the nodular mass show squamous epithelium with surface ulceration and tumour composed of sheets of pleomorphic round to polygonal and spindle cells separated by fibrovascular stroma which is infiltrated with lymphocytes. Individual tumour cells have pale eosinophilic cytoplasm, pleomorphic vesicular nuclei and prominent nucleoli. There are foci of necrosis and some of the tumour cells show melanin pigment. Histological features were consistent with melanoma (Figure 6 to 10). Tumor cells are strongly positive to IHC marker Melan A/MART-1, (Figure 11) confirming the diagnosis of melanoma. Sections from the neck lymph nodes show melanoma secondary deposits.



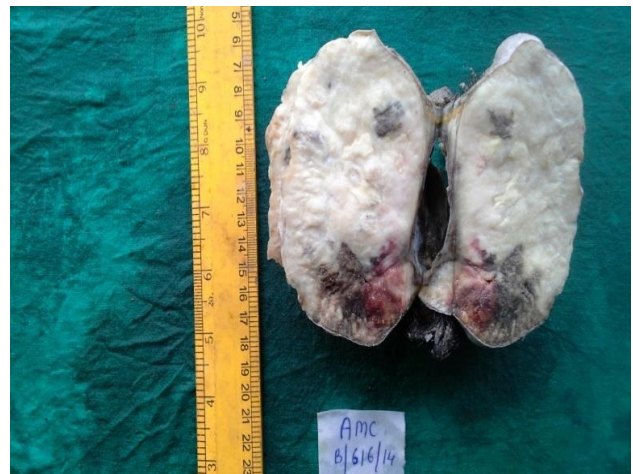**Figure 1: Clinical photo of woman presented with ulcerative swelling of size 20x10 cm occupying the right occipital region.**



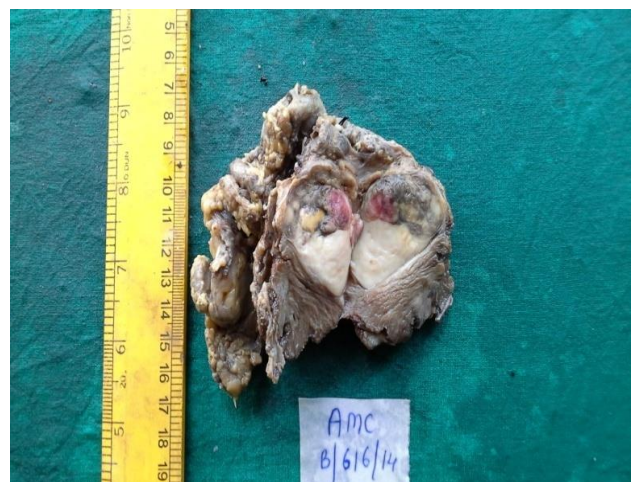**Figure 2: Post-operative clinical photo after skin grafting.**



**Figure 3: Gross appearance of tumor measuring 20x10x8 cm with surface ulceration.**

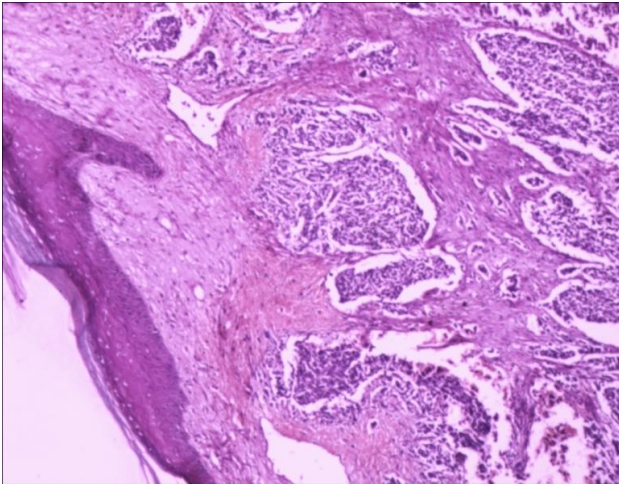


**Figure 4: Cut section of the specimen shows greyish white areas and foci of brownish black areas.**

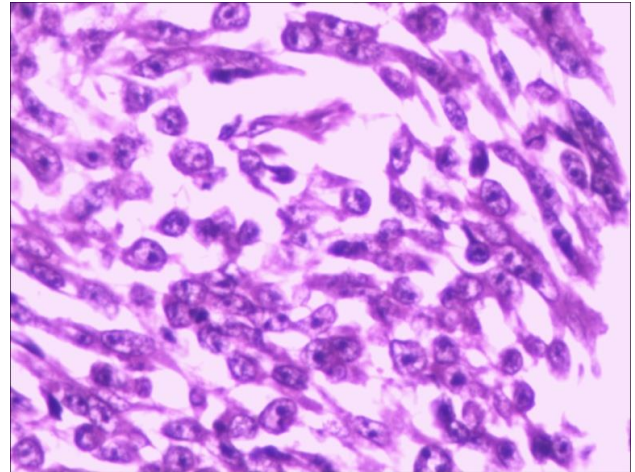


**Figure 5: Cut section of the cervical lymph node with adjacent muscle bundle greyish white areas with foci of brownish black discoloration.**

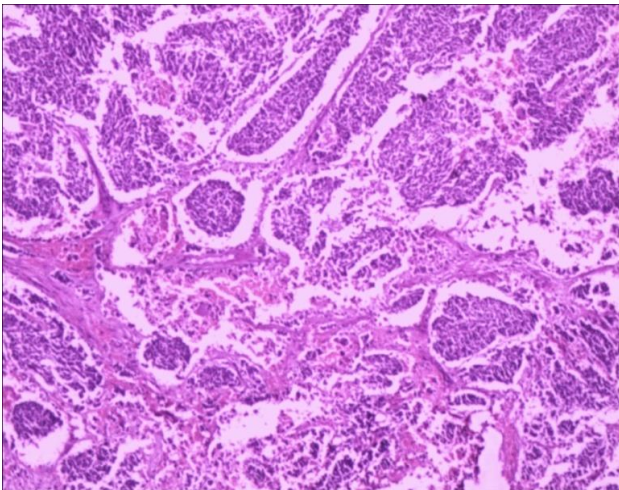




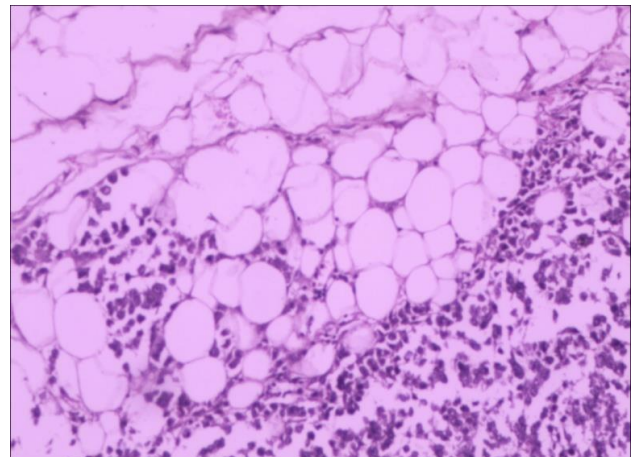
**Figure 6:** Photomicrograph showing surface squamous epithelium, subepithelial nests of pleomorphic tumor cells (H&E; 100x).



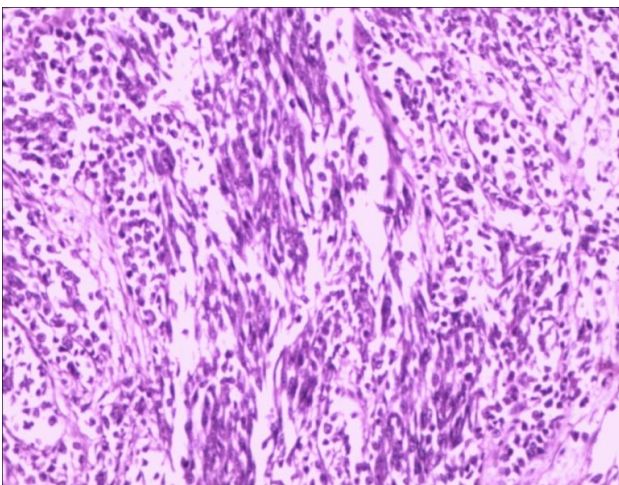
**Figure 9:** Photomicrograph showing markedly pleomorphic tumor cells with vesicular nuclei, prominent eosinophilic nucleoli and occasional mitotic figures. (H&E; 400x).



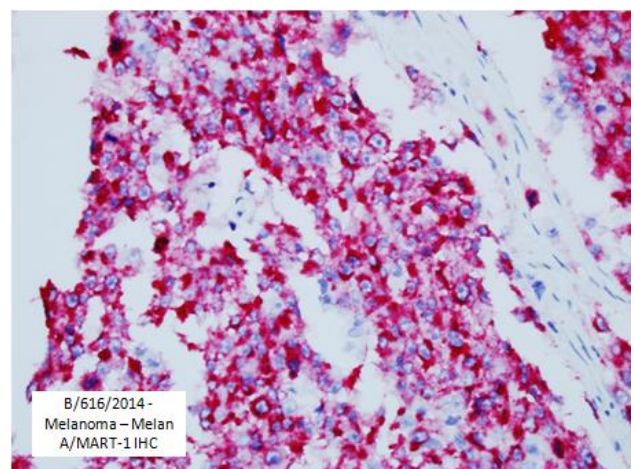
**Figure 7:** Photomicrograph showing pleomorphic tumor cells with foci of necrosis (H&E; 100x).



**Figure 10:** Photomicrograph showing tumour cells infiltrating into the adjacent fibrofatty tissue (H&E; 100x).



**Figure 8:** Photomicrograph showing pleomorphic spindle cells with hyperchromatic nuclei (H&E; 100x).



**Figure 11:** Immunohistochemistry showing strong positivity for Melan-A/Mart-1 in tumor cells.

## DISCUSSION

Nodular melanoma often presents as an expanding darkly pigmented cutaneous nodular lesion, usually found on the sun exposed areas of the skin, with far fewer such lesions occurring in covered areas. The most common sites are the trunk in men and the legs in women. The lesion is usually asymmetric with irregular borders, but it may also present as a round to globoid exophytic mass of varying size. In our case, tumour presented on the occipital area as an exophytic nodular mass with surface ulceration.<sup>3</sup> Metastatic melanoma usually involves draining lymph nodes and occasionally adjacent skin first, but eventually metastasizes to distant visceral sites. The skin and subcutaneous lymph nodes (59%) are most commonly involved followed by lung (36%), brain (20%), liver (20%), bone (17%) and others (12%). In our case only regional lymph nodes are enlarged without any radiological evidence of metastasis in other organs.<sup>4</sup>

Mutations in BRAF and NRAS genes have been reported at a high frequency in cutaneous melanoma, although not much is known about the relationship between these alterations and tumor cell proliferation or disease progress in established melanomas. In the study by Davies et al., BRAF was mutated in 29% of the primary tumors, compared with 27% for NRAS, and the mutations were mutually exclusive in all but one single case. There was a high degree of concordance between primary tumors and paired metastases with respect to mutations in both genes.<sup>5</sup>

Given the rarity of giant melanomas, it is difficult to draw any conclusions for the staging and management strategy. Consequently, there is no validated therapeutic approach. Giant melanomas are often associated with a very poor prognosis. The reason for local or loco-regional spread in some massive melanomas without distant metastases is unknown, although some authors have suggested that it could be ascribed to the intrinsic biological behavior of the tumor and patient's immunological response to the melanoma cells.<sup>6</sup>

## ACKNOWLEDGMENTS

We thank Dr. Nagarjun, Associate Professor, Pathology, Medical College of Wisconsin, Milwaukee, WI for providing us IHC marker studies with images and encouraged us to write the case report.

*Funding: No funding sources*

*Conflict of interest: None declared*

*Ethical approval: Not required*

## REFERENCES

1. Burton RC, Coates MS, Hersey P, Roberts G, Chetty MP, Chen S, et al. An analysis of a melanoma epidemic. *Int J Cancer*. 1993;55:765-70.
2. Bergenmar M, Ringborg U, Mansson Brahme E, Brandberg Y. Nodular histogenetic type the most significant factor for thick melanoma: implications for prevention. *Melanoma Res*. 1998;8:403-11.
3. Mandy Harting, Williams Tarrant, Craig A. Kovitz, Ted Rosen, Matthew T. Harting, Eduardo Souchon. Massive nodular melanoma: a case report. *Dermatol Online J*. 2007;13 (2): 7
4. Balch CM, Soong SJ, Murad TM, Smith JW, Maddox WA, Durant JR. A multifactorial analysis of melanoma. Prognostic factors in 200 melanoma patients with distant metastases (stage III). *J Clin Oncol*. 1983;1:126-34.
5. Lars A. Akslen, Sabrina Angelini, Oddbjørn Straume, Ingeborg M. Bachmann, Anders Molven, Kari Hemminki, et al. *J Invest Dermatol*. 2005;125:312-7.
6. Nicola di Meo, Giuseppe Stinco, Alessandro Gatti, Enzo Errichetti, Serena Bonin, Antonio Albano, et al. Giant melanoma of the abdomen: case report and revision of the published cases. *Dermatol Online J*. 2014;20(7):10.

DOI: 10.5455/2320-6012.ijrms20150439

**Cite this article as:** Bhagya Lakshmi A, Sudhakar PV, Shamili M, Subhash R. Massive nodular melanoma scalp: a case report. *Int J Res Med Sci* 2015;3:1002-5.