

## Case Report

# Dysplasia epiphysealis hemimelica (Trevor's disease): a rare case report with oral manifestations

Asha ML<sup>1</sup>, Nagaraj BN<sup>2</sup>, Arun Kumar G<sup>3\*</sup>, Ashok ML<sup>4</sup>

<sup>1</sup>Professor and Head of the Department, Department of Oral Medicine and Radiology, Dr. Syamala Reddy Dental College Hospital and Research Centre, Bangalore-560037, Karnataka, India

<sup>2</sup>Orthopedic Surgeon, Department of Emergency Medicine, Vyedehi Institute of Medical Sciences, Bangalore, Karnataka, India

<sup>3</sup>P.G. Student, Dr. Syamala Reddy Dental College Hospital and Research Centre, Bangalore-560037, Karnataka, India

<sup>4</sup>Assistant Professor, Department of Internal Medicine, Bangalore Medical College Hospital and Research Institute, Bangalore, Karnataka, India

**Received:** 18 February 2015

**Accepted:** 08 March 2015

### \*Correspondence:

Dr. Arun Kumar G,

E-mail: arunkumarg11061987@gmail.com

**Copyright:** © the author(s), publisher and licensee Medip Academy. This is an open-access article distributed under the terms of the Creative Commons Attribution Non-Commercial License, which permits unrestricted non-commercial use, distribution, and reproduction in any medium, provided the original work is properly cited.

## ABSTRACT

Dysplasia epiphysealis hemimelica, also known as Trevor's disease, is an extremely rare skeletal developmental disorder of unknown etiology, characterized by an osteocartilaginous outgrowth of one or more epiphyses or of a tarsal bone during childhood. It is a rare skeletal hemimelica disorder characterized by asymmetric growth of cartilage in one or more epiphyses. Due to the unusual presentation and variability of the picture, there is no standardized treatment and outcome is very different. Also such an unusual, unique case with craniofacial manifestations has not been reported in the literature. We report a case of a 14-year-old male, who complained of irregularly placed teeth in upper and lower front teeth region. On general physical examination we noticed some skeletal abnormalities with the patient and hence we subjected him to radiographic investigations. The images were consistent with epiphyseal dysplasia hemimelica. The prognosis of DEH is variable and depends basically on its location and size. Carriers of this unusual dysplasia should be periodically monitored for the risk of recurrence.

**Keywords:** Epiphyseal dysplasia hemimelica, Epiphysis, Trevor's disease

## INTRODUCTION

Dysplasia Epiphysealis Hemimelica (DEH) is a rare developmental disorder of the skeleton characterized by asymmetric osteochondral overgrowth of the cartilage of a medial or lateral epiphysis, or epiphyseal equivalent. Historically, DEH has been referred to by many names. It was originally described as "tarsomegalie" in 1926 by Mouchet and Belot.<sup>1</sup> In 1950 Trevor used the name tarso-epiphysial aclasis, and this abnormality is also commonly referred to as Trevor's disease.<sup>2</sup> Subsequently, in 1956 Fairbank<sup>3</sup> coined the current most frequently used term dysplasia epiphysealis hemimelica (hemi-half and melos-

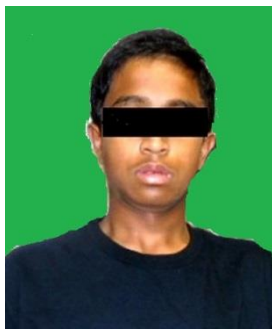limb). According to Fair-bank, DEH refers to a developmental disorder, which is confined to the medial or lateral half of an epiphysis of a single limb.

DEH has an incidence of one per million, with a male to female ratio of 3:1. The knee and ankle are most frequently affected.<sup>4</sup> The condition may be classified based on the degree of involvement into localized (affecting a single epiphysis, usually in the hind foot or ankle), classical (affecting more than one epiphysis of the same limb, and seen in two thirds of cases) or generalized (involving an entire limb), according to the classification given by Azouz et al. in 1985.<sup>5</sup> There is a little evidence

to suggest that DEH is a hereditary disorder. There has neither been a report of malignant transformation of DEH lesion nor a case report with particular emphasis on craniofacial and dental malformations. According to our knowledge, this is the first description of DEH in the Indian literature.

### CASE REPORT

A 14 year old Male patient reported to the department of oral medicine and radiology, with a chief complaint of forwardly placed lower jaw since childhood. His main concerns were difficulty in mastication and his appearance; hence he visited the dental OPD for treatment. The patient gave a medical history of deformity of right hand and was able to get only limited range of motion. Past dental history was not significant. After taking a brief family history he revealed that his great grandfather was a dwarf and his parents were apparently normal. On general physical examination, we noticed that there is disproportionate skeletal growth on comparison with right and left upper limb of the patient. We noticed a mesomelic type shortening of right upper limb. The left upper limb was apparently normal (Figure 1, 2 and 3).



**Figure 1: Frontal profile picture of the patient.**

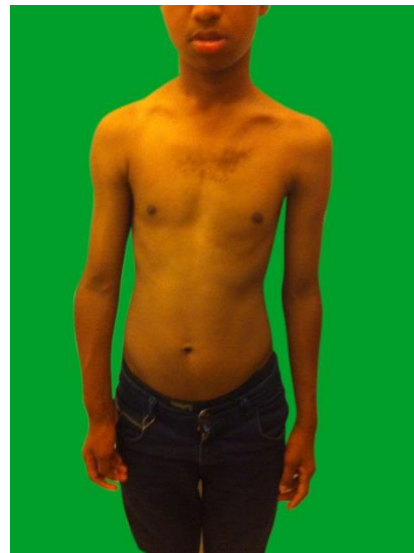

**Figure 2: Disproportionate skeletal growth on comparison with right and left upper limb of the patient.**

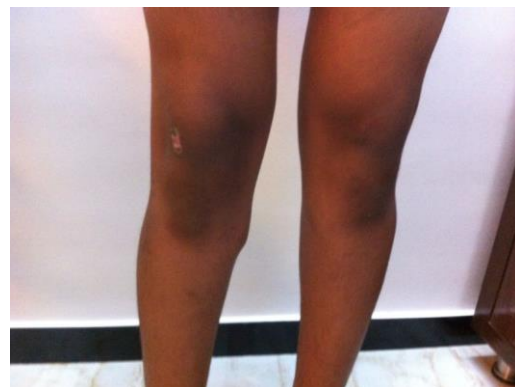

**Figure 3: Mesomelic type shortening of right upper limb with apparently normal left upper limb.**

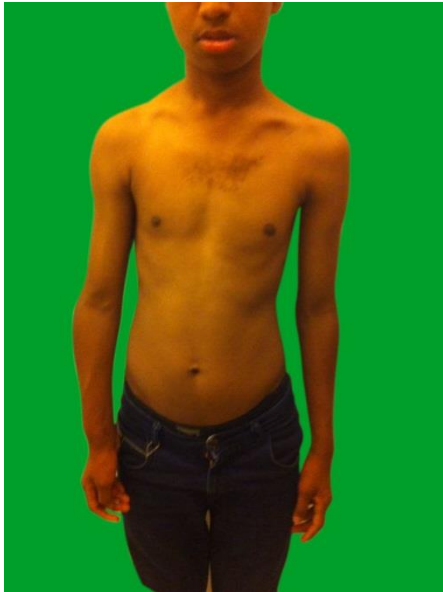On physical examination, a painless and hard protruded mass could be palpated on the dorsomedial aspect of the right ankle region. There were no sinuses, skin changes or bruit over the swelling (Figure 4). Another painless and hard protruded mass could be palpated on the dorsomedial aspect of the right tibial region (Figure 5). There was limb length discrepancy in relation to left third toe (Figure 6).



**Figure 4: Hard protruded mass could be palpated on the dorsomedial aspect of the right ankle region.**



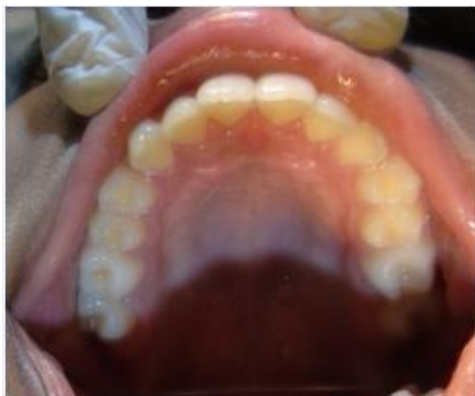**Figure 5: Painless and hard protruded mass could be palpated on the dorsomedial aspect of the right tibial region.**



**Figure 6: Limb length discrepancy in relation to left third toe.**

***Intra-oral findings***

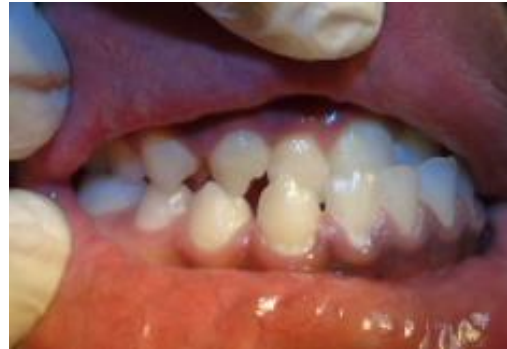A diffuse greyish blue pigmentation was seen on the palate, roughly oval in shape with diffuse borders, extending from 1 cm below the incisive papilla to 1 cm from the junction of hard and soft palate. Medio laterally, it is symmetrical around the midpalatine raphae (Figure 7).



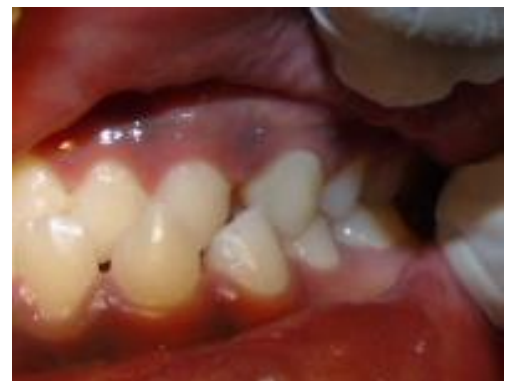**Figure 7: A diffuse greyish blue pigmentation was seen on the palate which is symmetrical around the midpalatine raphae.**

Intra-oral examination revealed retrognathic maxilla with class III malocclusion on both right and left sides (Figure 8, 9 and 10).

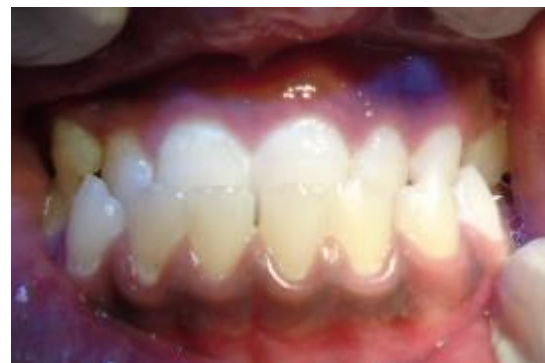Radiographs were advised for the patient. His OPG showed multiple impacted teeth in relation to 13, 14, 15, 23, 25 and 45 (Figure 11). The lateral cephalometry of the patient was taken and it showed mandibular deficiency (Figure 12).



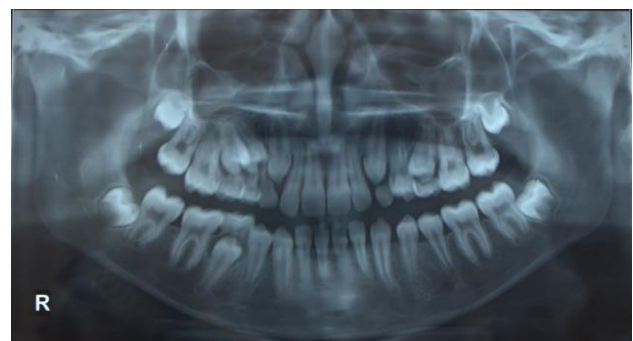**Figure 8: Class III malocclusion on right side.**



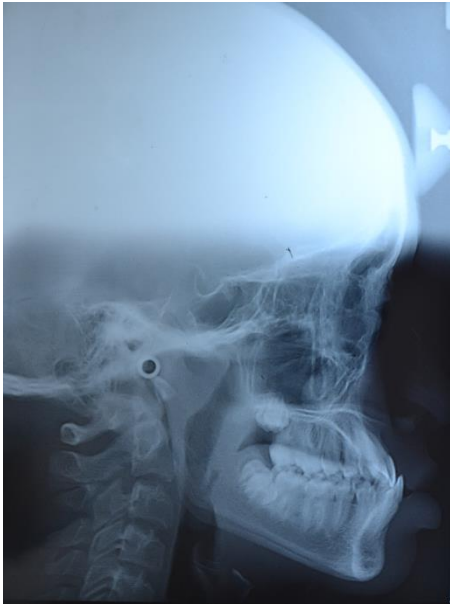**Figure 9: Class III malocclusion on left side.**



**Figure 10: Retrognathic maxilla with Class III malocclusion.**

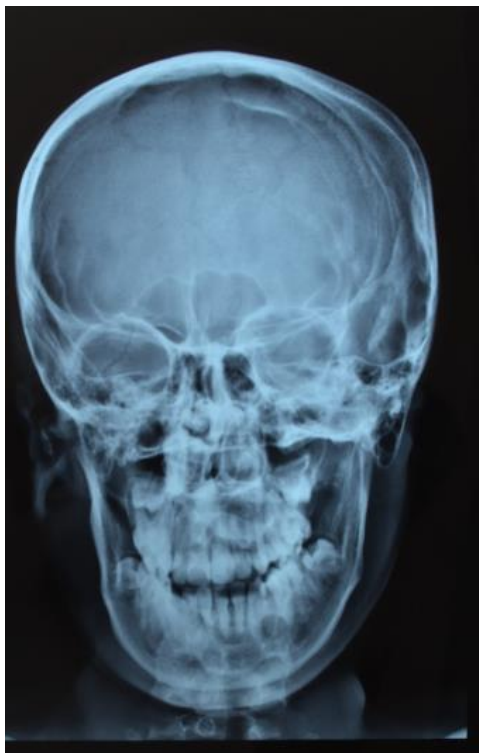

**Figure 11: Patient's OPG showing multiple impacted teeth in relation to 13, 14, 15, 23, 25 and 45.**

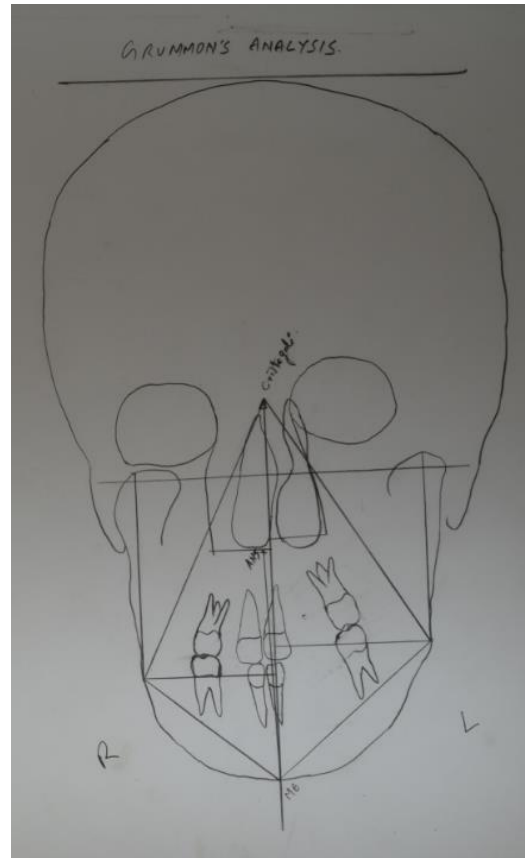


**Figure 12: The lateral cephalometry of the patient showing mandibular deficiency.**

The PA view of the patient showed facial asymmetry in relation to left half of the face (Figure 13). To confirm, Grummon's analysis was done on PA view, which showed that dental midline was shifted towards right side and skeletal midline was shifted towards left side of the patient. Also there was a shift in the cant of occlusal plane towards left side suggestive of both skeletal and dental asymmetry (Figure 14).

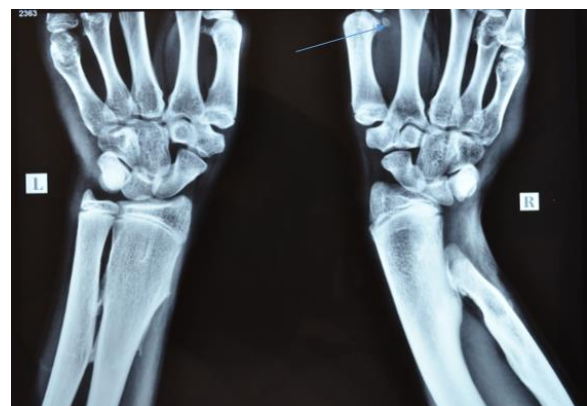


**Figure 13: The PA view of the patient showing facial asymmetry in relation to left half of the face.**



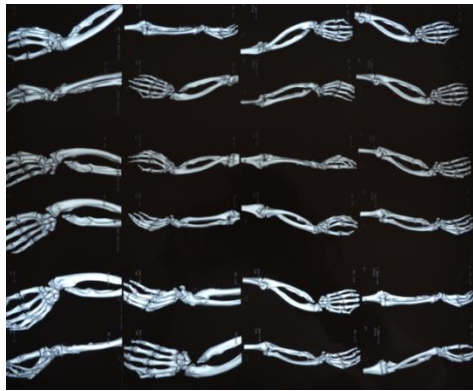**Figure 14: Grummon's analysis done, showing that dental midline was shifted towards right side and skeletal midline was shifted towards left side of the patient. Also there was a shift in the cant of occlusal plane towards left side suggestive of both skeletal and dental asymmetry.**

The plain X-ray of right upper limb (Figure 15) showed a prepubertal growth spurt, non-appearance of abductor sessamoid, incomplete ossification of epiphysis and diaphysis suggestive of fourth stage of ossification according to Bjork, Grave and Brown in 1972.<sup>6</sup>

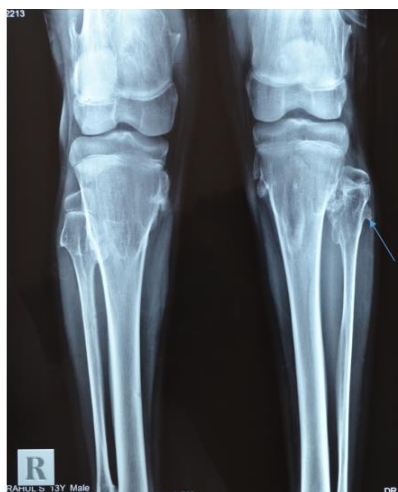

**Figure 15: The plain x-ray of right upper limb showing a prepubertal growth spurt, non-appearance of abductor sessamoid, incomplete ossification of epiphysis and diaphysis.**

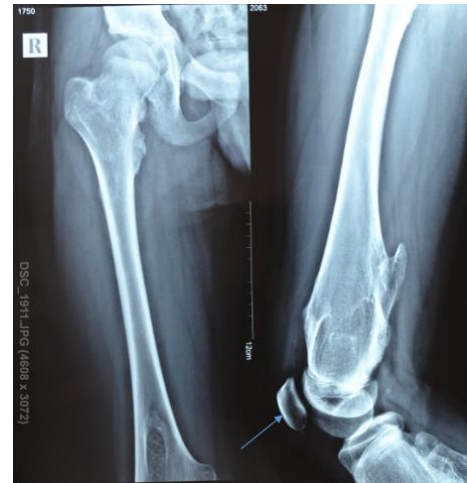The CT of right hand and wrist revealed radial shortening in relation to underdeveloped ulna with carpal wedging, V formation of proximal carpal bones. The growth plate of distal ulna and radius were not fused. Also there were seven carpal bones visualized with non-formation of pisiform bone. Confirming the mesomelic type of shortening with madelung deformity of the right upper limb (Figure 16). The AP X-ray of knee showed irregularities of bony chondral interface of the medial fibial shoulder including foci of inhomogeneous ossification. An osteocartilageneous protuberance was seen in relation to medial aspect of right tibia (Figure 17). The right femur AP radiographs showed an osteoblastic lesion just below the lateral condylar region which is extra-articular (in the epiphysis and tuberosity region) (Figure 18). The chest X-ray of the patient appeared normal (Figure 19). The standard laboratory blood parameters (blood count, coagulation, electrolytes, kidney function tests, liver function tests and thyroid function tests) were all within the normal range.



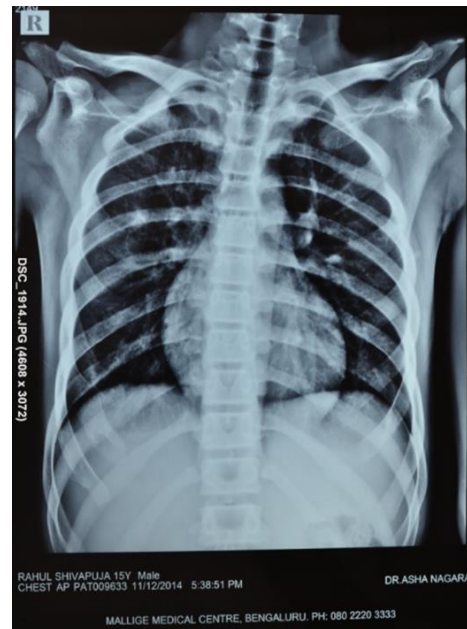**Figure 16: The CT showing mesomelic type of shortening with madelung deformity of the right upper limb.**



**Figure 17: The AP X-ray of knee showing irregularities of bony chondral interface of the medial fibial shoulder including foci of inhomogeneous ossification. An osteocartilageneous protuberance was seen in relation to medial aspect of right tibia.**



**Figure 18: The right femur AP radiographs showing an osteoblastic lesion just below the lateral condylar region which is extra-articular (in the epiphysis and tuberosity region).**



**Figure 19: The chest X-ray of the patient appeared normal.**

The diagnosis of epiphyseal dysphasia hemimelica (extra-articular form) was made on the basis of family history, clinical, radiographic, and according to classification given by Keret et al. in 1992.<sup>7</sup>

The differential diagnosis considered were multiple epiphyseal dysplasia, hematomas, calcified solitary osteochondroma, multiple hereditary exostoses, Ollier disease, tarsal coalition and some malignancies, such as osteosarcoma or chondrosarcoma.<sup>4</sup> The proposed dental treatment for the patient includes oral prophylaxis, facemask with reverse pull headgear therapy to correct skeletal malocclusion. The patient has to be observed for completion of all growth parameters in sagittal and

coronal plane (app.17 years) and then surgical procedure called Lefort 1 osteotomy has to be done for correction of retrognathic maxilla.

The treatment for DEH ranges in literature from simple observation of the asymptomatic lesions to surgical excision. There have been good results with non-operative treatments in the literature. Asymptomatic lesions can be treated non-operatively, as there is no sign of malignant transformation. Surgical treatment is usually indicated when the lesion produces pain, deformity or interferes with the joint motion. Keret et al.<sup>7</sup> divided the lesions into intra and extra-articular and proposed that if the mass is extra-articular, it may simply be excised. Also surgery can be undertaken to correct the deformation or to treat the damages of the articular cartilage. The surgical excision carries the risk of inducing hyperemia and further abnormal bone growth, and may also lead to secondary degenerative changes. Prognosis depends on the site and size of the lesion, the degree of incongruity of involved articular surfaces, as well as the involvement of adjacent structures.

## DISCUSSION

Dysplasia Epiphysealis Hemimelica (DEH), also known as Trevor's disease, is a rare developmental bone disorder with hemimelic involvement of one or more epiphysis in children as a result of overgrowth of cartilage. Although first reported by Mouchet and Belot in 1926 and called "tarsomégalie", it was delineated as a distinct entity by Trevor in 1950.<sup>8</sup> In 1956, Fairbank described the characteristic involvement of either the lateral or medial half of a single limb. He first used the term "dysplasia epiphysealis hemimelica", which appears to be the most logical and frequently used nomenclature. The reported incidence of DEH is 1 in 1000000.<sup>9</sup> However, this estimate may be artificially low since many cases may go unrecognized because of a similar histologic appearance to osteochondroma or because the lesion may be asymptomatic.<sup>10</sup> Children or teenagers are frequently involved, mostly the males in ratio of 3:1.<sup>11</sup> The involvement of the affected epiphysis is hemimelic, meaning that either the medial or the lateral part of the center of ossification is affected and the medial side more commonly. The characteristic hemimelic pathological growth pattern results clinically in painless, bony swelling, deformities, exostoses, limb-length discrepancies, progressive stiffness and articular incongruity. Irregularity of the articular surface may lead to early secondary osteoarthritis.<sup>12</sup> The lesions usually increase in size until the patient reaches skeletal maturity; however, in some cases, enlargement of the lesions was observed in adults.

Different theories have been described to explain HED origin, but none are considered as definitive. They are:<sup>2,3</sup>

1. Irregular cell proliferation in the superficial zone of articular cartilage

2. Changes in apical development button of lower limb
3. Changes in blood epiphysary vessel arrangement
4. Imbalance between proliferation and cellular death mechanism
5. Changes in fetal limb apical ectoderm, resulting in pre or post-axial disorders

CT and arthrography have traditionally been used to define the anatomy of the involved region. It shows the exact location and extent of the lesion, as well as any joint involvement or a potential plane of cleavage between the epiphysis and the pathological tissue.<sup>13</sup> In our case the CT of right hand and wrist revealed radial shortening in relation to underdeveloped ulna with carpal wedging, showing the mesomelic type of shortening with madelung deformity of the right upper limb.

In most cases the diagnosis has been based on plain radiographs,<sup>2,3,5,7</sup> which show the characteristic hemimelic pattern of asymmetrical epiphyseal overgrowth and exostoses of osteochondroma like appearance. Typically, radiographs initially show an irregular mass with focal ossification arising from one side of the affected epiphysis. On maturation, the lesion ossifies and becomes confluent with the underlying bone. In our case the plain radiographs of knee showed irregularities of bony chondral interface of the medial fibial shoulder including foci of inhomogeneous ossification, whereas the right femur AP radiographs showed an osteoblastic lesion in the epiphysis and tuberosity which was extra-articular.

The craniofacial features of the patient include skeletal and dental asymmetry, with class III malocclusion, the features have been first reported. We propose that DEH should also be considered in the list of syndromes with class III malocclusion.

Hence when a patient comes with class III malocclusion, all the skeletal features should be examined to rule out any syndromes which is a crucial step in the prevention and cure of these. Predictable complications arising as a result of these. Dentists will also be able to offer specialized treatment like dental rehabilitation, prevention of diseases of mouth and teeth, as well as dental education targeted to parents.

Trevor's disease is a rare skeletal developmental disorder characterized by asymmetric overgrowth of the cartilage in the epiphyses. There is a lack of literature concerning the diagnosis, oral manifestations, and appropriate dental and medical management of the same. Hence it is important to deepen the knowledge of the disease in order to be acquainted with possible implications on the dental treatment, recognize the type of disability afflicting the patient so as to establish a suitable treatment plan and offer comprehensive and optimum inter-disciplinary treatment to promote the dental health of patients thus afflicted. We hereby attempt to provide a unique, rarest of the case reports ever.

## ACKNOWLEDGEMENTS

My sincere thanks and gratitude to Dr. Asha ML, Head of the Department, Department of Oral Medicine And Radiology for her constant support and encouragement throughout my post-graduate course. A special thanks to Dr. Nagaraj BN, Orthopedic Surgeon, Assistant Professor, Department of Emergency Medicine, Vyedhehi Institute of Medical Sciences, Dr. Ashok ML, Associate Professor, Department of General Medicine, Bangalore Medical College and Research Institute for their support.

*Funding: No funding sources*

*Conflict of interest: None declared*

*Ethical approval: Not required*

## REFERENCES

1. Mouchet A, Belot J. La tarsomegalie. J Radiol Electrol. 1926;10:289-93.
2. Trevor D. Tarso-epiphysial aclasis: a congenital error of epiphyseal development. J Bone Joint Surg Br. 1950;32.B(2):204-13.
3. Fairbank TJ. Dysplasia epiphysialis hemimelica (tarso-epiphysial aclasis). J Bone Joint Surg Br. 1956;38.B(1):237-57.
4. Masquijo JJ, Willis B. Dysplasia epiphysealis hemimelica (Trevor's disease). Arch Argent Pediatr. 2010;108(1):e20-3.
5. Azouz EM, Slomic AM, Marton D, Rigault P, Finidori G. The variable manifestations of dysplasia epiphysealis hemimelica. Pediatr Radiol. 1985;15(1):44-9.
6. Björk A. Timing of interceptive orthodontic measures based on stages of maturation. Trans Eur Orthod Soc. 1972;61-74.
7. Keret D, Spatz DK, Caro PA, Mason DE. Hemimelica epiphysealis dysplasia: diagnosis and treatment. J Pediatr Orthop. 1992;12:365-72.
8. Trevor D. Tarso-epiphysial aclasis. A congenital error of epiphysial development. J Bone Joint Surg. 1950;32:204-13.
9. Segal LS, Vrahas MS, Schwentker EP. Dysplasia epiphysealis hemimelica of the sacroiliac joint: a case report. Clin Orthop Relat Res. 1996;333:202-7.
10. Kuo RS, Bellemore MC, Monsell FP, Frawley K, Kozlowski K. Dysplasia epiphysealis hemimelica: clinical features and management. J Pediatr Orthop. 1998;18:543-8.
11. Baumfeld D, Pires R, Macedo B, Abreu-E-Silva G, Alves T, Raduan F, et al. Trevor Disease (Hemimelic epiphyseal displasia): 12-year follow-up case report and literature review. Ann Med Health Sci Res. 2014;4(Suppl 1):S9-13.
12. Smith EL, Raney EM, Matzkin EG, Fillman RR, Yandow SM. Trevor's disease: the clinical manifestations and treatment of dysplasia epiphysealis hemimelica. J Pediatr Orthop B. 2007;16:97-102.
13. Skaggs DL, Moon CN, Kay RM, Peterson HA. Dysplasia epiphysealis hemimelica of the acetabulum: a report of two cases. J Bone Joint Surg. 2000;82A:409-14.

DOI: 10.5455/2320-6012.ijrms20150444

**Cite this article as:** Asha ML, Nagaraj BN, Arun Kumar G, Ashok ML. Dysplasia epiphysealis hemimelica (Trevor's disease): a rare case report with oral manifestations. Int J Res Med Sci 2015;3:1018-24.