

Research Article

Pattern of lymphadenopathy in fine needle aspiration cytology: a retrospective study

Gayathri MN^{1,*}, Sakshi Chaurasia², Bharathi M³, Shashidhar HB⁴

¹Assistant Professor, ²Postgraduate Student, ³Professor and Head of Department, ⁴Associate Professor, Department of Pathology, Mysore Medical College and Research Institute, Mysore, Karnataka, India

Received: 08 April 2015

Accepted: 07 May 2015

*Correspondence:

Dr. Gayathri M.N,

E-mail: drgayathri1967@gmail.com

Copyright: © the author(s), publisher and licensee Medip Academy. This is an open-access article distributed under the terms of the Creative Commons Attribution Non-Commercial License, which permits unrestricted non-commercial use, distribution, and reproduction in any medium, provided the original work is properly cited.

ABSTRACT

Background: Lymphadenopathy is of great clinical significance as underlying disease may range from treatable infectious etiology to malignant neoplasm. In fact it is also essential to establish that swelling in question is lymph node. Incidence of lymphadenopathy appears to be increasing especially among young adults all over the world. Inflammatory and immune reaction are most frequent cause of lymph node enlargement and are self limiting in majority of cases. Lymphnode are also affected as a result of primary neoplasm or from metastasis of malignant neoplasm from regional and distant organ.

Aims: Study different cytomorphological patterns associated with various lymphadenopathy and spectrum of lesion with respect to age and sex.

Methods: A total of 1774 cases came for FNAC of lymphnode in the Department of Pathology, MMC & RI, MYSORE from NOV 2011 to OCT 2014 were retrieved and studied retrospectively.

Results: Out of total cases, 908 were males and 865 females with age range from 3mth to 90 years with maximum number of cases diagnosed with reactive lymphadenopathy (26.2%) followed by metastatic lymphadenopathy (21.2%), Non specific lymphadenitis (18.5%), granulomatous lymphadenitis (14.65%), tuberculous lymphadenitis (14.65%), suppurative lymphadenitis (3.94%) and lymphoma(0.73%).

Conclusion: FNAC recognized as a diagnostic technique because of simplicity, cost effectiveness, easily availability of results, accuracy and minimal invasion. With the advent of FNAC most of inflammatory, reactive and neoplastic condition can be diagnosed without biopsy.

Keywords: FNAC, Lymphadenopathy

INTRODUCTION

Lymphadenopathy is one of the commonest clinical presentations of patients, attending the outdoor department. Lymph nodes are among the commonly aspirated organ for diagnostic purposes. Since the flourishing of the technique in 1950, the sphere of FNAC has come a long way in conjunction with sophisticated CT, MRI, USG guided procedures to become important diagnostic tool.¹

FNAC is simple and rapid diagnostic technique, because of easily availability of results, simplicity minimal trauma

and absence of complication, aspiration cytology is now considered valuable diagnostic aid. The cytomorphological features collaborates with histopathology and has qualities of micro biopsy.²

Aims & Objectives

The present study is undertaken to study the different cytomorphological patterns associated with various lymphadenopathy and spectrum of lesion with respect to age and sex.

METHODS

In present study, all clinically diagnosed cases of lymphadenopathies reporting at cytology section for FNAC, over a period of 3 years, from NOV-2011 to OCT-2014 were included. Most of the patients were referred from surgery, pediatrics, medicine, dermatology and ENT department.

A brief clinical history followed by a meticulous physical examination was done and findings were noted. These cases were subjected to FNAC and later follow up. A cellular aspirates were excluded from the study. FNAC was conducted with the help of 22 guage disposable

needle attached to a 20cc syringe. Smear were fixed in 95% ethyl alcohol. The smears were stained with Haematoxylin and eosin stain & papanicolaou stain. Leishman stain was done on air dried smear.

RESULTS

Table 1 shows diagnosis of aspirated lesion with age & sex distribution. Reactive lymphadenopathy was the most frequent diagnosis making up 26.2% (465/1774) of the cases. Maximum cases were seen in third decade, with males 908/1774 (51.2%) being slightly more affected than females 865/1774 (48.7%).

Table 1: Diagnosis of aspirated lesion with age and sex distribution.

CYTOLOGICAL DIAGNOSIS	SEX	0-10	11-20	21-30	31-40	41-50	51-60	61-70	71-80	81-90	TOTAL	GRAND TOTAL	PERCENTAGE
Acute Suppurative Lymphadenopathy	M	6	5	7	7	8	2	1	1	1	38	70	3.94
	F	5	3	13	5	1	2	2	0	0	32		
Chronic Granulomatous Lymphadenopathy	M	12	16	28	24	10	6	4	1	0	101	262	14.7
	F	9	28	50	45	14	11	3	0	1	161		
Tuberculous Lymphadenopathy	M	4	15	30	40	10	3	3	0	0	105	260	14.65
	F	5	26	59	30	17	7	5	5	1	155		
Reactive Lymphadenopathy	M	77	67	33	26	21	7	8	2	0	241	465	26.2
	F	41	55	49	32	25	10	10	1	1	224		
Non Specific Lymphadenopathy	M	45	36	34	17	17	12	5	2	1	169	328	18.5
	F	28	36	40	28	12	9	3	3	0	159		
Primary Malignant Lymphadenopathy													
Non-Hodgkin Lymphoma	M	0	1	1	0	1	0	1	3	0	7	10	0.56
	F	0	0	1	0	0	1	1	0	0	3		
Hodgkin Lymphoma	M	1	0	0	0	0	0	0	0	0	1	3	0.17
	F	0	0	2	0	0	0	0	0	0	2		
Metastatic Lymphadenopathy	M	1	0	7	15	48	67	75	26	7	246	376	21.2
	F	0	2	6	19	47	24	28	4	0	130		
		234	290	360	286								

Table 2 shows site and side of lymph node aspirated. The cervical group was the most common site of lymph node aspirated (1324/1774).

Table 2: Site and side of lymph node aspirated.

S.No.	Site	Right	Left	Total
1	Cervical lymph node	700	624	1324
2	Submental lymph node	0	0	60
3	Supraclavicular lymph node	30	55	85
4	Infraclavicular lymph node	10	0	10
5	Occipital lymph node	0	0	5
6	Axillary lymph node	110	90	200
7	Inguinal lymph node	65	25	90
Total				1774

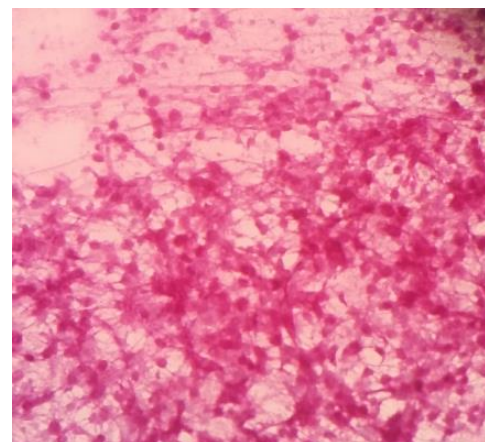


Figure 1: Photomicrograph of smear of lymph node aspirate showing necrosis and granuloma (Haematoxylin and Eosin x400).

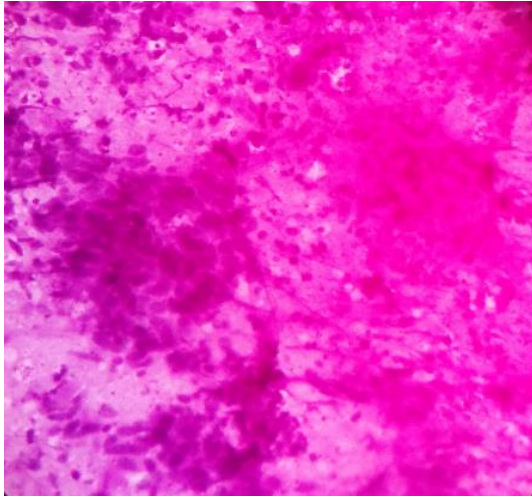


Figure 2: Photomicrograph of smear of lymph node aspirate showing group of malignant squamous cell showing pleomorphism and with hyperchromatic nuclei. (Haematoxylin and Eosin x400).

DISCUSSION

Lymphadenopathy is of great clinical significance as underlying disease may range from treatable infectious etiology to malignant neoplasm and requires accurate diagnosis so that proper treatment protocol can be started as early as possible. Inflammatory and immune reaction are most frequent cause of lymph node enlargement. FNAC is completely safe, quick and inexpensive method for quick diagnosis of lymphadenopathy, reducing need for surgical biopsy.

In the present study 1774 cases for a period of three years were retrieved and studied retrospectively. The pattern of lesion varied from non-neoplastic lesion like tuberculous lymphadenopathy, reactive lymphadenopathy, acute suppurative lymphadenopathy, granulomatous lymphadenopathy and non specific lymphadenopathy, to neoplastic lesion like metastatic lymphadenopathy and lymphoma.

In Our study, reactive lymphadenopathy was observed to be most frequent diagnosis with 465/1774 cases (26.2%). It was also the most frequent diagnosis in other studies and its incidence has been seen to range from 18.9% to 42%.^{1,2,3,4,5}

The Second most frequent diagnosis in this study was observed to be Metastatic Lymphadenopathy with 376/1774 cases (21.2%). This was similar to other Indian studies.^{1,4,8} Other studies have found the incidence of neoplastic involvement to vary from 10.1% to 47.8%.^{1,2,6,7,12} A Brazilian FNAC study on lymph node diagnosed 79.4% Metastatic lymphadenopathy and 14.2% lymphoma.¹³ A study conducted in Egypt has reported more involvement of lymphoma (80.3%) rather than metastatic disease (19.7%).¹⁴

The present study also comprised 328/1774 (18.5%) cases diagnosed as Non Specific Lymphadenopathy. Other studies shows variation in incidence from 2.63% to 35.6%.^{1,11,17}

Chronic Granulomatous Lymphadenopathy was observed to be frequent occurrence with 262/1774 cases (14.7%) in our study. The incidence of granulomatous inflammation was observed to vary from 9.2% to 25.45% in other studied.^{1,2,5}

Tuberculous lymphadenopathy diagnosed by cytology alone occurred in 260/1774 (14.65%) of our cases. Other previous studies showed this condition varying from 7.8% to 52%.^{2,3,4,6,7}

Acute Suppurative Lymphadenopathy comprised 70/1774 (3.94%) cases in our study. This can be correlated with the study of Chawla & Kishore,¹⁸ who found incidence to be 5.3% of all lymph node aspirated.

In our study cervical group was most common to be involved 1324/1774 (74.6%) followed by axillary lymph node. Also cervical group are most common to be involved by metastasis 675/1324 (51%) cases and the primary was most often from the oral cavity, which was similar to other studies^{3,5,15} with Squamous Cell Carcinoma being the most common histological type.^{9,10,15,16} Rates for carcinoma of oral cavity, pharynx, esophagus and male larynx are highest in India, probably due to the use of multiple tobacco products.

CONCLUSION

FNAC is an important diagnostic tool for diagnosing benign as well as malignant lesion.

It is safe, simple, and inexpensive definite diagnostic procedure to render prompt diagnosis especially in lymph node aspirates where biopsies are not done commonly. Also future mode of treatment can be ascertained with in short time which is boon to anxious patient.

Funding: No funding sources

Conflict of interest: None declared

Ethical approval: Not required

REFERENCES

1. Mohanty R, Wilkinson A. Utility of Fine Needle Aspiration Cytology of Lymph Nodes. IOSR-JDMS 2013; 8 :13-18.
2. Hirachand S, Lakhey M, Akhter J, Thapa B. Evaluation of Fine Needle Aspiration Cytology of Lymph Nodes in Kathmandu Medical College Teaching Hospital. Kathmandu University Medical Journal 2009; 7:139-142.
3. Kochhar K, Patel B, Shah M. Pattern of Lymphadenopathy on Fine Needle Aspiration

- Cytology of Superficial Lymph Nodes (A Study of 150 Cases). *JARBS* 2012; 4: 288-292.
4. Khajuria R, Goswami KC, Singh K, Dubey VK. Pattern of Lymphadenopathy on Fine Needle Aspiration cytology in Jammu. *JK Science Journal of Medical Education and Research* 2006; 8:157-159.
 5. Adhikari P, Sinha BK, Baskota DK. Comparison of fine needle aspiration cytology and histopathology in diagnosing cervical lymphadenopathies. *AMJ* 2011; 4: 97-99.
 6. Paul PC, Goswami BK, Chakrabarti S, Giri A, Pramanik R. Fine Needle Aspiration Cytology of Lymph Nodes - An institutional study of 1448 cases over a five year period. *Journal of Cytology* 2004; 21:187-90.
 7. Ahmad T, Naeem M, Ahmad S, Samad A, Nasir A. Fine Needle Aspiration Cytology (FNAC) and Neck swellings in the surgical department. *Journal of Ayub Medical College Abbottabad* 2008; 20:30.
 8. Sarwar A, Haque A, Aftab S, Mustafa M, Moatasim A, Siddique S et al. Spectrum of Morphological Changes in Tuberculous Lymphadenitis. *International Journal of Pathology* 2004; 2:85-89.
 9. Alam K, Khan AH, Siddiqui FA, Jain A, Haider N. Fine Needle Aspiration Cytology (FNAC), a handy tool for metastatic lymphadenopathy. *The Internet Journal of Pathology* 2010;10. Available from: http://www.ispub.com/journal/the_internet_journal_of_pathology.
 10. Bhagwan IN, Kane SV, Chinoy RF. Cytologic Evaluation of the Enlarged Neck Node: FNAC Utility in Metastatic Neck Disease. *The Internet Journal of Pathology* 2007; 6. Available from: http://www.ispub.com/journal/the_internet_journal_of_pathology.
 11. Haque MA, Talukder SI: Evaluation of fine needle aspiration cytology (FNAC) of lymphnodes in Mymensingh. *Mymensingh Med J* 2003; 12:33-5.
 12. Ghartimagar D, Ghosh A, Ranabhat S, Shrestha MK, Narasimhan R, Talwar OP. Utility of fine needle aspiration cytology in metastatic lymph nodes. *Journal of Pathology of Nepal* 2011; 1: 92-95.
 13. Martin MR, Santos GC. Fine Needle Aspiration Cytology in the diagnosis of superficial lymphadenopathy: a 5 year Brazilian experience. *Diagn Cytopathol* 2006; 34:130-134.
 14. Hafez NH, Tahoun NS. Reliability of fine needle aspiration cytology (FNAC) as a diagnostic tool in cases of cervical lymphadenopathy. *Journal of the Egyptian National Cancer Institute* 2011; 23: 105-114.
 15. Hoftr S, Muhle C, Brenner W, Sprenger E, Maune S. Fine-Needle Aspiration Cytology of the Sentinel Lymph Node in Head and Neck Cancer. *J Nucl Med* 2002; 43:1585-90.
 16. Mitra S, Ray S, Mitra PK. Fine needle aspiration cytology of supraclavicular lymph nodes: our experience over a three year period. *J Cytol* 2011; 28: 108-110.
 17. Mohan A, Reddy KM, Phaneendra BV, Chandra A. Aetiology of peripheral lymphadenopathy in adults. *The National Medical journal of India* 2007; 20:78-80.
 18. Chawla N, Kishore S, Kudesia S. FNAC of lymph node disorder. *India Medical Gazette* 2012; 312-315.

DOI: 10.18203/2320-6012.ijrms20150158

Cite this article as: Gayathri MN, Chaurasia S, Bharathi M, Shashidhar HB. Pattern of lymphadenopathy in fine needle aspiration cytology: a retrospective study. *Int J Res Med Sci* 2015;3:1416-9.