

## Case Report

# Round worm infestation in fundus of stomach: a rare case presentation

Sharique Ansari, Nisha Mandhane, Tanveer Parvez Shaikh\*, Sandesh Deolekar,  
Sangram Karandikar

Department of Surgery, DY Patil School of Medicine, Nerul, Navi Mumbai, India

**Received:** 04 April 2015

**Revised:** 24 April 2015

**Accepted:** 06 May 2015

### \*Correspondence:

Dr. Tanveer Parvez Shaikh,

E-mail: drtanny.shaikh@gmail.com

**Copyright:** © the author(s), publisher and licensee Medip Academy. This is an open-access article distributed under the terms of the Creative Commons Attribution Non-Commercial License, which permits unrestricted non-commercial use, distribution, and reproduction in any medium, provided the original work is properly cited.

### ABSTRACT

A case of a 27-year-old female, in whom a 10cm long round worm (*Ascaris lumbricoides*) was found in the fundus of stomach, is reported here. In this patient, *Ascaris lumbricoides* upward migration of the worm to the fundus of stomach, its rare phenomenon, worm mostly seen in the small intestine. This is mainly because of the high gastric acidity. In this patient, we believe proton pump inhibitor (PPI) use caused hypochlorhydria and coexistence *H. pylori* infection caused chronic atrophic gastritis, which resulted in the retrograde migration of the roundworm to the stomach in our patient.

**Keywords:** *Ascaris lumbricoides*, Fundus of Stomach, Proton pump inhibitor, Oesophagogastroduodenoscopy

### INTRODUCTION

*Ascaris lumbricoides*, a nematode, is the most common helminthic infestation in the world. It is prevalent mainly in the Far East, Indian Subcontinent, Latin America and Middle East countries.<sup>1</sup> It usually affects people from the lower socioeconomic groups living in unhygienic conditions. The adult roundworm normally lives in the small intestine. If the worm load is high, more than a few thousands, the worms tend to migrate away from the usual site to lung, peritoneum, urinary bladder and biliary-pancreatic system.<sup>1</sup>

### CASE REPORT

A 27-year-old woman was admitted to our outpatient clinic with a 2-month history of intermittent epigastric pain. Her physical examination and the results of routine blood tests were unremarkable. This patient had treated by proton pump inhibitor for long time. Her abdominal X-ray and abdominal ultrasonography was normal. On

upper gastro duodenal endoscopy, a live roundworm was found (Figure 1 & 2), in fundus of the stomach while doing “J” maneuver. In the upper gastro duodenal endoscopy; there was red antral mucosa with a shiny surface and mild nodularity, which gastric biopsy revealed antral gastritis with *H. pylori* infection. The patient was treated with single dose (600 mg) of praziquantel for *Ascaris lumbricoides* infestation and we decided to follow up the patient for her chronic gastritis. After 1 month, she was symptom free and specific exams showed no trace of the parasite. The patient was given a single dose of praziquantel: 15 mg/kg body weight. The patient got instant relief of her symptoms. Parasitological controls (two series of three fecal samples each), performed two months later, were negative for parasites in stool specimens.

### DISCUSSION

Ascariasis is a helminthic infestation of global distribution with >1.4 billion persons infested throughout the world. An estimated 1.2–2 million such cases with 20

000 deaths occur in endemic areas per year.<sup>2</sup> The highest prevalence of ascariasis occurs in tropical countries where warm and wet climates provide environmental conditions that favour year-round transmission of the disease. More often, recurrent infestations lead to malnutrition and growth retardation in children in endemic areas. Surgical complications due to *Ascaris* are rarer in adults.<sup>3</sup> *Ascaris* is acquired by the ingestion of the embryonated eggs contaminating raw vegetables and fruits. Adult worms inhabit the lumen of the small intestine, usually the jejunum or ileum. Intestinal ascariasis is usually detected as an incidental finding. This can result in a wide range of clinical presentations ranging from asymptomatic worm infestation to intestinal obstruction, perforation, especially ileal, and bleeding.<sup>2</sup>

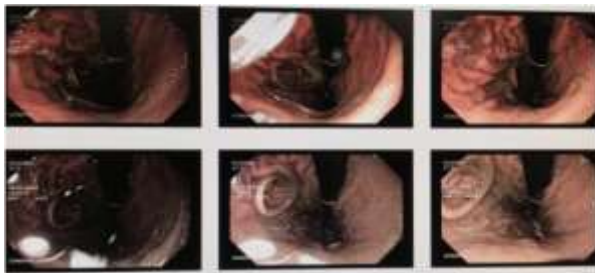


Figure 1: Worms on OGD scopy in fundus.

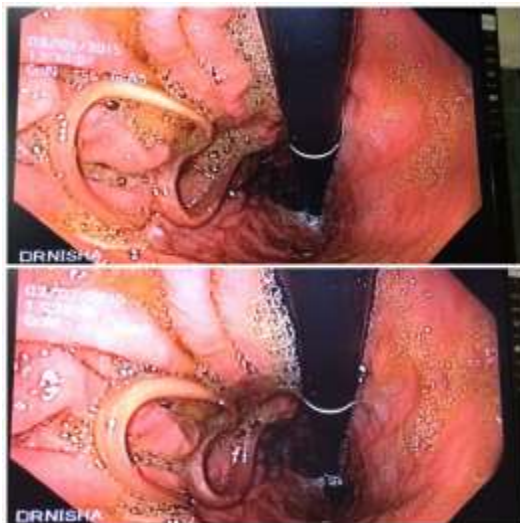


Figure 2: Zoomed in image of worm.

The intestine has an immense capacity for dilatation and can possibly accommodate >5000 worms without any symptoms.<sup>4</sup> The commonest complication of ascariasis is intestinal obstruction due to a worm bolus,<sup>5</sup> especially in children with heavy worm load. The obstruction may be acute or sub acute. The mechanism of obstruction is occlusion of the intestinal lumen by worms packed in distal ileum as well as localized volvulus of a segment of terminal ileum owing to the weight of the worms inside. Gangrene or perforation may occur as a result of pressure necrosis by roundworms or due to localized volvulus. In intestinal ascariasis, the cause of perforation of the small intestine remains controversial. In the tropics, patients

often have associated diseases such as typhoid enteritis, tuberculosis and amoebiasis which are known to cause intestinal ulcerations. Intestinal ulcers can also develop due to Crohn's disease, trauma, lymphoma or non-specific ulceration induced by drugs like non-steroidal anti-inflammatory drugs (NSAIDs). The worm may escape into the peritoneal cavity through perforations at these sites of ulceration.<sup>6</sup> Another possible explanation is that the large worm bolus can lead to pressure necrosis and gangrene.<sup>7</sup> The bowel thus becomes susceptible to perforation by the burrowing action of the worm.<sup>2</sup>

Intussusceptions due to *Ascaris* have also been reported.<sup>8,9</sup> Acute appendicitis and appendicular perforation can occur as a result of worms entering the appendix. Perforation of Meckel's diverticulum has also been reported to be caused by *Ascaris*. Granulomatous peritonitis in ascariasis is reported to be due to the presence of dead adult worms in the peritoneal cavity or caused by reaction to the eggs.<sup>2</sup> Ascariasis should thus be investigated in patients with non-specific abdominal pain or intestinal perforation especially in tropical countries to avoid such potentially fatal complications.

Funding: No funding sources

Conflict of interest: None declared

Ethical approval: Not required

## REFERENCES

1. Sanai FM, Al-Karawi MA. Biliary ascariasis: Report of a complicated case and literature review. Saudi J Gastroenterol 2007;13:25-32.
2. Sarmast AH, Parray FQ, Showkat HI, Lone YA, Bhat NA. Duodenal perforation with an unusual presentation: a case report. Case Rep Infect Dis 2011;2011:512607, Article ID.
3. Iya D, Kidmas AT, Ozoilo K, Sani AA. Gastric perforation and ascariasis: casual or causal relationship. Ann Afr Med 2004;3:161.
4. Louw M. The abdominal complication of adult *Ascaris lumbricoides* manifestations in children. Br J Surg 1966;53:510-21.
5. Basavaraju SV, Hote PJ. Acute GI and surgical complications of *Ascaris lumbricoides* infection. Infect Med 2003;20:154-9.
6. Efem SE. *Ascaris lumbricoides* and intestinal perforation. Br J Surg 1987;74:643-4.
7. Surendran N, Paulose MO. Intestinal complications of round worms in children. J Pediatr Surg 1988;23: 931-5.
8. Karatepe O, Tu'kenmez M, Hu'nerli K, Citlak G, Salmalioglu A, Battal M, et al. *Ascaris* as a leading point for small-bowel intussusception in an adult: a rare cause of intussusception. Am J Emerg Med 2008;26:381. e3-4.
9. Nikolic' H, Palc'evski G, Saina G, Pers'ic' M. Chronic intussusception in children caused by *Ascaris lumbricoides*. Wien Klin Wochenschr 2011; 123:294-6.

10. Peker K, Kilic K. Endoscopic diagnosis in *Ascaris lumbricoides* case with pyloric obstruction. *Turkiye Parazitol Derg* 2011;35:210–3.

DOI: 10.18203/2320-6012.ijrms20150190

**Cite this article as:** Ansari S, Mandhane N, Shaikh TP, Deolekar S, Karandikar S. Round worm infestation in fundus of stomach: a rare case presentation. *Int J Res Med Sci* 2015;3:1554-6.