

## Case Report

# Squamous cell carcinoma in left flank due to saree: Largest reported case

**Nisha Mandhane\*, Tanveer Parvez Shaikh, Sharique Ansari, Sandesh Deolekar,  
Sangram Karandikar, Lokesh Sreedharan, Sheena Ali**

Department of Surgery, DY Patil School of Medicine, Nerul, Navi Mumbai, India

**Received:** 15 May 2015

**Accepted:** 05 June 2015

### \*Correspondence:

Dr. Nisha Mandhane,

E-mail: [drnishanahar@gmail.com](mailto:drnishanahar@gmail.com)

**Copyright:** © the author(s), publisher and licensee Medip Academy. This is an open-access article distributed under the terms of the Creative Commons Attribution Non-Commercial License, which permits unrestricted non-commercial use, distribution, and reproduction in any medium, provided the original work is properly cited.

## ABSTRACT

Saree is a female costume unique for Indian ladies. This includes a superficial cloth and a skirt underneath which is fastened securely to the waist by a cord. Persistent and long term wearing of this costume has resulted in waist dermatoses. Waist dermatoses theoretically may present with malignant transformation. Here we present a case of 60 year old female who presented with left flank ulcer following chronic irritation from saree, biopsy was taken and it showed squamous cell carcinoma (SCC). We decided to do wide excision with tension free suturing. Post operatively the patient followed up for 12 week and has shown to be disease free. This turns out to be the third case being reported and the largest ever to be reported in the literature.

**Keywords:** SCC, Skin malignancy, Saree cancer, Giant SCC, Saree dermatoses

## INTRODUCTION

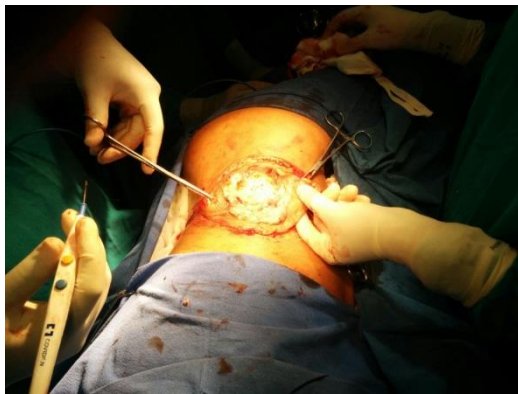
Squamous cell carcinoma (SCC) is the second most common skin malignancy.<sup>1</sup> Dermatoses like allergic and non-allergic contact dermatitis<sup>2</sup> and dermatophytosis<sup>3</sup> are more common in body folds especially when associated with increased sweating. Saree including its skirt can cause chronic irritation along waistline. These tight garments induce various dermatoses along the waist in Indian female patients.<sup>4</sup> This is often aggravated by the hot and humid climate of certain areas. Pigmentation and mild scaling over the waist have become so common in females in India that they have started considering it as normal.<sup>4</sup> After the stage of scaling and pigmentation, it can progress to ulcerative lesion which may be SCC. When lesions are larger than 2 cm in diameter, SCCs can be associated with a greater risk for disfigurement, local recurrence, and metastasis.<sup>5</sup> There are few reported cases of SCCs larger than 5 cm in diameter.<sup>3-11</sup>, but SCC caused by saree is a rare finding. Larger SCCs can be infiltrative and destructive,<sup>6</sup> thereby posing a great challenge for the operating surgeon.<sup>7,8,9</sup> For effective

treatment, it may be necessary to resect affected aesthetic and/or functional structures, which can cause major defects that require complex surgical reconstruction.<sup>8,9</sup> We present a case of left flank dermatoses which over a period of time gave rise to ulcer which turned out to be squamous cell carcinoma and this is a rare presentation.

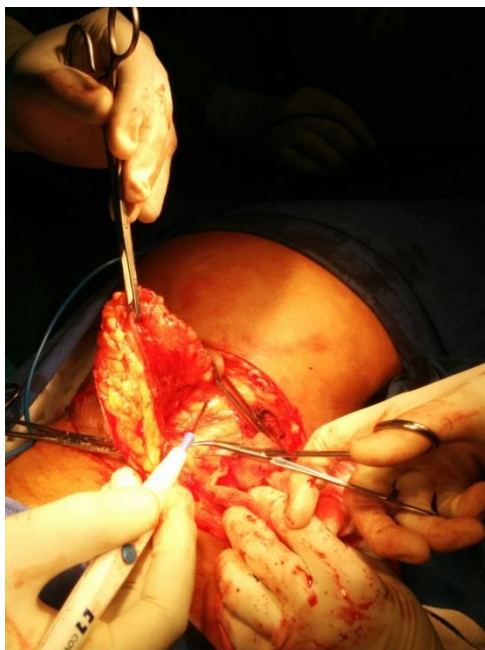## CASE REPORT

Here we present a case of 60 years old female who came to our outpatient department with chief complaints of ulcerative growth in left flank region since 2 years with pain in ulcer and foul smelling discharge since 1 month. There was initially coarsening of skin in left lumbar region after which there was hyperpigmentation of that area which lead to atrophy and hypopigmentation. There was associated burning sensation. This patch of skin gave way to form an ulcer which grew beyond its edges within a span of 2 years. There was initially serous discharge which in past 1 month turned foul smelling. On enquiry patient gave history of wearing tight saree for more than 40 years. She took treatment from the local practitioner

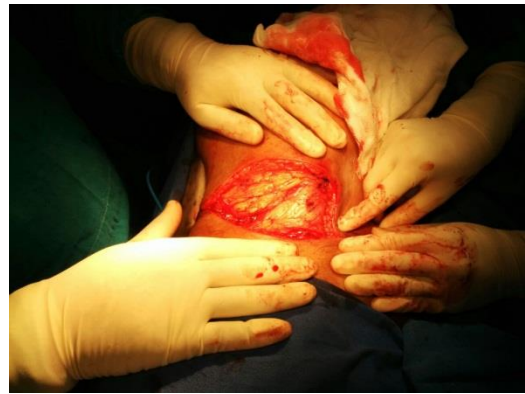and got symptomatic relief. Patient had history of weight loss approximately 5 kg in 3 months. Clinical examination revealed an ulcer measuring 8 cms x 6 cms with everted edges, ill-defined margins and serosanguinous discharge from the ulcer bed (Figure 1). Ulcer was tender on palpation, did bleed on touch. Surrounding skin was hyperpigmented and scaly. Left side nontender, discrete, firm, mobile inguinal lymphadenopathy was present. Patient was admitted in our ward. Edge Wedge biopsy and ultrasonography of abdomen was done. Wedge biopsy report suggested of squamous cell carcinoma. FNAC of left inguinal lymph nodes showed reactive lymphadenitis. Decision was taken to excise the tumor with wide margins and wide excision with 2 cm margin was done, specimen was sent for histopathology (Figure 2, 3, 4). Histopathology report confirmed squamous cell carcinoma with margins free from tumor. Patient was followed after 3 week, 6 week and 12 week with no recurrence and healthy scar line (Figure 5).



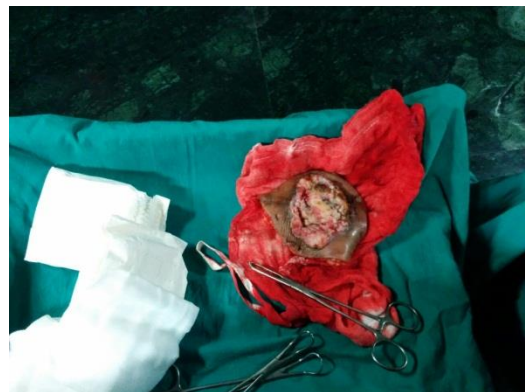**Figure 1: The saree cancer.**



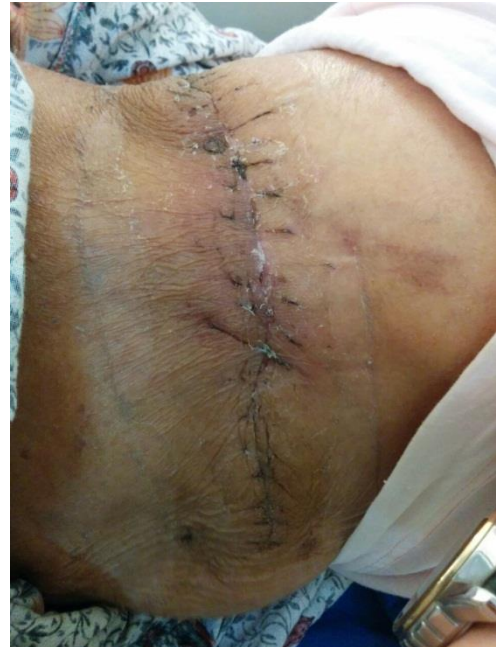**Figure 2: Intra Operative image.**



**Figure 3: After wide excision of SCC.**



**Figure 4: Specimen sent for Histopathology.**



**Figure 5: 3 week post op.**

## DISCUSSION

Till date only 3 cases of saree carcinoma have been reported with largest being 8x5 cms<sup>10</sup> and smaller one 7x5 cms.<sup>11</sup> Here we are reporting the largest saree carcinoma measuring 8x6 cms. Squamous cell carcinoma accounts for

approximately 20% of cutaneous malignancies<sup>12</sup> and occurs predominantly in elderly fair-skinned men.<sup>13</sup> Chronic sun exposure is the major etiologic factor for the development of cutaneous SCC<sup>14</sup> and actinic keratosis and Bowen disease (SCC *in situ*) are considered to be precursor lesions.<sup>13,14</sup> Dermatoses giving rise to malignancy is rare, but if persistent over a long period, may progress to malignancy like in our case. Various dermatoses like allergic and non-allergic contact dermatitis<sup>2</sup> and dermatophytosis<sup>3</sup> are more common in body folds especially when associated with increased sweating. Saree induces various dermatoses along the waist in our female patients and 140 cases of the same have been reported.<sup>4</sup> Multiple studies on flexural dermatoses have not identified any association with risk factors like diabetes,<sup>15</sup> obesity and atopy.<sup>16</sup> Tightness of a cord of saree (Cotton nada) giving rise to chronic itching/friction/irritation leads to this type of waistline lesions. Hence use of broad belt instead of narrow, thick cord which will reduce the pressure over waist line which in turn will minimize the chances of malignancy.<sup>17</sup> Squamous cell carcinomas are characterized by papules, plaques, or erythematous and keratotic nodules.<sup>1</sup> Lesions that are more than 2 cm in diameter (large SCCs) carry twice the risk for recurrence and 3 times the risk for metastasis.<sup>12</sup> The 5-year cure rate for large SCCs (70%) is much lower than smaller lesions (98.4%). Lesions that are 4 cm or more in diameter are strongly associated with mortality arising because of recurrence of complications of SCC.<sup>12</sup> Large SCCs present in patients without a family history of skin cancer and develop from chronic lesions located in areas that are difficult for patients to see; for example, 66.7% of cases occur on the back. Giant lesions are associated with lower socioeconomic status and in population with infrequent physician visits.<sup>18</sup> Giant SCCs larger than 5 cm in diameter are rare; there is no guideline on the size of an SCC that is considered giant.<sup>7-19</sup> The nomenclature adopted in this report supergiant is derived from a report that defined super giant basal cell carcinomas as tumors greater than 20 cm in diameter.<sup>20</sup> There have been reports of SCCs with proportions similar to our patients<sup>7-21</sup> and the tumor size is an important prognostic factor.<sup>13</sup> The delay between onset of injury and treatment substantially increases the likelihood that the SCC will increase in size beyond 2 cm in diameter. Early detection and treatment of SCCs can have a positive impact on morbidity and mortality rates as well as costs.<sup>20</sup> Cutaneous SCCs are diagnosed via clinical evaluation<sup>14</sup> and confirmed by pathological examination.<sup>14</sup> Other than a diameter greater than 2 cm, factors that indicate a poor prognosis for SCCs include location in periorificial zones; occurrence in injury sites (i.e., burn scars, chronic ulcers, areas of radiodermatitis); adherence to ceiling level; mucoepidermoid, acantholytic, and desmoplastic histologic subtypes; perineural invasion; poorly differentiated or undifferentiated tumors; and Clark level IV or V.<sup>13,14</sup> The presence of at least one of these criteria implies an increased risk for recurrence and/or metastasis.<sup>13</sup> Immunosuppression, inadequately excised lesions, recurrent lesions, and lymph node involvement or metastasis also are determinants of poor prognosis.<sup>13,14</sup>

Surgical excision with safety margins is the preferred treatment in most cases of SCC<sup>13</sup> including larger lesions.<sup>7-9</sup> For SCCs greater than 2 cm, the lateral surgical margins of resection must be greater than 6 mm. The deep margin should involve the hypodermis, respecting fascia, periosteum, and perichondrium because these structures are not in direct contact with or invaded by the tumor.<sup>13</sup> In tumors that affect large areas, larger margins are recommended.<sup>8,22</sup> Appropriate reconstruction methods should be based on the location and size of the defect created after tumor excision.<sup>22</sup> In our patients, primary closure was enough. The proper surgical treatment of larger SCCs can provide long-term survival or even cure the disease.<sup>7,8</sup> It is recommended that cases of SCC with the worst prognostic factors are followed up for 5 years.<sup>13</sup> Special attention should be given to preventive measures and early detection of skin cancers<sup>14,23</sup> thus avoiding cases with large dimensions such as the case reported here.

## CONCLUSION

SCC occurring at flank region due to saree is one of its kind presentation and SCC greater than 5 cms are rare and if found, wide excision with reconstruction can provide long term survival. Waist dermatoses due to saree can rarely present as malignancy and this entity should be kept in mind and SCC should be ruled out in ladies wearing saree.

## REFERENCES

1. Lee DA, Miller SJ. Nonmelanoma skin cancer. *Facial Plast Surg Clin North Am.* 2009;17:309-24.
2. James C, Shaw M. Allergic and non allergic eczematous dermatitis. *Immunology and Allergy Clinics of North America.* 1996;16:119-35.
3. Rinaldi MG. Dermatophytosis: epidemiological and microbiological update. *J Am Acad Dermatol.* 2000;43:S120-4.
4. Eapen BR, Shabana S, Anandan S. Waist dermatoses in Indian women wearing saree. *Indian J Dermatol Venereol Leprol.* 2003;69:88-9.
5. Renzi C, Mastroeni S, Passarelli F, et al. Factors associated with large cutaneous squamous cell carcinomas. *J Am Acad Dermatol.* 2010;63:404-11.
6. Bachmeyer C, Reynaert G, Pen L, et al. Giant cutaneous squamous cell carcinoma of the nose with subsequent brain extension [in French]. *Ann Dermatol Venereol.* 2004;131:791-4.
7. Yuen JC, Habibipour S, Johnson D, et al. Giant skin cancer of the chest wall. *Plast Reconstr Surg.* 1997;100:1614-5.
8. Thomas WO, Harper LL, Wong SG, et al. Surgical management of giant nonmelanoma skin neoplasia. *South Med J.* 1998;91:190-5.
9. Unlü RE, Orbay H, Uysal AC, et al. Unusual and giant tumors of head and neck region. *J Craniofac Surg.* 2006;17:1219-29.
10. Kamble AS, Gokhale S. Saree Cancer – A Case Report. *Int J Biol Med Res.* 2012;3(2):1540-1

11. Patil AS, Bakhshi GD, Puri YS, Gedham MC, Naik AV, Joshi RK. Saree Cancer. *Bombay Hospital J.* 2005; 47: 302-3.
12. Weinberg AS, Ogle CA, Shim EK. Metastatic cutaneous squamous cell carcinoma: an update. *Dermatol Surg.* 2007;33:885-99.
13. French Society of Dermatology. Guidelines for the diagnosis and treatment of cutaneous squamous cell carcinoma and precursor lesions. arguments—May 2009 [in French]. *Ann Dermatol Venereol.* 2009;136(5):S189-S242.
14. Madan V, Lear JT, Szeimies RM. Non-melanoma skin cancer. *Lancet.* 2010;375:673-685.
15. Sibbold RG. Skin and diabetes. *Endocrinol Metab Clin North Am.* 1996;25:463-72.
16. Hanifin JM, Rajka RG. Diagnostic features of atopic dermatitis. *Acta Derm Venereol (Stockh).* 1980;92(144):44-7.
17. Bakshi, Borisa, Tayde. Waist cancer. *J Indian Med Assoc.* 2011;109:829-31.
18. Robinson JK, Altman JS, Rademaker AW. Socioeconomic status and attitudes of 51 patients with giant basal and squamous cell carcinoma and paired controls. *Arch Dermatol.* 1995;131:428-31.
19. Nishioka M, Tanemura A, Yamanaka T, et al. A case of giant squamous cell carcinoma of the buttock possibly arose from syringocystadenoma and invaded to the rectum. *J Skin Cancer.* 2011;2011:213406.
20. De Bree E, Laliotis A, Manios A, et al. Super giant basal cell carcinoma of the abdominal wall: still possible in the 21st century. *Int J Dermatol.* 2010;49:806-9.
21. Rai JK, Singh P, Mendonca DA, et al. Management of a neglected giant squamous cell carcinoma of the scalp. *QJM.* 2009;102:67.
22. Papadopoulos O, Frantzoglou M, Chrisostomidis C, et al. Neglected squamous cell carcinoma of the frontal area: a clinical report. *J Craniofac Surg.* 2006;17:1015-20.
23. Ferreira CP, Valle Hde A, Ferreira JA, et al. Giant squamous cell carcinoma in HIV-positive patient. *Braz J Infect Dis.* 2010;14:209-10.

**Cite this article as:** Mandhane N, Shaikh TP, Ansari S, Deolekar S, Karandikar S, Sreedharan L, Ali S. Squamous cell carcinoma in left flank due to saree: Largest reported case. *Int J Res Med Sci* 2015;3:1803-6.