

## Case Report

# Median nerve's loop in the arm penetrated by a superficial brachial artery: case report and neurosurgical considerations

George K. Paraskevas\*, Ioannis Varnalidis, Konstantinos Koutsouflianiotis

Faculty of Medicine, Aristotle University of Thessaloniki, Greece

**Received:** 18 June 2015

**Accepted:** 09 July 2015

### \*Correspondence:

Dr. G. K. Paraskevas,

E-mail: [g\\_paraskevas@yahoo.gr](mailto:g_paraskevas@yahoo.gr)

**Copyright:** © the author(s), publisher and licensee Medip Academy. This is an open-access article distributed under the terms of the Creative Commons Attribution Non-Commercial License, which permits unrestricted non-commercial use, distribution, and reproduction in any medium, provided the original work is properly cited.

## ABSTRACT

Median nerve is commonly formed by the union of the lateral and medial cord of the brachial plexus, which embrace the third part of the axillary artery. Formation of a median nerve's loop is a very rare condition. We present a cadaveric case, in which the right median nerve was found at the upper arm forming a fusiform neural loop penetrated by a superficial brachial artery, which continued over the forearm as the radial artery. The literature concerning nerve loops and traversing arteries is discussed, as well as the relevant embryology. We consider that such nerve loops constitute vulnerable sites of the nerve trunk since it is compressed by the pulsation of the abnormal traversing artery. Moreover, neurosurgeons should keep in mind that in case of existing arterial variation, variation of the associated neural structures may co-exist.

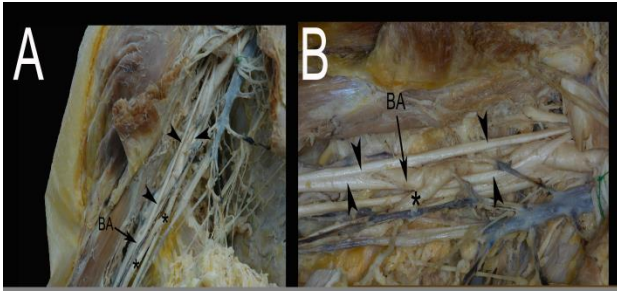
**Keywords:** Median nerve, Superficial brachial artery, Loop

## INTRODUCTION

As it is well known the median nerve (MN) is commonly formed by the union of the lateral and medial cord of the brachial plexus, which embrace the third part of the axillary artery, uniting anterior or lateral to it.<sup>1</sup> Rarely, the MN or its roots may course behind the axillary or brachial artery.<sup>2</sup> Furthermore, the MN is observed to be formed by three roots, usually two from the lateral cord and one from the medial cord or even by four roots, two from medial and two from lateral cord<sup>3</sup> or three arising from the lateral and one from the medial cord.<sup>4</sup> Sometimes, in such cases as the abovementioned the MN's roots form a nerve loop around the axillary vessels.<sup>5</sup> However the formation of a nerve loop in the region of the arm associated with an abnormal superficial brachial artery is a very rarely detected combination of vessels and nerves variants that should be highlighted and taken into account by the neurosurgeon during surgical interventions in the arm and axilla area.

## CASE REPORT

During our routine dissection studies for educational and research purposes, we detected on the right side of the upper arm of a 78-year-old male cadaver an unusual MN's loop associated with a superficial brachial artery. Specifically, the MN was united with an additional lateral root from the lateral cord of the brachial plexus, giving rise to a fusiform neural loop penetrated by a superficial brachial artery. The latter one was coursing superficial to the MN, as the so-called superficial radial artery as it continued as radial artery. The main brachial artery was located underneath the MN (Fig.1). The cause of death was unrelated to the current study. There were no any demonstrable pathologic conditions or concomitant anatomic variations or evidence of previous surgical interventions in the axilla and arm region. The topography of the current variant was documented by repeated photographs during the course of the anatomical dissection.



**Figure 1: (A) The loop of median nerve (arrowheads) is demonstrated, with the main brachial artery (BA) inside it and the superficial brachial artery (\*) traversing the loop. (B) Magnification of median nerve's loop.**

## DISCUSSION

Formation of MN's loops is a very rare condition. Presence of MN's loop in the forearm enclosing the abnormal persistent median artery has been detected very occasionally in the literature,<sup>6,7</sup> whereas an unusual MN's ring at the upper forearm enclosing the aberrant palmaris profundus muscle has also been reported.<sup>8</sup> In few studies the existence of MN's palmar digital nerve loops penetrated by digital arteries has also been prescribed. Although, no so widely-known in the community of neurosurgeons, the aforementioned relationship between palmar digital nerve loops and digital arteries has been mentioned in a high prevalence as 67%<sup>9</sup> or 81%.<sup>10</sup>

MN's perforation in the axilla by an axillary artery's branch such as subscapular artery and humeral circumflex stem in the region of axilla has been mentioned in an incidence of 1.46%.<sup>11</sup> The same author observed penetration of the MN by deep brachial artery at the middle of the arm in only 0.1%. Moreover, penetration of the MN in the lower arm by a muscular branch of the brachial artery has been described as well.<sup>12</sup> Our case is unique since MN's loop at the upper third of arm is traversed by an abnormal artery the so-called superficial brachial artery. Such an artery coursing superficial to MN with the main brachial artery deep to MN was encountered in approximately 4% in the literature.<sup>13</sup> The variations of the arteries of the upper limb seem to be one of the leading causes of variations of the brachial plexus.<sup>14</sup> With the establishment of the musculature the nerve pattern becomes fixed and does not adjust itself to the more variable arteries when they tend to revert to their earlier primate positions. This has been considered by Miller as an explanation for the human anomaly of perforation of a nerve by an artery.<sup>11</sup>

As concerns the clinical value of the presence of a MN's loop traversing by a normal or abnormal artery limited data are provided in the relative literature. It has been postulated that an abnormal artery penetrating the MN in the arm can compress it and produce symptoms of proximal neuropathy of MN.<sup>15</sup> Roy claimed that the increased amount of connective tissue and reorganization

of the MN into multiple smaller fascicles at the site of MN's arterial penetration presumably leads to MN's protection from compression induced from arterial pulsation.<sup>12</sup> In cases of digital nerves' loops traversed by digital arteries, it is likely the pulsatile arterial flow progressed over time to induce compression neuropathy or reversely the neural loops to cause occlusion of the digital arteries. In such cases the microvascular decompression of the neural loop, transposition of the artery out of the loop and arterial repair has been suggested.<sup>16</sup> It has been proposed that such nerves are usually weak at the site of arterial penetration and are more susceptible to pathological conditions.<sup>17</sup> Regarding the likely clinical significance of the MN's loop traversing by an artery in the region of axilla, arm or forearm no much data are offered in the consulted literature. We assume that under circumstances, such as progressive arterial flow, aneurysm or thrombosis of the contented artery, MN's compression symptoms might be arisen. In addition when an abnormality of an artery is detected, the neurosurgeon should be suspicious for the co-existence of a variant of the associated neural structures.

## CONCLUSION

MN's loop is a very rare anatomical variation. In the current study a cadaveric case has been presented, in which a fusiform neural loop penetrated by a superficial brachial artery was encountered. Neurosurgeons should acknowledge the potential existence of this variant, while keeping in mind that in case of existing arterial abnormality, variation of the associated neural structures may co-exist.

*Funding: None*

*Conflict of interest: None declared*

*Ethical approval: Not required*

## REFERENCES

- Williams PL (Ed). *Gray's Anatomy*. Edinburgh: Churchill Livingstone;1995.
- Natsis K, Papadopoulos AL, Paraskevas G, Totlis T, Tsikaras P. High origin of a superficial ulnar artery arising from the axillary artery : anatomy , embryology , clinical significance and review of the literature. *Folia Morphol.* 2006;65(4):189-94.
- Satyanaraya N, Vishvakarma N, Kumar GP, Guha R, Datta AK, Sunitha P. Rare variations in the formation of median nerve-embryological basis. *Nepal Med Col J.* 2009;11(4):287-90.
- Uzun A, Selling LL. A variation in the formation of median nerve and communicating branches between musculocutaneous and median nerve. *Folia Morphol.* 2001;60(2):99-101.
- Bhat KMR, Gowda S, Potu BK. Nerve loop around the axillary vessels by the roots of the median nerve, a rare variation in a south Indian male cadaver: a case report. *Cases Journal.* 2009;2:179.

6. Srivastava SK, Pande BS. Anomalous pattern of median artery in the forearm of Indians. *Acta Anat.* 1990;138:193-4.
7. Kolagi SI, Rairam GB, Herur A. Multiple variations of median nerve with persistent median artery- a case report and review of literature. *Anatomica Karnataka.* 2010;4(1):44-6.
8. Chou HC, Jeng H, Ko TL, Pai MH, Chang CY, Wu CH. Variant palmaris profundus enclosed by an unusual loop of the median nerve. *J Anat.* 2001;199:499-500.
9. Hartmann H. Note sur l'anatomie des nerfs de la paume de la main. *Bull Mem Soc Anat Paris.* 1887;62:860-64.
10. Lee JY, Kim YR, Kim JN, Choi HG, Song WC, Koh KC. Penetration of the digital nerves by the common palmar digital arteries in human cadavers. *J Hand Surg.* 2010;35(A):2022-26.
11. Miller RA. Observations upon the arrangement of the axillary artery and brachial plexus. *Am J Anat.* 1939;64:143-63.
12. Roy TS. Median nerve penetration by a muscular branch of the brachial artery. *Clin Anat.* 2003;16:335-9.
13. Lippert H, Pabst R. Arterial variations in man. Classification and frequency. Munchen: JF Bergmann Verlag; 1985.
14. Beheiry EE. Anatomical variations of the median nerve distribution and communication in the arm. *Folia Morphol.* 2004;63:313-18.
15. Gross PT, Tolomeo EA. Proximal median neuropathies. *Neurol Clin.* 1999;17:425-45.
16. Hofmann KJ, Ruchelsman DE. Symptomatic neural loop causing hemigital anaesthesia: case report. *J Hand Surg.* 2012;37A:1994-96.
17. Delfiner JS. Dynamics and pathophysiology of nerve compression in the upper extremity. *Orthop Clin North Am.* 1996;27:219-26.

**Cite this article as:** Paraskevas GK, Varnalidis I, Koutsouflianiotis K. Median nerve's loop in the arm penetrated by a superficial brachial artery: case report and neurosurgical considerations. *Int J Res Med Sci* 2015;3:2123-5.