

## Research Article

# Anomalous azygos veins - its embryological basis and clinical significance

Uma Shivanal<sup>1\*</sup>, Geethanjali HT<sup>2</sup>

<sup>1</sup>Department of Anatomy, Mysore Medical College and Research Institute, Mysore, Karnataka, India

<sup>2</sup>Department of Anatomy, Mandya Institute of Medical Sciences, Mandya, Karnataka, India

**Received:** 15 July 2015

**Accepted:** 10 August 2015

### \*Correspondence:

Dr. Uma Shivanal,

E-mail: [umavijay15@gmail.com](mailto:umavijay15@gmail.com)

**Copyright:** © the author(s), publisher and licensee Medip Academy. This is an open-access article distributed under the terms of the Creative Commons Attribution Non-Commercial License, which permits unrestricted non-commercial use, distribution, and reproduction in any medium, provided the original work is properly cited.

### ABSTRACT

**Background:** The anatomical knowledge of the variability of the azygos venous system is important for the surgical interventions of the posterior mediastinum and also during radiological investigations/diagnosis especially CT and MRI. The variant azygos venous system might be confused with thoracic aorta aneurysms, lymphadenopathy and tumours of posterior mediastinum.

**Methods:** The present study was undertaken on 10 embalmed adult human cadavers irrespective of sex, used for undergraduate dissection from the Department of Anatomy, Mandya Institute of Medical Sciences, Mandya. In this present study, formation, course and termination pattern of azygos system of veins was observed in 10 dissected human cadavers. Out of which 2 cadavers showed different types of variations.

**Results:** In the present study, normal azygos venous system was found in 8 specimens accounting for 80%. Variations were found in 2 specimens (20%); one specimen presented with connection between accessory hemiazygos vein and hemiazygos vein, 3 transverse channels across vertebral column and the other specimen showed absence of accessory hemiazygos vein and shifting of azygos vein towards midline.

**Conclusions:** Accurate knowledge about these kinds of variations is very important to identify, especially in the computed tomography and magnetic resonance imaging of mediastinum. The abnormal azygos venous system may easily be confused with aneurysm, lymphadenopathy and other abnormalities like tumor. It is important to keep these kinds of variations in mind while performing the mediastinal operations or surgery of large vessels.

**Keywords:** Azygos vein, Hemiazygos vein, Accessory azygos vein

### INTRODUCTION

The Greek root *zyg* refers to a pair. 'A-' means not. Thus, azygos means unpaired. The azygos vein is unpaired in that there is only one in the body, mostly on the right side. While there is the hemiazygos vein and its accessory on the left side of the body, they are considered tributaries of the azygos vein rather than its left-side equivalent.<sup>1</sup> The azygos system includes those veins which are straight in course, paravertebral in position, and not accompanied with the corresponding arteries.

These veins are provided with valves, and drain most of the blood from the back and from the thoracic and abdominal walls. The azygos system communicates with the vena caval system in front, and with the vertebral venous plexus behind. The terminal veins of this system are the azygos, hemi-azygos and accessory azygos veins. The azygos vein is inconstant in the mode of origin.<sup>2</sup> Although there are complete valves in some tributaries of azygos veins, there are usually incomplete valves varying between one and four in the azygos arch. Thus, the azygos vein functions as a collateral for the superior and

IVC in case of their obstruction. The azygos vein connects the superior and IVC with ascending lumbar veins and their tributaries. In congenital obstruction of the IVC, the azygos vein provides the venous flow of the lower body half.<sup>3</sup> On developmental grounds, it may arise from the back of inferior vena cava at or below the renal vein as lumbar azygos vein. If it does not arise as the lumbar azygos vein, then the trunk formed by the union of the right subcostal and right ascending lumbar veins forms the commencement of the azygos veins.<sup>4</sup> The azygos vein system develops on the basis of multiple transformation of the subcardinal veins, which causes its great variability, especially on the left side.<sup>5</sup> The azygos vein system makes the somatic vein network of the trunk. It is important that in pathologic situations it may function as collateral pathway.<sup>3</sup> Azygos veins are important cavo-caval and porto-caval junctions, thus forming collateral circulation in caval vein occlusion and in portal hypertension.<sup>5</sup>


## METHODS

The present study was conducted on 10 embalmed adult human cadavers, belonging to the Department of Anatomy of Mandya Institute of Medical Sciences, Mandya for the period of 1 year from January 2013 - January 2014, used for undergraduate studies irrespective of sex and race, age ranging from 18 to 80 years. The dissection was carried out to look for the formation, course and termination pattern of azygos system of veins.

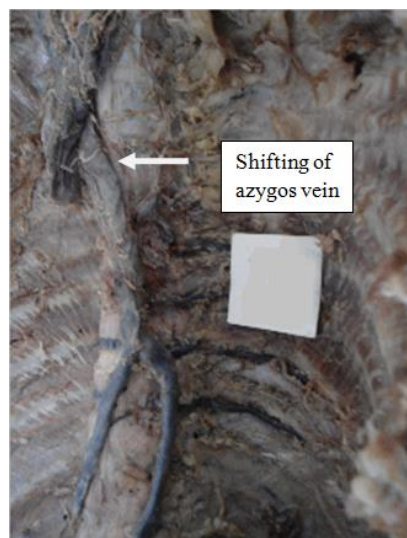
## RESULTS

Out of 10 specimens studied, 8 (80%) specimens showed normal azygos venous system, while the rest 2 (20%) specimens showed:

1. Connection between accessory hemiazygos vein and hemiazygos vein, 3 transverse channels across vertebral column (Figure 1).
2. Absence of accessory hemiazygos vein and shifting of azygos vein towards midline (Figure 2).



**Figure 1: Specimen showing connection between accessory hemiazygos vein and hemiazygos vein, 3 transverse channels across vertebral column.**



**Figure 2: Specimen showing absence of accessory hemiazygos vein and shifting of azygos vein towards midline.**

## DISCUSSION

Variation of azygos venous system are not very rare. Knowledge of variations of the azygos venous system is necessary since this might be confused with aneurysm, lymphadenopathy and other anomalies like tumor, during radiological investigations.<sup>4</sup> The azygos vein system functions as an additional drainage way when high pressure and obstruction occurs in most of the veins that inferior vena cava vein drains. In the obstruction of the IVC, it joins whole venous drainage below the diaphragm except the digestive system. This system connects to the cerebral vein system with the intercostal veins and vertebral venous plexuses. This connection is important because of venous metastatic pathways in breast and bronchial cancers. Also, in superior vena cava syndrome it joins with IVC.<sup>3</sup>

Very occasionally, independent left and right azygos veins (the early embryonic form) persist, or a single azygos vein may occur in a midline position without hemiazygos tributaries.

Azygos venous system is classified as Anson's system of classification with a basis of vertical and horizontal connection of the system. These include primitive or embryological type, transient type, unicolon type as 3 basic types with their eleven subgroups. According to this:

- Type I: This primitive and embryological form consists of two separate veins lying in parallel to each other in the posterior mediastinum, being anterior and lateral to the vertebral column. It is seen 1%. These parallel veins constitute the azygos vein at the right side and superior and inferior azygos veins, which are the continuation of each other's, at the left side. The veins at the left side,

those that the left lumbar vein opens, subsequently open into the left brachiocephalic vein. There is only one subtype (Group 1) of this type.

- Type II: 98% of all cases are in this form and it is known as the transition type. It consists of Groups 2-10. There are multiple retro-aortic anastomoses between the azygos and hemiazygos venous systems. From Group 2 to Group 5 the quantity of these transverse anastomoses increases. There is continuity in the left side. Between Groups 6 and 10, it is seen a vertical bending and the number of the transverse anastomoses decreases gradually.

- Type III: It consists of a single azygos vein lying at the midline, on the anterior surface of the vertebral column. There is only one subtype (Group 11) of this main type. It is seen in 1% of all cases.<sup>3</sup>

According to these classifications, one of our cases (Figure 1) shows connection between accessory hemiazygos vein and hemiazygos vein, later forming horizontal anastomosis with azygos vein. This case is of Type II Anson classification. And the other case (Figure 2), which shows absence of accessory hemiazygos vein and shifting of azygos vein towards midline partly comes under Type III.

Retro-aortic transvertebral connections from hemiazygos and accessory hemiazygos veins to the azygos are also extremely variable: there may be up to five connections. When either of the hemiazygos veins are absent, the relevant intercostal veins cross the vertebral bodies and end in the azygos. These transvertebral routes are often very short, because the azygos vein is more commonly anterior to the vertebral column and often passes to the left of the midline for part of its course. When there is congenital interruption of the IVC, the azygos vein can become as large as the IVC that it has replaced.<sup>3</sup>

Bergmann et al., have reported variations of azygos veins in 26% of cases. Grzybiak et al., have found the variations of azygos veins in 25% of cases. The azygos vein receives the hemiazygos vein, on its left margin, as a side or double branch at about the eighth and ninth vertebra. Slightly higher, at the sixth or seventh thoracic vertebra, it receives the accessory hemiazygos vein as a single trunk in 72% of individuals. The hemiazygos and accessory hemiazygos veins are incompletely formed in 15% of individuals. When this occurs the posterior intercostal veins on the left side of the thorax may drain into the azygos vein independently. In this case the azygos vein lies on the midline.<sup>6</sup>

Satheesha Nayak et al., have reported a case of azygos ladder i.e. the hemiazygos and accessory hemiazygos veins communicated with the azygos vein through six transverse channels across the vertebral column. The accessory hemiazygos and hemiazygos veins joined to form a common channel which opened into the azygos

vein. Presence of preaortic interazygos vein has been reported in the literature. Presence of such interazygos vein might get damaged during manipulations in the posterior mediastinum as it is a common site of surgical interventions.

Knowledge of variations in the posterior mediastinum close to the vertebral column is important for cardiothoracic surgeons, radiologists and orthopedic surgeons.<sup>4</sup>

Hitherto there have been only 6 cases of absence of the AV published in anatomical-radiological literature, the intercostal area being drained by the HV, which terminated on the left brachiocephalic vein. In all these cases the increased venous flow on the left side caused the enlargement of the left intercostal superior vein, which appears on radiological films as a small triangular "aortic nipple".<sup>7</sup>

A case of absence of azygos vein associated with the double superior vena cava has also been reported.<sup>4</sup> The azygos vein may continue as inferior vena cava and open directly in to the right atrium. Absence of superior and inferior venae cavae and azygos continuation of inferior vena has been reported.<sup>8</sup> Absence of accessory hemiazygos vein and termination of left 4-7<sup>th</sup> posterior intercostal veins into azygos vein has been reported by Quadros et al.<sup>9</sup> A case of communication between pulmonary veins and azygos vein has been reported by Lapierre et al.<sup>10</sup> Very rarely the azygos vein may terminate in the left superior vena cava. One such variation has been reported by Uemura et al.<sup>11</sup>

The connection between azygos vein and portal venous system provides the blood flow to the superior vena cava through the esophageal veins in case of portal hypertension. In case of portal hypertension, collateral veins are produced between portal and caval venous systems mainly in five zones. One of these collateral veins in the retroperitoneal region is the "plexus venosus retzius", which connects the veins of duodenum, pancreas, spleen and transverse colon with the azygos and inferior phrenic veins.<sup>3</sup>

Osteophytosis, a generalized phenomenon along the vertebral column with advancing years, is considered to be caused by the mechanical stresses and strains acting on the vertebral column. The asymmetric growth of the osteophytes in the thoracic region is apparently due to an inhibitory influence on their development which is exerted by the aorta running along the left side of the vertebral column. In the lower thoracic and lumbar regions where the aorta runs in the midline, osteophytes are seen to develop symmetrically on both sides (Nathan, 1960). Thus the asymmetrical development of the vertebral bodies seems to cause the deviation of the azygos vein by pushing it to the left. The development of osteophytes in the thoracic region, predominantly on the

right side of the vertebrae, may also be related to the deviation of the azygos vein to the left.<sup>12</sup>

Azygos veins embryologically generate from subcardinal veins. The right subcardinal vein forms azygos vein and the left subcardinal vein forms hemiazygos vein. A transverse anastomosis is formed between them at sixth and seventh thoracic vertebrae in adults. At the left side, cranial part of this anastomosis remains as accessory hemiazygos vein.<sup>13</sup>

Knowledge of variations is of utmost important to identify, especially in the computed tomography and magnetic resonance imaging of mediastinum. The abnormal azygos venous system can be confused with thoracic aorta aneurysm, lymphadenopathy and other abnormalities like tumours of posterior mediastinum.

## CONCLUSION

The azygos vein is the vein that drains the thoracic wall and upper lumbar region. It is the important channel connecting the two venae cavae. Knowledge of different types of variations is of utmost importance during any surgical interventions and radiological investigations so as to avoid iatrogenic complications.

*Funding: No funding sources*

*Conflict of interest: None declared*

*Ethical approval: The study was approved by the institutional ethics committee*

## REFERENCES

1. Susan Standring. Azygos vein. In: Susan Standring, eds. Gray's Anatomy: the Anatomical Basis of Clinical Practice. 40th ed. London: Churchill Livingstone Elsevier; 2008: 939-940.
2. Datta AK. Thorax and abdomen. In: Datta AK, eds. Essentials of Human Anatomy. 9th ed. Kolkata: Current Books International; 2010: 100-102.
3. Kutoglu T, Turut M, Kocabiyik N, Ozan H, Yildirim M. Anatomical analysis of azygos vein system in human cadavers. Rom J Morphol Embryol. 2012;53(4):1051-6.
4. Naveen K, Satheesha NB, Surekha S, Somayaji SN. Azygos ladder and looped thoracic duct - a case report. IJAV. 2011;4:80-2.
5. Elzbieta KS, Marcin W, Michal S, Helena K. Variability of the azygos vein system in human foetuses. Folia Morphol. 2003;62(4):427-30.
6. Bergman RA, Afifi AK, Miyauchi R. Azygos vein. Illustrated Encyclopedia of Human Anatomic Variation: Opus II: Cardiovascular system: Veins: Head, Neck and Thorax. Anatomy Atlases, 2015. Available at: <http://www.anatomyatlases.org/AnatomicVariants/Cardiovascular/Text/Veins/Azygos.shtml>.
7. Arslan G, Cebuk M, Ozkaynak C, Sindel T, Lüleci E. Absence of the azygos vein. J Clin Imaging. 2000;24:157-8.
8. Quraishi MB, Mufti O, Wase A. Absent left and right superior vena cava and azygos continuation of inferior vena cava: a rare anomaly of systemic venous return. J Invasive Cardiol. 2010;22:E159-61.
9. Quadros LS, Potu BK, Guru A, Pulakunta T, Ray B, D'Silva SS, et al. Anomalous azygos venous system in a south Indian cadaver: a case report. Cases J. 2009;2:6746.
10. Lapierre C, Siles A, Bigras JL. Partial anomalous pulmonary venous return to the azygos vein: an unusual case. Pediatr Cardiol. 2010;31:749-50.
11. Uemura M, Takemura A, Ehara D, Yasumitsu H, Ohnishi Y, Suwa F. Left superior vena cava with left azygos vein. Okajimas Folia Anat Jpn. 2009;86:55-60.
12. Nathan H. Anatomical observations on the course of the azygos vein (vena azygos major). Thorax. 1960;15:229-32.
13. Lydia SQ, Bhagath KP, Anitha G, Thejodhar P, Biswabina R, Suhani SD, et al. Anomalous azygos venous system in a south Indian cadaver: a case report. Cases J. 2009;2:6746.

**Cite this article as:** Shivanal U, Geethanjali HT. Anomalous azygos veins - its embryological basis and clinical significance. Int J Res Med Sci 2015;3:2323-6.