

## Case Report

# Multiple palmar epidermoid cysts: fourth reported case

Raj Gautam, Tanveer Parvez Shaikh\*, Shitiz Gupta, Jatin Wani,  
Sridevi Murali, Ankit Bhupatkar, Sandesh Deolekar

Department of Surgery, DY Patil School of Medicine, Nerul, Navi Mumbai, Maharashtra, India

**Received:** 04 July 2015

**Accepted:** 09 August 2015

### \*Correspondence:

Dr. Tanveer Parvez Shaikh,

E-mail: [drtanny.shaikh@gmail.com](mailto:drtanny.shaikh@gmail.com)

**Copyright:** © the author(s), publisher and licensee Medip Academy. This is an open-access article distributed under the terms of the Creative Commons Attribution Non-Commercial License, which permits unrestricted non-commercial use, distribution, and reproduction in any medium, provided the original work is properly cited.

### ABSTRACT

Implantation of epidermal fragments into the dermis has been pointed out as the cause of common epidermal cysts. However, some palmoplantar epidermoid cysts have been reported to be caused by human papillomavirus (HPV) infection or to be derived from eccrine ducts. A 55 year old woman presented with multiple epidermoid cysts on the palm and volar aspect of her left hand. HPV infection CEA was not detected in situ hybridization and polymerase chain reaction.

**Keywords:** Epidermoid cyst, Eccrine duct, CEA, Human papillomavirus

## INTRODUCTION

Multiple epidermoid cysts appear infrequently on the palms and soles where pilosebaceous structures are absent. Till date 3 cases of multiple palmoplantar epidermoid cysts have been reported to the best of our knowledge<sup>1-3</sup> (Table 1). Obstruction of hair follicles and implantation of epidermal fragments into the dermis from a penetrating or blunt injury have been pointed out as causes of common epidermal cysts.<sup>4</sup> However, it is improbable that palmoplantar epidermoid cysts develop from pilosebaceous structures. On the other hand, recent investigations indicate that palmoplantar epidermoid cysts are caused by human papillomavirus (HPV) infection<sup>5-10</sup> and that they develop from eccrine ducts.<sup>1,9,11</sup> Here we report fourth case of multiple palmar epidermoid cysts.

## CASE REPORT

A 55 year old woman came to outpatient department after first noticing asymptomatic multiple nodules on the left palm of her left hand since 10 years. These nodules gradually enlarged and increased in size over 10 years.

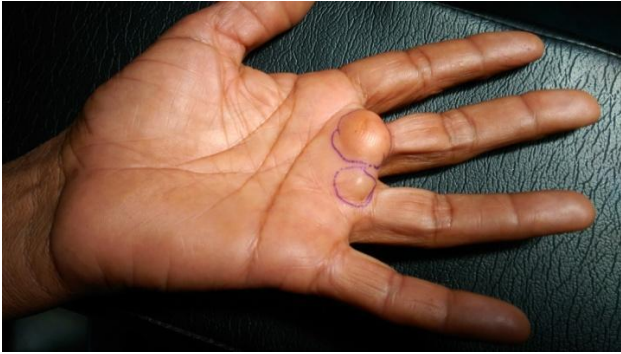
She had noticed no striking traumatic injuries at the sites where the epidermoid cysts developed. The cysts were varied in size, smooth-surfaced, dome-shaped well defined margins (Figure 1).

**Table 1: Summary case reported.**

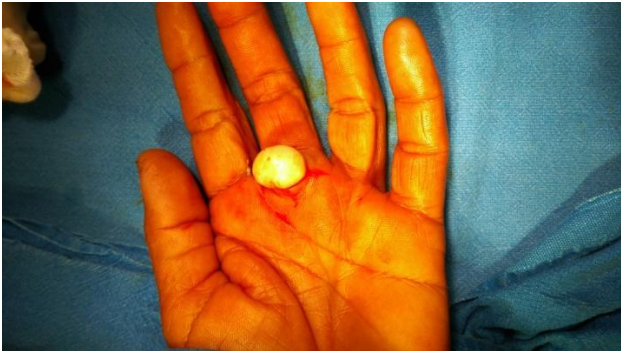Year (reference)	Age (sex)	Location	Duration	Therapy
1994 (1)	23 year (male)	Right sole	??	Surgery
1998 (2)	25 year (male)	??	??	Surgery
2002 (3)	65 years (female)	Left hand	2 years	Surgery
2015 (Present)	55 years (female)	Left hand	10 years	Surgery

Fine Needle Aspiration Cytology (FNAC) revealed white creamy material suggestive of epidermoid cyst. Ultrasonography showed two well defined lesions largest 2x2 cm. No similar nodules and verrucous lesions were observed on any other part of her body surface. These two lesions were excised (Figure 2) and sent for

histopathology. Histopathology of excised nodules which was formalin fixed and paraffin embedded. The cyst wall was composed of thin keratinized stratified squamous epithelial with focal acanthosis. The granular cell layer was thickened in most areas but was focally absent. The cyst cavity was filled with keratinous materials. HPV Infection was detected.



**Figure 1: Multiple epidermoid cysts.**



**Figure 2: One of the epidermoid cyst being excised.**

## DISCUSSION

Recent studies have pointed out that palmoplantar epidermoid cysts might be caused by HPV infection.<sup>5-10</sup> Egawa et al.<sup>1,9</sup> speculated that HPV-60 had a high affinity to eccrine duct epithelia and played a role in the cyst formation, since HPV-60 was concomitantly demonstrated with eccrine duct origin in plantar epidermoid cysts. In the present case, cyst wall did not reveal any histological changes suggestive of HPV infection such as vacuolated structures and intracytoplasmic eosinophilic inclusions.<sup>5-9</sup> In addition, HPV infection was not detected in the cyst wall cells in situ hybridization and PCR examinations. HPV DNA fragments were amplified by Polymerase Chain Reaction (PCR) examinations performed by the method described by Saiki et al.<sup>12</sup> using a thermal cycler (Perkin Elmer PJ 2000) and degenerate primers developed by Shamanin et al.<sup>13</sup> Therefore, HPV did not contribute to the development of epidermoid cysts in our case. Recently, it has been reported that palmoplantar epidermoid cysts could develop from the eccrine duct by factors other than HPV infection.<sup>11</sup> It is reported that an epidermal

keratinizing metaplasia occurs in eccrine duct milia.<sup>14,15</sup> On the other hand, Ohnishi and Watanabe<sup>16</sup> have pointed out that plantar epidermoid cysts were derived from the follicular infundibulum, since the cyst wall cells expressed cytokeratins specific to the epidermis or infundibulum. Thus, the origin of palmoplantar epidermoid cysts is still controversial.

CEA, one of the markers of eccrine ducts,<sup>17</sup> was extensively expressed in the cyst wall cells of a plantar cyst.<sup>1,9</sup> In the present patient, CEA expression was not evident in cyst wall cells. The cytokeratin composition of the cyst wall cells showed differentiation dependence similar to the non-adnexal epidermis, as observed by Ohnishi and Watanabe.<sup>16</sup> A similar localized distribution of multiple trichilemmal cysts was reported in a case of multiple glomus tumors.<sup>18</sup> The development on the dominant hand suggests that invagination of epidermal cells caused by traumatic injuries induced these palmar epidermoid cysts. It is conceivable that palmoplantar epidermoid cysts might be caused by HPV infection or invagination of epidermal cells and originated from the dermal eccrine ducts or surface epidermis.

## CONCLUSION

Multiple epidermoid cysts can occur without HPV infection and without showing any malignancy indicated by CEA. Surgery remains the gold stay for this condition. Knowledge of this will help in future.

*Funding: No funding sources*

*Conflict of interest: None declared*

*Ethical approval: Not required*

## REFERENCES

1. Egawa K, Honda Y, Inaba Y, Kojo Y, Ono T, de Villiers E-M. Multiple plantar epidermoid cysts harboring carcinoembryonic antigen and human papillomavirus DNA sequences. *J Am Med Dermatol.* 1994;30:494-6.
2. Thewes M, Worret W-I, Aback D. An unusual case of multiple epidermal finger cysts. *Dermatology.* 1998;196:366-7.
3. Maki Yokogawa, Kiyofumi Egawa, Kumi Dabanaka, Emi Wada, Ken Miyoshi, Mitsunori Ikeda, et al. Multiple palmar epidermoid cysts. *Dermatology.* 2002;205(4):398-400.
4. MacKie RM. Epidermal skin tumors. In: Champion RH, Burton JL, Ebling FJG, eds. *Textbook of Dermatology.* 5th ed. Oxford: Blackwell Scientific Publications; 1992: 1459-1504.
5. Yanagihara M, Sumi A, Mori S. Papillomavirus antigen in the epidermoid cyst of sole. *J Cutan Pathol.* 1989;16:375-81.
6. Egawa K, Inaba Y, Ono T, Arao T. Cystic papilloma in humans? Demonstration of human papillomavirus in plantar epidermoid cysts. *Arch Dermatol.* 1990;126:1599-603.

7. Mihara M, Nishiura S, Aso M, Shima S, Nakakuki S. Papillomavirus-infected keratinous cyst on the sole. *Am J Dermatopathol.* 1991;13:293-9.
8. Matsukura T, Iwasaki T, Kawashima M. Molecular cloning of a novel human papillomavirus (type 60) from a plantar cyst with characteristic pathological changes. *Virology.* 1992;190:561-4.
9. Egawa K, Honda Y, Inaba Y, Ono T, de Villiers E-M. Detection of human papillomaviruses and eccrine ducts in palmoplantar epidermoid cysts. *Br J Dermatol.* 1995;132:533-42.
10. Egawa K, Kitasato H, Honda Y, Kawai S, Mizushima Y, Ono T. Human papillomavirus 57 identified in a plantar epidermoid cyst. *Br J Dermatol.* 1998;138:510-4.
11. Egawa K, Kitasato H, Ono T. A palmar epidermoid cyst, showing histological features suggestive of eccrine duct origin, developing after a bee-sting. *Br J Dermatol.* 2000;143:469-70.
12. Saiki RK, Gelfand DH, Stoffel S, Scharf SJ, Higuchi R, Horn GT, et al. Primer-directed enzymatic amplification of DNA with a thermostable DNA polymerase. *Science.* 1988;239:487-91.
13. Shamanin V, Delius H, de Villiers E-M. Development of a broad spectrum PCR assay for papilloma viruses and its application in screening lung cancer biopsies. *J Gen Virol.* 1994;75:1149-56.
14. Tsuji T, Sugai T, Suzuki S. The mode of growth of eccrine duct milia. *J Invest Dermatol.* 1975;65:388-93.
15. Honda Y, Egawa K, Baba Y, Ono T. Sweat duct milia - immunohistological analysis of structure and three-dimensional reconstruction. *Arch Dermatol Res.* 1996;288:133-9.
16. Ohnishi T, Watanabe S. Immunohistochemical observation of cytokeratins in keratinous cysts including plantar epidermoid cyst. *J Cutan Pathol.* 1999;26:424-9.
17. Penneys NS, Nadji M, McKinney EC. Carcinoembryonic antigen present in human eccrine sweat. *J Am Acad Dermatol.* 1981;4:401-3.
18. Flarez A, Peteiro C, Sanchez-Aguilar D, Fernandez-Redondo V, Pereiro Ferreirids M, Toribio J. Three cases of type 2 segmental manifestation of multiple glomus tumors: association with linear multiple trichilemmal cysts in a patient. *Dermatology.* 2000;200:75-7.

**Cite this article as:** Gautam R, Shaikh TP, Gupta S, Wani J, Murali S, Bhupatkar A, Deolekar S. Multiple palmar epidermoid cysts: fourth reported case. *Int J Res Med Sci* 2015;3:2478-80.