

Research Article

An etiological analysis of proptosis

Nithin Teja*, Manmitha Reddy, Alekhya Vanama

Department of Ophthalmology, Mamata Medical College, Khammam, Telangana, India

Received: 08 August 2015

Revised: 11 September 2015

Accepted: 12 September 2015

***Correspondence:**

Dr. Nithin Teja,

E-mail: nithinreddygurra@gmail.com

Copyright: © the author(s), publisher and licensee Medip Academy. This is an open-access article distributed under the terms of the Creative Commons Attribution Non-Commercial License, which permits unrestricted non-commercial use, distribution, and reproduction in any medium, provided the original work is properly cited.

ABSTRACT

Background: The main objective of the study was to analyse the various causes for proptosis.

Methods: A prospective analysis of 54 cases of proptosis. Detailed ocular and systemic history, examination and relevant investigations were done in necessary cases. Also other related specialties opinion obtained whenever indicated for diagnosis and treatment.

Results: Out of 54 cases, 26 were axial and 28 were eccentric, 38 were unilateral, 16 were bilateral. Etiology of proptosis due to inflammation 20 cases, infectious 14 cases, neoplastic 10 cases, vascular 4 cases, traumatic 4 cases, others 2 cases.

Conclusions: Thyroid eye disease is the single most common cause of proptosis in this study. Among neoplastic cases primary tumours were more common than secondary tumours in the orbit in this study. Orbital X-ray, B scan, CT scan and MRI were helpful in the diagnosis, treatment and follow up.

Keywords: Early diagnosis, Timely intervention, Save vision and life

INTRODUCTION

Proptosis is a forward movement of the globe in relation to the skull. It is the common presenting symptom of wide variety of diseases affecting the structure in and around the orbit. The exact clinical diagnosis of the cause for proptosis is not easy, owing to the inaccessibility of the contents of the orbit.

A lesion in the intraconal region produces axial proptosis, whereas lesion in the extraconal region produces eccentric proptosis. Eccentric proptosis may be due to lesion within the orbit itself or due to the lesion in the neighbouring structures like cranial cavity, paranasal structures etc.

Thyroid eye disease (TED) is an immunological disorder that affects the orbital muscles and fat.¹ It is a disabling ocular presentation of Graves' disease (GD), causing cosmetic changes and functional alterations. TED will present in almost 50% of GD cases, whereas

approximately 5% of patients will develop severe disease with dysthyroid compressive optic neuropathy (DON).² TED has an incidence of 42 per million per year.³ Thyroid eye disease is the most common cause of unilateral and bilateral proptosis (Figure-1).

Orbital cellulitis describes inflammation of preseptal (peri-orbital) or postseptal (orbital) fat.⁴ Patients typically present with proptosis, chemosis, and painful diplopia.⁴ Blindness occurs in approximately 1% of patients with orbital cellulitis.⁵

Preseptal and postseptal can be difficult to differentiate clinically⁶ and therefore, imaging is often required for confirmation of diagnosis and to evaluate for complications of postseptal cellulitis.

Capillary hemangiomas are common primary benign tumors of the orbit.⁷⁻⁹ Cavernous hemangiomas are the most common benign neoplasm of the orbit in adults.

METHODS

A prospective analysis of 54 cases of proptosis was done. All the patients were evaluated as follows. Detailed history with reference to the duration of the illness, mode of onset, laterality¹⁰, progression and associated symptoms like fever, pain, diplopia, loss of vision etc. Prior medical and surgical treatment and family history of proptosis were also noted.

Complete ocular examinations including visual acuity, examination of orbit, eyelids, anterior and posterior segments were done. Slit lamp biomicroscopy, ophthalmoscopy, hertels exophthalmometry¹¹, visual fields, color vision, forced duction test, refraction, intra ocular pressure and examination of proptosis were also done.

Examination of other relevant system and laboratory investigations like routine haemogram, culture and sensitivity, T3, T4, TSH levels, histopathological examination of biopsy specimens etc. To find out inflammatory, infectious and neoplastic causes of proptosis. Orbital X-ray, B-scan, CT scan¹² and MRI were done to aid the etiological diagnosis.

Patients were also referred to ENT, Neurology, Endocrinology, Oncology and Radiology departments for the expert opinion regarding the diagnosis and management whenever indicated.

RESULTS

Incidence of proptosis in males is 26 (48.14%), in females 28 (51.85%). Out of 54 cases, 38 cases were unilateral (70.30%) and 16 cases were bilateral (29.62%). Number of cases with axial proptosis were 26 (48.14%), eccentric proptosis were 28 (51.85%) (Figure-2). Among thyroid eye disease cases with proptosis 14 cases were hyperthyroid (70%), 05 cases were hypothyroid (25%) and 01 case was euthyroid (5%) (Table-1) (Figure-3).

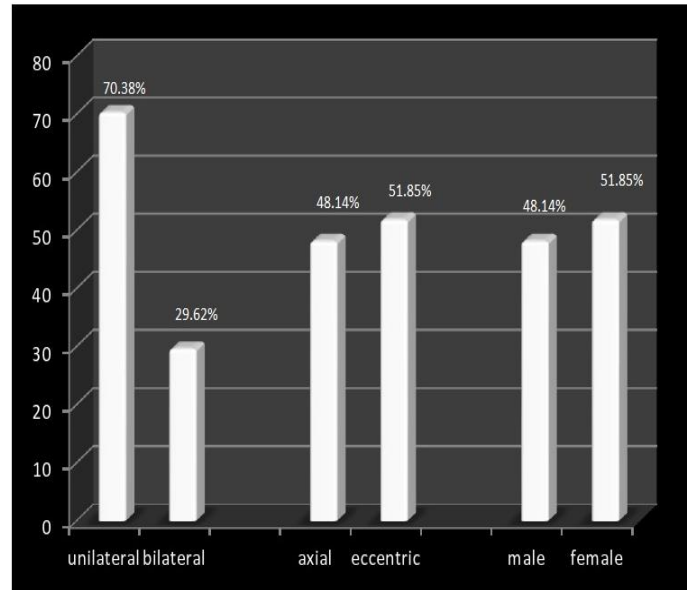


Figure 2: Bar diagram showing distribution of proptosis.

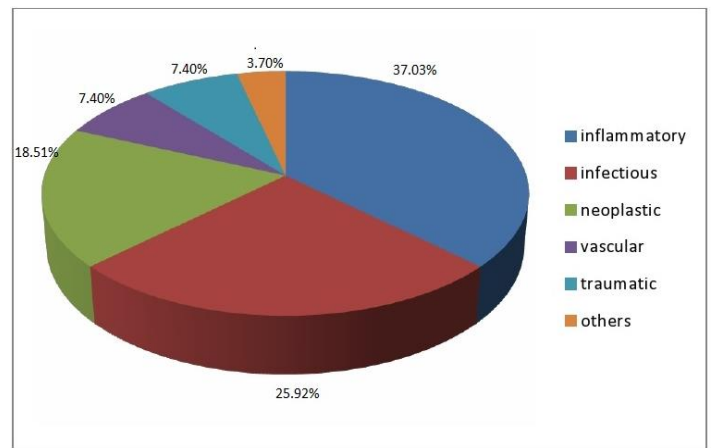


Figure 3: Pie diagram showing etiological distribution of proptosis.

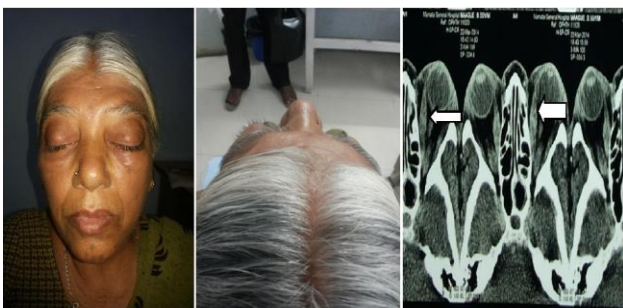

Figure 1: (A) Thyroid disease with bilateral proptosis. (B) Birds eye view showing asymmetric proptosis. (C) CT orbits showing enlargement of belly of extra ocular muscles.

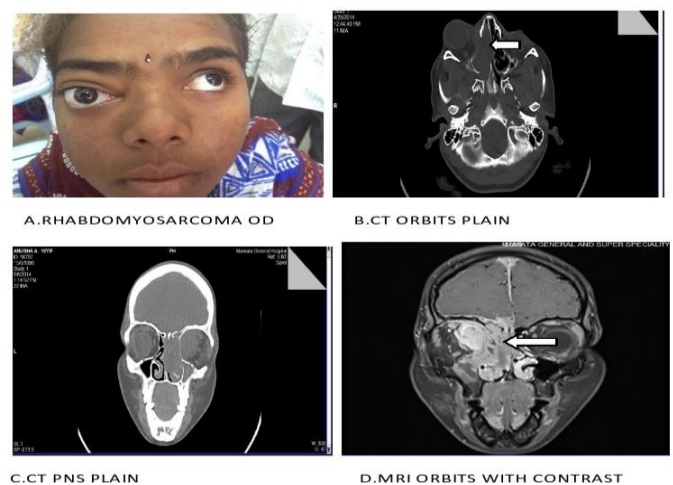


Figure 4: Rhabdomyosarcoma and orbits.

Table 1: Details of disease causing proptosis.

Causes	Number of cases	Percentage
Inflammatory	20	37.03%
Thyroid Eye Disease	20	37.03%
Infectious	14	25.92%
Orbital Cellulitis	10	18.51%
Cavernous Sinus Thrombosis	03	05.55%
Mucormycosis	01	01.85%
Tumors	10	18.51%
Dermoid Cyst	04	07.40%
Optic Nerve Glioma	02	03.70%
Burkitts Lymphoma	01	01.85%
Rhabdomyosarcoma	01	01.85%
Pleomorphic Adenoma	01	01.85%
Optic Nerve Sheath Meningioma	01	01.85%
Vascular	04	07.40%
Capillary Haemangioma	02	03.70%
Cavernous Haemangioma	02	03.70%
Traumatic	04	07.40%
Others	02	03.70%

Table 2: Comparison of various studies.

Study	Inflammatory	Infectious	Tumors	Vascular	Traumatic
Present Study	37.03%	25.92%	18.51%	07.40%	07.40%
Masud Mz Et Al	23%	20%	33%	07%	05%
Sabharwal Kk Et Al	18%	28%	46%	02%	06%
Sharma P Et Al	47%	03%	37%	10%	03%

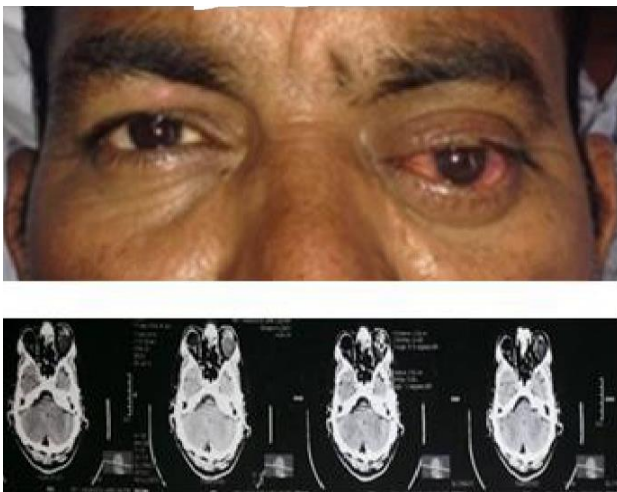


Figure 5: (A) OS showing eccentric proptosis due to lacrimal gland tumour (pleomorphic adenoma). (B) MRI orbit with brain showing retro orbital mass arising from lacrimal gland.

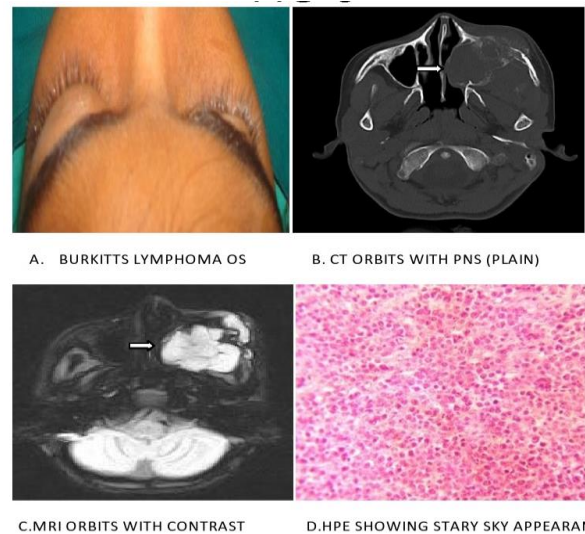


Figure 6: Burkitts lymphoma and orbits.

DISCUSSION

The most common cause of proptosis in our study was inflammation which is similar to Sharma P et al study. In contrast to this, Masud et al¹³ and Sabharwal et al¹⁴ showed tumor as the most common cause of proptosis. This could be due to small sample size.

In our present study, Graves's disease was seen in 25.92% patients of proptosis. Most of our patients had bilateral disease with inferior rectus being the most common muscle to be involved.

Among all patients of proptosis, infectious cases constituted 25.92%, which is similar to Sabharwal KK et al¹⁴ study (28%), Masud et al¹³ study (20%). In contrast to Sharma et al¹⁵ study this constituted 3%. Orbital cellulitis was the most common cause among infectious cases of proptosis in our study. Orbital cellulitis is more common in children and more severe in diabetics and immunocompromised patients.¹⁶ Cavernous sinus thrombosis was seen in 03 patients (5.55%).

In our study tumors constituted around 18.51%, where as in Masud et al study it was 33%, Sabharwal et al study 44% and in Sharma P et al study it was 37%. Dermoid cyst was seen in 04 patients (7.40%). It is a developmental choristoma, lined with epithelium and filled with keratinized material.¹⁷ The majority of such cysts are located in the eyelids and orbit. Optic nerve glioma is of (neoplasm of astrocytes)¹⁸ that affects primarily children (mean age, 8 yrs) which constituted 2 cases (3.70%). It frequently associated with type 1 neurofibromatosis.

Rhabdomyosarcoma is the most common soft tissue mesenchymal tumor in children, accounting for 3.4% of all childhood malignancies.^{19,20} The tumors arise from pluripotential mesenchymal precursors that normally differentiate into striated muscle cells. Boys are affected more commonly than girls at a ratio of 5:3 (Figure-4).

Lesions of the lacrimal gland include infiltrative processes (such as inflammatory diseases and lymphoma), structural disorders (such as cysts), and epithelial neoplasms.²¹ Epithelial tumors represent 20–25% of all lacrimal gland lesions. Almost all lacrimal gland lesions result in a mass effect, with swelling of the lateral eyelid and often with a downward and medial displacement of the globe. Pleomorphic adenomas occur mainly in the orbital lobe and rarely in the palpebral lobe of the lacrimal gland.²² They represent 3–5% of all orbital tumors, 25% of lacrimal mass lesions, and 50% of epithelial lacrimal gland tumors (Figure-5).

Orbital lymphomas comprise about 10% of all orbital neoplasms. Among the orbital lymphomas, non-Hodgkin's lymphoma (NHL) of ocular adnexa constitutes less than 1% of all cases of nodal and extra nodal NHL²² and accounts for about 8% of all extra nodal NHL.²³

Burkett's lymphoma is a cancer of the lymphatic system particularly B lymphocytes found in germinal center (Figure-6).

Optic nerve sheath meningioma is a benign neoplasm of meningotheial cells of arachnoid tissue²⁴ that affects primarily middle-aged adults (20–60 years). Women are involved slightly more commonly than men, at a ratio of 3:2. In 4–9% of cases there is an association with type 1 neurofibromatosis, and in 6% of cases the lesion may be bilateral.

In our study vascular causes of proptosis constituted around 4 cases (7.40%). Among these 02 cases (3.70%) were capillary and 02 cases (3.70%) were cavernous hemangiomas. Capillary hemangioma is a congenital hamartoma of tightly packed capillaries that typically presents during the first 6months of life.²⁵ It is generally unilateral and usually visible on the surface, but it may lie deep in the orbit. More common in the superonasal quadrant of the upper lid, Capillary hemangiomas show rapid growth over weeks to months, followed by slow spontaneous involution over months to years.

Cavernous hemangioma is a benign, noninfiltrative, slowly progressive tumor of large endothelial-lined channels.²⁶ Although it is congenital; it typically becomes symptomatic in adults (aged 20–40years). Cavernous hemangioma is usually found in an intraconal location, more commonly in the temporal quadrant.

Traumatic lesion accounted for 7.40% of the patients of proptosis. This is comparable with the study by Sabharwal KK et al and Masud MZ et al where traumatic lesion accounted for 6% and 5% of the patients of proptosis respectively.

According to our study inflammatory cases were 20 (37.03%), infectious 14 (25.92%), neoplastic 10 (18.515), vascular 4 (7.40%), traumatic 4 (7.40%), others 2(3.70%). Hence we conclude that inflammatory lesions are the most common cause of proptosis which is similar to Sharma P et al study (Table-2).

Funding: No funding sources

Conflict of interest: None declared

Ethical approval: Not required

REFERENCES

1. Bergin DJ, Wright JE. Orbital cellulitis. *Br J Ophthalmol.* 1986;70:174-8.
2. Wiersinga WM, Bartalena L. Epidemiology and prevention of Graves' ophthalmopathy. *Thyroid.* 2002;12:855–860.
3. Abraham-Nordling M, Bystrom K, Torring O, et al. Incidence of hyperthyroidism in Sweden. *Eur J Endocrinol.* 2011;165:899–905.

4. Danesh-Meyer HV, Rosser PM. Orbital inflammatory disease. *Int Ophthalmol Clin.* 2007;47:79–92.
5. Fisher RG, Boyce TG. *Moffet's Pediatric infectious diseases: a problem-oriented approach.* Philadelphia, PA: Lippincott Williams & Wilkins; 2005, p.102.
6. Baring DE, Hilmi OJ. An evidence based review of periorbital cellulitis. *Clin Otolaryngol* 2011; 36: 57-64. 10.1111/j.1749-4486.2011.02258.x
7. Cruz OA, Zarnegar SR, Myers SE. Treatment of periocular capillary hemangioma with topical Clobetasol propionate. *Ophthalmology.* 1995; 102(12):2012-2015.
8. Haik BG, Karcioglu ZA, Gordon RA, Pechous BP. Capillary hemangioma (infantile periocular hemangioma). *Surv Ophthalmol.* 1994(5);38:399-426.
9. Walker RS, Custer PL, Nerad JA. Surgical excision of periorbital capillary hemangiomas. *Ophthalmology.* 1994(8): 101: 1333-1340.
10. Oakhill A, Willshaw H, Mann JR. Unilateral proptosis. *Arch Dis Child* 1981;56:549-51.
11. Tamsin J, Sleep, Ruth M. Interinstrument Variability in Hertel Type Exophthalmometers. *J Ophth Plastic reconstructive surgery* 2002;18:254-7.
12. Rauniyar RK, Thakursk, Panda A. CT in diagnosis of isolated cysticercal infestation of extraocular muscle. *J Clin Radiology* 2003;58:154-6
13. Masud MZ, Babar TF, Iqbal A, et al. Proptosis-etiologic and demographic patterns. *J Coll Physicians Surg Pak* 2006;16:38-41.
14. Sabharwal KK, Chouhan AL, Jain S. CT evaluation of proptosis. *Indian J Radiol Imaging* 2006;16:683-8.
15. Sharma P, Tiwari PK, Ghimire PG, Ghimire P. *NJMS.* 2013;02(01):35-7.
16. Watters EC, Wallar H, Hiles DA, et al. Acute orbital cellulitis. *Arch Ophthalmol.* 1976;94:785.
17. Shields JA, Shields CL. Orbital cysts of childhood-Classification, Clinical features and management. *Surv Ophthalmol.*2004;49:281-99.
18. Dutton JJ. Gliomas of anterior visual pathways, *Surv Ophthalmol.*1993;38:427-52.
19. Shields JA, Shields CL. Rhabdomyosarcoma: review for the ophthalmologist. *Surv Ophthalmol* 2003;48:39-57.
20. Franca CM, Caran EM, Alves MT, et al. Rhabdomyosarcoma of the oral tissues – two new cases and literature review. *Med Oral Patol Oral Cir Bucal* 2006; 11:E136-40.
21. Lemke AJ, Hosten N, Neumann K, et al. Space occupying lesions of the lacrimal gland in CT and MRI exemplified by four cases. *Aktuelle Radiol* 1995;5:363-6.
22. Alyahya G.A., Stenman G., Persson F., et al: Pleomorphic adenoma arising in an accessory lacrimal gland of Wolfring. *Ophthalmology.* 2006; 113:879.
23. Keleti D, Flickinger JC, Hobson SR, Mittal BB. Radiotherapy of lymph proliferative diseases of the orbit. Surveillance of 65 cases. *Am J Clin Oncol.* 1992;15:422-7.
24. Freeman C, Berg JW, Cutler SJ. Occurrence and prognosis of extranodal lymphomas. *Cancer.* 1972;29:252-60.
25. Dutton JJ. Optic nerve sheath meningiomas. *Surv Ophthalmol* 1994; 37:167-183
26. Bilaniuk LT. Vascular lesions of the orbit in children. *Neuroimaging Clin N Am.* 2005;15:107-20.
27. Rootman J. Diseases of the orbit. A multidisciplinary approach. Philadelphia, JB Lippincott, 1988:119–139.

Cite this article as: Teja N, Reddy M, Vanama A. An etiological analysis of proptosis. *Int J Res Med Sci* 2015;3:2584-8.