

Case Report

Solitary fibrous tumor of nasal cavity: a rare case report with review of literature

Shubhangi Vinayak Agale*, Vidya Chandrakant Arole, Dipashri Bhaurao Jadhav,
Jai Vijay Juvekar

Department of Pathology, Grant Government Medical College, Mumbai, India

Received: 14 August 2015

Accepted: 07 September 2015

***Correspondence:**

Dr. Shubhangi Agale,

E-mail: shubhagale@hotmail.com

Copyright: © the author(s), publisher and licensee Medip Academy. This is an open-access article distributed under the terms of the Creative Commons Attribution Non-Commercial License, which permits unrestricted non-commercial use, distribution, and reproduction in any medium, provided the original work is properly cited.

ABSTRACT

Solitary fibrous tumor is an unusual soft tissue neoplasm. Commonly the tumor is located in pleural cavity but recently has been described in many extra-thoracic locations. Nose and paranasal sinuses are rare sites for this tumor and so far less than 30 cases have been reported in the literature. In the nasal cavity the tumor usually presents as a polypoidal intranasal mass in a middle aged patient. Erosion of adjacent structures may occur but tumor does not metastasize. Local excision is almost invariably curable. We report SFT in a 50 year old patient with involvement of unilateral nasal cavity and all paranasal sinuses.

Keywords: Solitary fibrous tumor, Nose, Paranasal sinuses

INTRODUCTION

Solitary fibrous tumor (SFT) is an unusual tumor which was previously known as fibrous mesothelioma/submesothelial fibroma, and was thought to arise from mesothelial cells.¹⁻⁶ Today SFT is described as a “mesenchymal” tumor¹⁻¹² as most investigators believe that their origin is mesenchymal, as evident by their fibroblastic differentiation histopathologically, immunohistochemically and ultrastructurally.^{3,4}

This fact also explains the occurrence of SFTs at numerous extrapleural sites. Extrapleural SFT is a rare entity. In a study by Gold JS et al⁵ extrapleural SFTs are accounted for 0.6% of all soft tissue tumors.

However over the years it has been reported at various extrapleural locations such as pelvic region, retroperitoneum, extremities, Head and neck region.¹⁻⁴ We report SFT of nasal cavity with involvement of paranasal sinuses in a 50 year male patient.

CASE REPORT

A 50 year old male presented with nasal blockage since 1 year. He also had discharge from the nose and altered sleep habits. There was no history of epistaxis, headache or any other chronic disease. Physical examination showed a polypoidal mass in left lateral side of nose with deviated nasal septum to right side.

CT scan revealed extensive polypoidal mucosal thickening involving all the sinuses and nasal cavities with deviation of nasal septum to the right side. No bony erosion or destruction was seen. Endoscopic removal of the mass was done.

Pathologic examination showed multiple greyish white, rubbery firm tissue bits, totally measuring 3.7x3x1.2 cm (Figure 1). Microscopy revealed an intact nasal mucosal lining with a submucosal spindle cell tumor arranged in “pattern less” pattern with areas of collagenisation. The mitotic activity was absent with absence of hemorrhage and necrosis (Fig 2a and 2b). Immunohistochemically tumor cells showed diffuse positivity for CD34 and CD99 (Fig 3a and 3b). Based on histomorphology and

immunohistochemistry the diagnosis of solitary fibrous tumor was rendered.

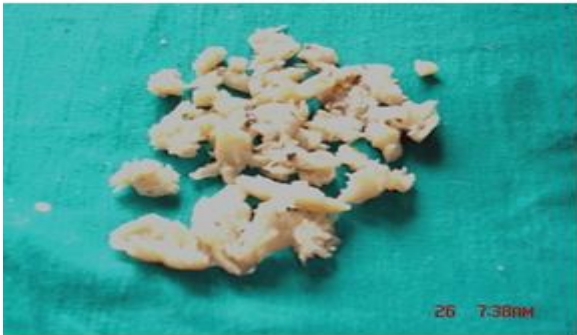

Figure 1: Grossly tumor was in multiple bits and totally measured 3.7x3x1.2 cm. Cut surface of tumor was solid, greyish white glistening with no areas of haemorrhage or necrosis.

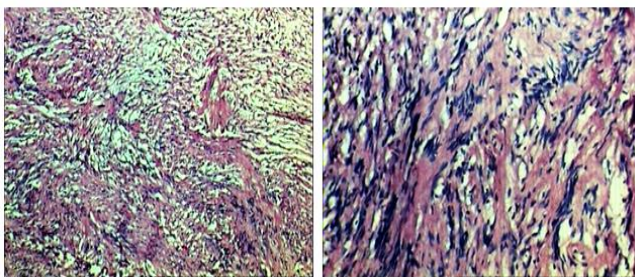


Fig. 2a

Fig 2b

Figure 2a: Microscopic examination showed “pattern less pattern” of spindle cells without necrosis (H&E, X40). 2b: Focally tumor showed high cellularity with spindle cells arranged in fascicles, spindle cells had indistinct cytoplasmic margins and were embedded in collagenous matrix, and nuclei were plump to spindle with low mitotic activity (H&E, X400).

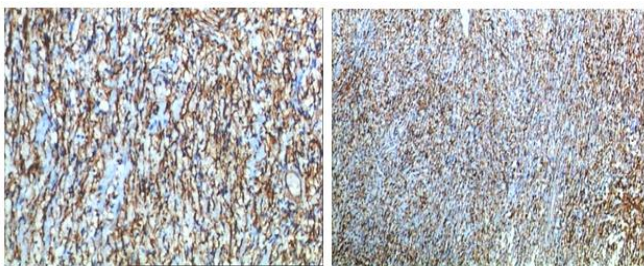


Fig. 3a

Fig. 3b

Figure 3a & 3b: Immunohistochemically cells showed diffuse cytoplasmic positivity for CD34 and CD 99.

DISCUSSION

SFT was thought to be exclusively located in the thoracic cavity as a pleural tumor.¹ In head and neck region SFT may involve meninges, oral cavity, orbit, soft tissue of head and neck, upper respiratory tract, nasal cavity,

paranasal sinuses, salivary glands, thyroid, parapharyngeal space and tongue.¹⁻⁴

The first case in the English literature of a solitary fibrous tumor arising in nasal cavity was reported by String fellow in 1996 in a 59 year old woman.¹³ In a review of literature, Alobid et al¹⁴ have mentioned 21 cases of primary SFT arising in nasal cavity and paranasal sinuses. Ahire et al¹⁰ have reported a case of SFT involving maxillary sinus and have mentioned that previously only 24 cases of SFT of nose and paranasal sinuses are reported in English literature.

To the best of our knowledge there are total 28 reported cases of SFT till date, involving nasal cavity including a case reported by Mathew et al.⁶ So the present case will be 29th case of solitary fibrous tumor of nose and paranasal sinuses.

Nasal SFT usually presents with unilateral nasal mass, nasal obstruction, rhinorrhoea, headache and epistaxis.^{3,11} Other signs and symptoms such as epiphora, facial pain, visual disturbances can also be present.^{3,8,11} Rhinoscopically nasal SFT is of 2 types (i) Greyish pinkish solid glistening tumor with smooth surface (ii) Rough reddish mass that bleeds easily.²

CT scan appearance is usually nonspecific with reactive remodelling of nasal bone.^{2,3} Clinically and radiologically differential diagnosis of nasal cavity SFT is nasopharyngeal angiofibroma, nasopharyngeal carcinoma, hemangio-pericytoma, benign and malignant fibrous histiocytoma and fibrosarcoma.^{4,9,11}

Pathological examination is decisive diagnostically and therapeutically.³ However pathological diagnosis is difficult as the tumor has histologic features that may mimic other soft tissue tumors such as schwannoma, benign and malignant fibrous histiocytoma, nasopharyngeal angiofibroma and fibrosarcoma.³⁻¹⁰

Macroscopically SFT is polypoidal, well circumscribed tan rubbery mass.^{2,3} Cut surface is usually tan, firm with whorled or nodular pattern.⁸ Histopathologically SFT is a low grade neoplasm of variable cellularity and characteristic “patterenless” pattern. The prominent features are spindle cells arranged randomly in collagenised stroma with keloid like ropy collagen and blood vessels with hemagio-pericytomatous pattern.^{2,6,8}

Nasopharyngeal angiofibroma is a common benign neoplasm of nasal cavity seen commonly in adolescent males. These tumors have characteristic histology of bland spindle cells admixed with many variable sized blood vessels. Similar to SFT the cellularity is low with bland looking spindle cells but presence of characteristic “patternless” pattern and collagenous background helps in differentiating SFT from nasopharyngeal angiofibroma.^{7,9}

Schwannoma is an encapsulated benign tumor less commonly seen in nasal cavity (<4%).¹² Microscopically presence of verocay bodies and myxoid background will help in differentiating these tumors from SFT.

Benign and malignant fibrous histiocytoma though rare in nasal cavity can mimic SFT on histology. Characteristic storiform pattern seen in benign and malignant fibrous histiocytoma can be seen focally in SFT however presence of multinucleated giant cells, cellular atypia and high mitotic activity in malignant tumors will help in differentiating them from SFT.⁷

Other fibrous tumors such as fibrosarcoma are rare in nasal cavity. They may mimic SFT clinically but can be differentiated from SFT microscopically and immunohistochemically. Presence of characteristic herringbone pattern, high cellularity and higher mitotic activity in fibrosarcoma will help in distinguishing them from SFT.^{7,9}

Immunohistochemically SFT shows diffuse positivity for CD34, CD99 and variable vimentin reactivity. These tumors are negative for S-100 protein, SMA, keratin, EMA, desmin and glial fibrillary acidic protein.⁴

Usually SFT has a benign behaviour but malignant variants are known to occur. Local recurrence and metastasis occurs depending on size of tumor, infiltration into surrounding tissue, state of surgical resection margins, cellularity, mitotic activity and necrosis.¹⁻¹⁰

Complete surgical resection is usual treatment for nasal SFTs.⁴ Nowadays endoscopic excision is a preferred surgical approach for SFT of nasal cavity. Other approaches are lateral rhinotomy, medial maxillectomy, external ethmoidectomy; transfacial endoscopic removal.⁶ Complete surgical removal may prove difficult because of proximity to vital structures and possibility of profuse bleeding.⁴

As the resectability is the most important prognostic factor, effective treatment of SFT of nose and paranasal sinuses involves en-block resection.⁶

CONCLUSION

In conclusion, solitary fibrous tumor of nasal cavity with extensive involvement of paranasal sinuses is rare. SFT has to be differentiated from other nasal / paranasal sinus tumors based on histomorphology and immunohistochemistry.

Funding: None

Conflict of interest: None declared

Ethical approval: Not required

REFERENCES

- Daigeler A, Lehnhardt M, Langer S, Steintraesser L, Steinau H, Mentzel T, et al. Clinicopathological findings in a case series of extrathoracic solitary fibrous tumors of soft tissues. BMC Surgery. 2006; 6:10.
- Terumichi F, Ishida M, Sekine K, Aoki H, Okubo K. Solitary fibrous tumor arising from the superior nasal turbinate: A case report. J Nippon Med Sch. 2012;79:373-6.
- Zeitler DM, Kanowitz SJ, Har-EL G. Malignant solitary fibrous tumor of nasal cavity. Skull Base. 2007;17(4):239-45.
- Hicks DL, Moe SK. Nasal solitary fibrous tumor arising from the anterior cranial fossa. Skull Base. 2004;14:203-7.
- Gold JS, Antonescu CR, Hajdu C, Ferrone CR, Hussain M, Lewis JJ, et al. Clinicopathologic correlates of solitary fibrous tumors. Cancer. 2002;94(4):1057-68.
- Mathew GA, Ashish G, Tyagi AK, Chandrashekharan R, Paul RR. Iranian Journal of Otorhinolaryngology. 2015;27(4):307-11.
- Chauhan SS, Krishnan J, Heffner DK. Solitary Fibrous Tumor of Nasal Cavity in Patient with Long -Standing History of Cocaine Inhalation. Arch Pathol Lab Med. 2004;128(1):e1-4.
- Rajaan KV, Santhi T. A case of solitary fibrous tumor of nose and paranasal sinuses. Indian Journal of Otolaryngology and Head and Neck Surg. 2006;58(3):316-8.
- Pace Balzan J, Fenech A, Degaetano J. Solitary Fibrous Tumour of Nose and Nasopharynx. Maltese Medical Journal. 1993;5(2):39-41.
- Ahire D, Nagle S, Jagade MV, Agarwal S, Joshi S, Kashide R et al. Solitary Fibrous Tumor in the Maxillary Sinus Treated By Caldwell Luc Surgery. Scientific reports. 2013;2(2).
- Nai GA, Neto GCR. Solitary fibrous tumor of the nasal cavity. Braz J Otorhinolaryngol. 2009;75(5):769.
- Fanburg-Smith JC, Thompson LDR. Benign soft tissue tumors. In World Health Organisation classification of tumors. Pathology and genetics of head and neck tumors. IARC press: Lyon 2005,47-48.
- Stringfellow HF, Khan IA, Sissons MCJ. Solitary fibrous tumour arising in nasal cavity: report of a case. The journal of Laryngology and Otology 1996;110:468-70.
- Alobid I, Alos L, Blanch JL, Benitez P, Bernal-Sprekelsen M, Mullol J. Solitary fibrous tumors of nasal cavity and paranasal sinuses. Acta otolaryngol 2003;123:71-4.

Cite this article as: Agale SA, Arole VC, Jadhav DB, Juvekar JV. Solitary fibrous tumor of nasal cavity: a rare case report with review of literature. Int J Res Med Sci 2015;3:2877-9.