

## Case Report

# A patient presenting with recurrent post-prandial abdominal discomfort and vomiting

Ashis Kumar Saha<sup>1\*</sup>, Payodhi Dhar<sup>2</sup>, Abhiparna Roy<sup>2</sup>, Soumesh Roy<sup>2</sup>

<sup>1</sup>Associate Professor, <sup>2</sup>Junior Resident, General Medicine, K P C Medical College, Jadavpur, Kolkata, India

**Received:** 15 August 2015

**Revised:** 04 September 2015

**Accepted:** 07 September 2015

### \*Correspondence:

Dr. Ashis Kumar Saha,

E-mail: [asissaha2008@gmail.com](mailto:asissaha2008@gmail.com)

**Copyright:** © the author(s), publisher and licensee Medip Academy. This is an open-access article distributed under the terms of the Creative Commons Attribution Non-Commercial License, which permits unrestricted non-commercial use, distribution, and reproduction in any medium, provided the original work is properly cited.

## ABSTRACT

Duodenal diverticulum is the second most common diverticulum of gastrointestinal tract. Among duodenal diverticulum, incidence of intramural duodenal diverticulum is 100 as per report till date. It is usually asymptomatic, but in middle or adult age, it may present with postprandial abdominal discomfort, often complicates in the form of bleeding, perforation or rarely neoplasm. So, this congenital duodenal deformity requires urgent definitive treatment. Here we presented a case presenting with postprandial abdominal discomfort with occasional vomiting. He was advised upper gastrointestinal endoscopy. It showed evidence of duodenal septa at the junction of 1st and 2nd part. Scope was negotiated through one channel. He was advised barium meal of stomach, duodenum and follow through, which ultimately demonstrated presence of a rare abnormality, duodenal intramural diverticulum, which if not treated, can produce severe complication in future.

**Keywords:** Upper gastro duodenal endoscopy, Barium meal of stomach duodenum, Postprandial abdominal discomfort, Intramural duodenal diverticulum

## INTRODUCTION

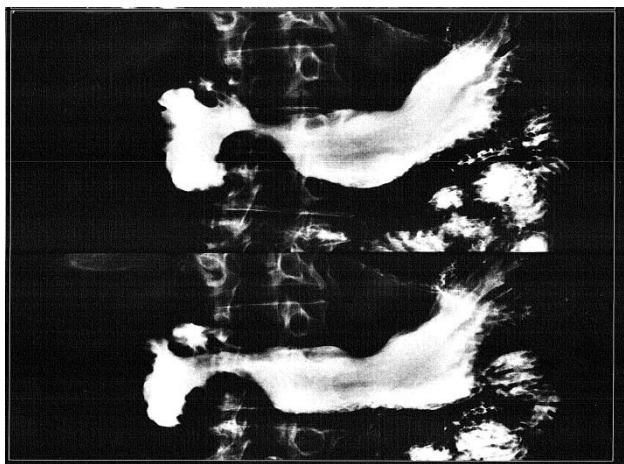
Upto twenty-five percent patients demonstrate duodenal diverticula. Chromall in 1710, first reported about duodenal diverticulum and was first documented by Morgagni in 1762 and first radiologically demonstrated in 1913. It is the second most common diverticula after colon followed by jejunum, ileum and stomach.<sup>1,2</sup> Duodenal diverticulum is usually classified into primary and secondary diverticulum, the latter usually results from chronic duodenal ulceration.<sup>3</sup> Primary diverticula usually occur between 50 to 60 years of age.<sup>1,3,4,5,6</sup> These primary diverticula again are classified into external and intramural diverticula. There is no sex predilection in the incidence of diverticula.<sup>1,2,3,4,6</sup> Only 100 case of Intramural duodenal diverticulum, a rare anatomical abnormality are documented till date. Majority patients with diverticula are asymptomatic.<sup>1,3,5,7,8,9</sup> Some patients

usually present with postprandial abdominal pain, discomfort with or without vomiting, rarely gastrointestinal bleeding and weight loss.<sup>1,3,5</sup> Here we presented a case presented with postprandial abdominal discomfort.

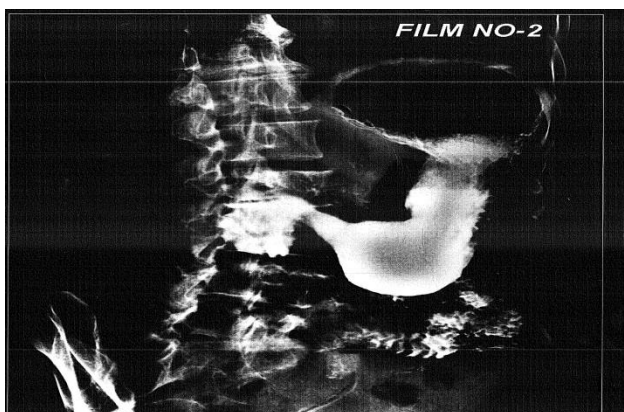
## CASE REPORT

52 years old patient presented with recurrent postprandial abdominal discomfort as well as occasional bleeding. His hematological biochemical parameters, routine stool and urine examinations were within normal limit. He was advised for upper gastrointestinal endoscopy. Endoscopic picture showed presence of a septum at the junction of 1st and 2nd part producing two channels. Scope was negotiated through lateral channel towards 2nd part, but not through medial channel. So barium meal of stomach, duodenum and follow through was advised. This barium

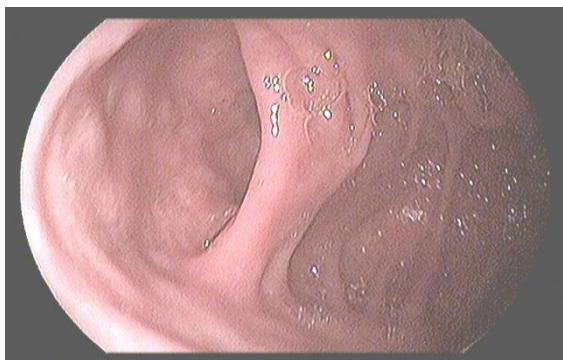
meal study demonstrated the presence of a filling defect stating from the 2nd part with presence of two channels on both sides of filling defect. In the medial channel there was hold-up of barium looking like pedunculated polyp, but through the lateral channel barium reached jejunum, it was diagnosed as a case intramural duodenal diverticulum.



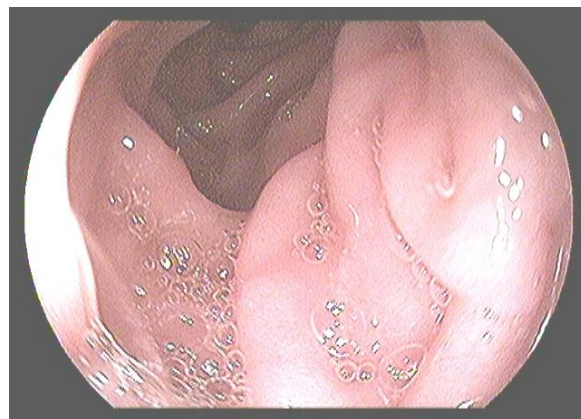
**Figure 1: Barium meal of stomach and duodenum showed Hold up of barium in duodenum looking like pedunculated polyp.**



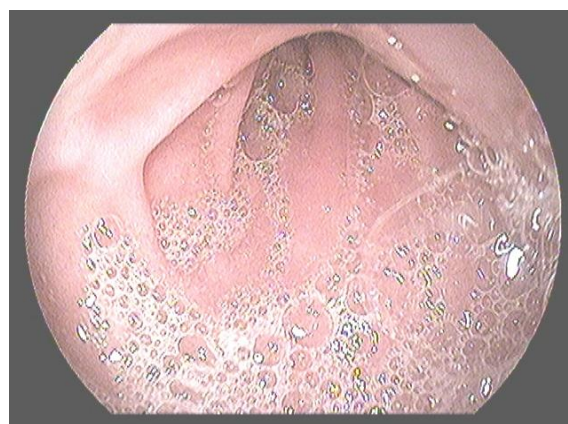
**Figure 2: Barium meal of stomach and duodenum showed two channels in the duodenum pushing barium through both the channels.**



**Figure 3: Endoscopy of duodenum showed junction of the proximal part of diverticulum in the duodenum.**



**Figure 4: Endoscopic picture showed passage of scope through one channel to the third part.**



**Figure 5: Endoscopic picture showed the passage through the other channel.**

## DISCUSSION

If we see the method of development of duodenum in the foetal life, it shows the following stages: In the fifth week of gestation, second to fourth part of duodenum becomes obliterated by proliferation of duodenal epithelium. But since early sixth week, vacuolization starts producing two separate channels, lateral and medial. At the eight week, both the channels coalesce. Abnormality in the communication and channelization produces the following types of congenital duodenal abnormalities, like, duodenal atresia, duodenal stenosis, intraluminal duodenal diverticulum, obstructing mucosal diaphragm and duodenal duplication. Intraluminal duodenal diverticulum results from incomplete canalization of one or both channels. As a result, one duodenal channel ends blindly and attaches to a small part of duodenal wall. So, in these patients, there will be hold up of food in the diverticulum. If the amount of food will gradually increase in the diverticulum, patient may vomit. Patient usually presents in the adulthood with postprandial abdominal bloating with or without vomiting. Our patient also presented in adulthood with postprandial abdominal distension with recurrent vomiting. This patient usually requires endoscopic therapy unless he or she is too frail to

tolerate it. Definitive treatment is laparoscopic removal of diverticulum or duodenostomy if patient cannot tolerate therapeutic endoscopic procedure by means of electrocautery. During endoscopic treatment of this intramural diverticulum care must be taken not to injure the papilla. If the attachment is not circumferential endoscopic resection with electrocautery snare is the procedure of choice. But if the attachment is circumferential, endoscopic inversion of the diverticulum followed by partial resection to produce an opening of at least 1 cm. in diameter at the blind end is the definite method of choice.

## CONCLUSION

Though this is a rare condition, but, its diagnosis is of immense importance, because, it can produce complications like, severe bleeding, obstruction, perforation and rarely, neoplasm. So, urgent intervention is always required in case of accidental diagnosis of intraluminal duodenal diverticulum.

*Funding: None*

*Conflict of interest: None declared*

*Ethical approval: Not required*

## REFERENCES

1. Pimparkar BD. Diverticulosis of small intestine In: Bockus Henry L, (Ed). Gastroenterology. 3rd (Ed). Philadelphia: WB Saunders Co 1976;437-58.
2. Knoefel WT, Rattner DW. Duodenal diverticula and duodenal tumors In: Morris PJ, Malt RA (Ed). Oxford of Surgery. New York: Oxford University Press 1994;1:943-946.
3. Cheshire NJ, Glezer G. Diverticula, Volvulus, superior mesenteric artery syndrome and foreign bodies. In: Zinner MJ, Schwartz SI, Ellis H, (Ed). Maingot's Abdominal operation 10th (Ed). London: Prentice Hall International Inc (UK) Limited 916-921.
4. Lobo N, Balfour TW, Iftikar SY, Rowlands BJ. Periapillary diverticula and pancreaticobiliary disease. Br J Surg. 1999;86:588-97.
5. Harford WW. Diverticula of hypopharynx and esophagus, the stomach and small bowel. In: Feldman M, Scharschmidt BF, Sleisenger MH, (Ed). Sleisenger and Fordtran's Gastroenterology and Liver Diseases. 6th (Ed). Philadelphia: WB Saunders Co. 1998;1:313-316.
6. Lane JE, Ajjan M, Sedghi S. GI bleeding from duodenal diverticula. Am J Gast. 2001;2799.
7. Yin wee, Chen HT, Huang SM, Lin HH, Chang TM. Clinical analysis and literature review of massive duodenal diverticular bleeding. World J Surg 2001;25:848-55.
8. Rioux L, Des Groseilliers S, Fortin M, Mutch do. Massive upper gastrointestinal bleeding originating from a fourth stage duodenal diverticulum: A case report and review of literature. Can J Surg. 1996;39:510-2.
9. Afridi SA, Fitchbaum CJ, Taubin H. Review of duodenal diverticula. Am J Gastroenterology. 1991;86:935-8.

**Cite this article as:** Saha AK, Dhar P, Roy A, Roy S. A patient presenting with recurrent post-prandial abdominal discomfort and vomiting. Int J Res Med Sci 2015;3:2880-2.