

Research Article

The effect of induction chemotherapy followed by chemoradiotherapy in advanced head and neck cancer: a prospective study

Bhushan M. Nikam*, Kailash K. Singh, Rohan Kharde,
Siddharth Nagshet, Dipalee Borade, Zaiba Moosa

Department of Radiotherapy & Oncology, Rural Medical College, Pravara Institute of Medical Sciences, Loni-413736, Ahmednagar, Maharashtra, India

Received: 6 January 2014

Accepted: 2 February 2014

*Correspondence:

Dr. Bhushan M. Nikam,

E-mail: drbhushan11@gmail.com

© 2014 Nikam BM et al. This is an open-access article distributed under the terms of the Creative Commons Attribution Non-Commercial License, which permits unrestricted non-commercial use, distribution, and reproduction in any medium, provided the original work is properly cited.

ABSTRACT

Background: Objective of current study was to observe the local control, progression free survival and organ preservation for locally advanced head and neck cancer by using induction Chemotherapy followed by concurrent chemoradiotherapy.

Methods: 102 patients enrolled in this study with stage III-IVB of head & neck cancer. Patients were assessed and treated by faculty of the department as per NCCN guidelines. Group A patients received three courses of cisplatin ($100\text{mg}/\text{m}^2$) and paclitaxel ($175\text{mg}/\text{m}^2$) at every 21 days interval followed by concurrent chemoradiotherapy with cisplatin $30\text{mg}/\text{m}^2$ on weekly basis while group B received only concurrent chemoradiotherapy. Radiotherapy consisted of total dose up to 66-70 Gy, by conventional fractionation schedule.

Results: From August 2011 to July 2013, total 102 patients have completed 14 months of follow up after completing definitive treatment group A : 48 and group B: 54 patients. Response evaluation was done after one and half months of completion of chemoradiotherapy in both arms. Complete response rate was 60.42% and 38.88 % in study and control arm respectively while partial response was 72.92% and 55.56%. Most common grade III or IV toxicity was mucositis in group A and skin reaction in control arm. At a median follow-up 13 months the median progression free survival in group A was 11.5 months and 9 months in group B.

Conclusion: Response to induction chemotherapy was useful as predictive factor for ultimate outcome and progression free survival. But our study shows statistically significant improvement in complete response rate in group A as compared to group B ($p < 0.05$). Our induction chemotherapy with two-drug regimen followed by concurrent chemoradiotherapy was well tolerated with manageable toxicity and good locoregional control.

Keywords: Induction chemotherapy, Chemoradiotherapy, Head and neck cancer

INTRODUCTION

Head and neck cancers constitute 5% of all cancers worldwide and in the Indian population, it accounts above 50% of all malignant tumours. Most of the patients present with locally or locoregionally advanced disease. As a result of their location, these tumors can cause

varying degree of functional and cosmetic deformity that are often exacerbated by cancer treatment.

Larynx preservation trial 1991,¹ the non-surgical organ preservation through the radiation and chemotherapy entered the main stream. Since then the most significant advances in the treatment of head and neck tumours have been the development of altered fractionation schedules

and concurrent chemotherapy regimen that have documented improvements in local control and overall survival

Currently three multimodality treatment approaches are used in treatment of head and neck cancer. The first approach is surgery, followed by adjuvant concurrent chemoradiotherapy, which enables precise pathologic staging and identification of high risk features that influence the choice of adjuvant treatment. The second approach is definitive concurrent chemoradiotherapy with surgery as an optimal salvage or completion treatment. It has the advantage of improved organ preservation.

The third approach is use of induction chemotherapy followed by definitive local therapy.^{2,3} Advantages include the potential to decrease the risk of distant failure and a rapid reduction in tumour bulk in responders. A response to induction appears to predict responsiveness to chemoradiotherapy.

Induction chemotherapy has been frequently administered in advanced head and neck cancer with an overall response rate often exceeding 75%.^{4,5} Two large landmark trials the TAX323 and TAX324, had highlighted the role of induction chemotherapy in unresectable and locally advanced head and neck cancer. The use of three drug regimen in these trials led to response rates of around 68 to 70%.

The aim of this study is to evaluate the feasibility and outcome of a two drug induction regimen with combined cisplatin and paclitaxel. In general; most trials of concurrent chemoradiation have not documented reductions in the rates of distant metastases with the addition of concurrent chemotherapy to radiotherapy. As a result, the survival benefit imparted by chemotherapy is primarily due to improvements in local control.^{6,7}

In view of these findings we performed an observational study to observe the effectiveness of two drug chemotherapy regimen administered as induction treatment in patients with locally advanced unresectable head and neck cancer. The primary objective of this study is to compare progression free survival rate between study and group B. Secondary end points included assessment of overall survival, toxicities and organ preservation rate.

METHODS

This was a prospective study was conducted in the department of radiotherapy and oncology, Pravara rural hospital, Loni during period from August 2011 to July 2013. Total 102 Patients of locally advanced head and neck squamous cell carcinoma treated by faculty in the department of radiotherapy and oncology were included for the study. A written and informed consent was taken. Then patients were given induction chemotherapy and

chemoradiotherapy as per the decision taken by faculty which was best for patient.

Inclusion criteria

1. Patient must have histopathologically confirmed, stage III, stage IVa, IVb, H&N, SCC.
2. Patient must have no prior exposure to chemotherapy, radiotherapy, surgery.
3. Patients with age <70 yrs, performance status <2 (ECOG), and with normal haematocrit, renal and liver function.

Exclusion criteria

1. Prior history of surgery, chemotherapy or radiotherapy for the present condition.
2. Severe medical illness like chronic renal failure, CCF, IHD.
3. Nasopharyngeal carcinoma and thyroid tumours.

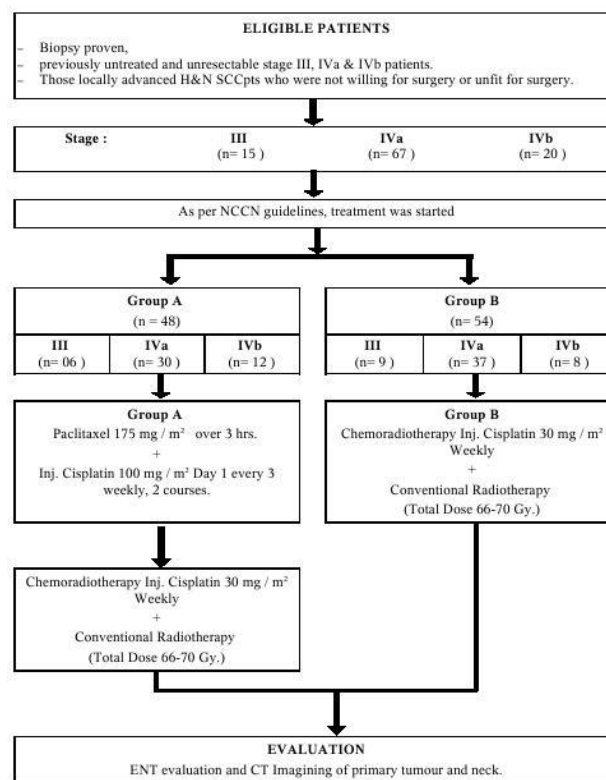


Figure 1: Flow chart.

Two cycles of chemotherapy were infused at an interval of 21 days.

Before infusion of chemotherapy complete blood count, RFT and LFT were done and should be within normal limit to start next cycle.

Group A: For patients in this arm Induction chemotherapy with Inj. paclitaxel (175 mg/m²) and cisplatin(100 mg/m²), for 2 cycles at 21 days interval was given. It was then followed by concurrent

chemoradiotherapy with Inj.cisplatin 30 mg/m² weekly for 6-7 cycles.

Group B: Only chemoradiotherapy with Inj. cisplatin 30 mg/m² weekly for 6-7 cycles was given.

Both groups have been treated with radiotherapy in a dose of 200 cGy per day for five day in a week up to 6600 to 7000 cGy.

Radiotherapy field include primary as well as lymphatic drainage area. Two parallel opposite portal was planned. After 4600 cGy spine was spared.

At the end of study following parameters were assessed:

1. Effectiveness: It was observed in terms of
 - A. Response: After completion of definitive treatment in both group A and B.
 - B. Progression free survival: It was defined as the time from date of inclusion in either groups to disease progression or death from any cause without progression which ever occurred first.
2. Safety assessment: It was observed in terms of toxicities.

The patient toxicities evaluated daily during treatment and subsequent follow up and toxicities were graded according to Common Terminology Criteria for Adverse Events v3.0 (CTCAE). The response was evaluated after completion of the chemotherapy and radiotherapy.

Response evaluation is done by using RECIST 1.1 criteria.

RESULTS

From August 2011 to July 2013, total 102 patients were recruited. Out of these, group A included 48 patients and Group B had 54 patients respectively. All these patients have completed one and half year of follow up after completing definitive treatment. Response evaluation was done after six to eight weeks of completion of chemoradiotherapy in both arms. The baseline characteristics of our patient population are listed in Figure 2. Median age of population was 55 years ranging from 22 - 75 years.

Patient characteristics

48 patients received two drug regimen for two cycle followed by chemoradiotherapy and 54 patients received only chemoradiotherapy. Response evaluation was as per RECIST 1.1 criteria. Complete response was achieved in 60.42% patients in group A and 38.88% patients in group B. Partial Response was seen in 22.92% patients in group A and 55.56% patients in group B. Progressive disease

was observed 16.66% and 05.56% patients in study and group B respectively. After applying chi-square test the association found was statistically significant (i.e. p <0.05). So we can say that group A is more effective than group B.

Table 1: Showing patient characteristics.

		Group A		Group B	
		No. of patient	%	No. of patient	%
Age (Median age 55)	55	48	100%	54	100%
Sex	M	35	73%	38	70%
	F	13	27%	16	30%
Perform-ance status	0	12	25%	09	16%
	1	22	46%	29	54%
	2	14	29%	16	30%
Site	Oral cavity	24	50%	31	57%
	Oro pharynx	11	23%	15	28%
	Larynx	07	15%	05	09%
	Hypo pharynx	06	12%	03	06%
TNM staging	III	06	13%	09	17%
	IVA	30	63%	37	69%
	IVB	12	24%	08	14%

Response (RECIST 1.1)

Table 2: Showing response.

Response	Group A		Group B	
	No. of patient	%	No. of patient	%
CR	11	22.92%	30	55.56%
PR	08	16.66%	03	05.56%
PD	29	60.42%	21	38.88%

Progression free survival

By applying Z test of proportion there is a significant difference between proportion of median progression free survival (PFS) between group A and group B. The median PFS in group A is significantly higher i.e. 11.5 months as compared to Group B i.e. 9 months.

Toxicity

The main toxicities NACT were vomiting (5%), neutropenia (5%), and diarrhea (4%). Grade III and Grade IV toxicities like mucositis, skin reactions and Bone marrow toxicity were common in group A. Even though the toxicities were high in group A as compared to group B, but they were tolerable and acceptable.

Side effect of chemotherapy**Table 3: Showing side effect of chemotherapy.**

Grade/groups	Nausea & vomiting		Skin		Mucositis		Diarrhea		Neutropenia	
	A	B	A	B	A	B	A	B	A	B
I	33%	17%	10%	80%	21%	33%	8%	7%	27%	3%
II	44%	5%	15%	12%	12%	21%	2%	6%	33%	0%
III	3%	0%	75%	4%	17%	02%	2%	0%	3%	0%
IV	2%	0%	0%	0%	04%	0%	2%	0%	2%	0%
None	18%	78%	0%	4%	46%	44%	86%	87%	35%	97%

DISCUSSION

This study provide follow-up of patients of locally advanced head and neck squamous cell carcinoma (HNSCC) treated with an neoadjuvant chemotherapy (NACT) with paclitaxel / cisplatin based regimen followed by concomitant cisplatin / radiation compared with only concomitant cisplatin / radiation. The indications for NACT are not well defined in clinical practice. NACT is used keeping in mind that it could help in control of micro metastasis and might downstage the tumour and hence making lesions operable.^{8,9} Only two positive phase III trials of induction chemotherapy have been published to date: the Gruppo di Studio sui Tumori della Testa e del Collo, which showed a survival benefit for patients who were considered ineligible for resection and the Groupe d'Etude des Tumeurs de la Te'te et du Cou, which was limited to oropharynx cancer. Thus, the benefit of induction chemotherapy in clinical practice compared with the present standard CT/RT is unclear.

Our goal was to identify regimen that optimizes local and distant control for organ preservation and cure in patients with HNSCC. For this purpose we used paclitaxel and cisplatin as induction chemotherapy regimen. Our centre is a rural setup with economically poor patients who can not afford docetaxel and infusional 5FU based regimen with G-CSF support. So we modified our regimen to two drugs. Responses were radiologically evaluated 6-8 weeks after the end of treatment, consistently with the usual timing in clinical practice. However, no data on the best method and optimal timing for evaluating responses in SCCHN have been published to date.

In our study, complete response was achieved in 60.42% patients in group A and 38.88% patients in group B. Partial Response was seen in 22.92 % patients in group A and 55.56% patients in group B. Progressive disease was observed 16.66% and 05.56% patients in study and group B respectively. These results are quite similar with a study by Paccagella et.al.¹⁰ a randomized phase 2 Italian study. Two groups were compared: TPF followed by chemoradiotherapy versus chemo radiotherapy alone.

During chemoradiotherapy, PF was used as the chemotherapy backbone in both groups. The primary endpoint was complete radiographic response. The study showed the sequential chemoradiotherapy group to be better than the concurrent group, with higher complete response rates: 21.2% for concurrent versus 50% for sequential.¹⁵ These findings led to the Italian phase 3 study comparing the two treatments. This study has completed accrual and is waiting for sufficient follow-up before reporting. After a median follow-up of 42 months, 32 patients (62.7%) in arm A and 26 patients (52.0%) in arm B progressed or died; median PFS was 19.7 and 30.4 months, respectively. But in our study with median follow up of 13 months, the median progression free survival in group A was found to be significantly higher i.e. 11.5 months as compared to group B i.e. 9 months. Toxicities were acceptable with NACT (Group A) in our study with grade 3 and 4 neutropenia and thrombocytopenia in 3 and 2 % and vomiting in 3 and 2% respectively. The most relevant nonhematologic toxic effects (mucositis, skin toxicity, and diarrhea) were not much higher with group A as compared to group B. It also highlights that two drug combination of taxane with platinum needs to be investigated further to replace three drug combination.

CONCLUSION

In conclusion the results of our study indicate that induction chemotherapy with paclitaxel and cisplatin followed by concurrent chemoradiotherapy is superior to chemoradiotherapy in terms of radiological complete response and progression free survival. But in clinical practice the question of whether the addition of induction chemotherapy to concurrent chemoradiotherapy will improve survival over concurrent chemoradiotherapy alone remains unfortunately unanswered and it might be answered soon with more randomized phase III trials comparing both modalities. Both treatment modalities are effective in the treatment of head and neck cancer. A cost-benefit and quality-of-life analysis might prove beneficial in addressing the true value of induction chemotherapy. But the treating oncologist will have to

decide about how to best treat patient, based on available evidence.

Funding: No funding sources

Conflict of interest: None declared

Ethical approval: The study was approved by the Institutional Ethical Committee

REFERENCES

1. Psyrri A, Kwong M, DiStasio S, Lekakis L. Cisplatin, fluorouracil, and leucovorin induction chemotherapy followed by concurrent cisplatin chemoradiotherapy for organ preservation and cure in patients with advanced head and neck cancer: long-term follow-up. *J Clin Oncol.* 2004 Aug;22(15):3061-9.
2. Posner MR, Glisson B, Frenere G et al. Multi center phase I-II trial of docetaxal, cisplatin, and fluorouracil induction chemotherapy for patients with locally advanced squamous cell cancer of the head and neck. *J Clin Oncol.* 2001;19:1096-1104.
3. Forastiere A, Maor M, Weber R et al. Long term results of Intergroup RTOG 91-11: a phase III trial to preserve the larynx-induction cisplatin/5-FU and radiation therapy versus concurrent cisplatin and radiation therapy versus radiation therapy. *Proc Am Soc Clin Oncol.* 2006;24(18 Suppl):5517.
4. Merrill S, Kies et al. Induction chemotherapy followed by concurrent chemoradiation for advanced head and neck cancer: Improved disease control and survival. *Jr. Clin. Oncology.* 1998 August;16(8):2715-21.
5. Katori H, Tsukuda M. Comparison of induction chemotherapy with docetaxel, cisplatin, and 5-fluorouracil (TPF) followed by radiation vs. concurrent chemoradiotherapy with TPF in patients with locally advanced squamous cell carcinoma of the head and neck. *Clin Oncol (r Coll Radiol).* 2005 May;17(3):148-52.
6. Borone C, Grillo R, Dongiovanni D et al. Induction chemotherapy followed by concurrent chemoradiotherapy in advanced head and neck squamous cell carcinoma. *Anticancer Res.* 2008 Mar-Apr;28(2B):1285-91.
7. Marshall R, Ponsler et al. Role of Induction chemotherapy in the curative treatment of squamous cell cancer of head and neck. *Seminars Oncol.* 2000 Aug; 27(4 Suppl 8):13-24.
8. Bernier J, Bentzen SM. Altered fractionation and combined radio-chemotherapy approaches: Pioneering new opportunities in head and neck Oncology. *Eur J cancer.* 2003;39:560-71.
9. Specenier PM, Vermorken JB. Neoadjuvant chemotherapy in Head and Neck cancer: should it be revisited? *Cancer Left.* 2007;256:166-77.
10. Zorat PL, Paccagnella A, Cavaniglia G et al. Randomized phase II trial of neoadjuvant chemotherapy in head and neck cancer: 10 years follow-up. *J Natl Cancer Inst.* 2004;96:1714-7.
11. Haddad RI, Rabinowits G, Tishler RB et al. Induction chemotherapy followed by concurrent chemoradiotherapy (Sequential chemoradiotherapy) versus concurrent chemoradiotherapy alone in locally advanced head and neck cancer (PARADIGM): A randomized phase III trial. *Lancet Oncol.* 2013;14:257-64.
12. Cohen EW, Karrison T, Kocherginsky M et al. The DeCIDE Study: A phase III randomized trial of docetaxel (D), cisplatin (P), 5-Fluorouracil (F) (TPF) induction chemotherapy (IC) in patients with N2/N3 locally advanced squamous cell carcinoma of the head and neck (SCCHN). *J Clin Oncol.* 2012;30(suppl):356s.
13. Schrijvers D, Van Herpen C, Kerer J et al. Docetaxel, cisplatin and 5-fluoro-uracil in patients with locally advanced unresectable head and neck cancer: a phase I-II feasibility study. *Ann Oncol.* 2004;15:638-45.
14. Adelstein DJ, Moon J, Hanna E, Giri PG et al. Docetaxel, cisplatin, and fluorouracil induction chemotherapy followed by accelerated fractionation/concomitant boost radiation and concurrent cisplatin in patients with advanced squamous cell head and neck cancer: A southwest oncology group phase II trial (S0216). *Head Neck.* 2010 Feb;32(2):221-8.
15. Everett E, Vokes, Merrill Kies et al. Induction chemotherapy followed by concurrent chemoradiotherapy for advanced head and neck cancer: Impact on natural history of disease. *Jr. Clin Oncol.* 1995 April;13(4):876-83.
16. Semrau S, Waldfathere Female, Lell M et al. Feasibility, toxicity and efficacy of short induction chemotherapy of docetaxel plus cisplatin or carboplatin followed by concurrent chemoradiotherapy for organ preservation in advanced cancer of the hypopharynx, larynx, and base of tongue. Early results. *Strahlenther Oncol.* 2011 Jan;187(1):15-22.
17. M. Yamouni, Y. Beldjilali, K. A. Benhadji. A phase II trial of induction chemotherapy with cisplatin, docetaxel, and capecitabine followed by concurrent cisplatin-radiotherapy in advanced nasopharyngeal carcinoma. *J Clin Oncol.* 2011;29(suppl):5543.
18. Jan B. Vermorken, Eva Remenar, Carla Van Herpen. Cisplatin, fluorouracil and docetaxal in unresectable head and neck cancer. *N Engl J Med.* 2007 October;357:1695-1704.

DOI: 10.5455/2320-6012.ijrms20140519

Cite this article as: Nikam BM, Singh KK, Kharde R, Nagshet S, Borade D, Moosa Z. The effect of induction chemotherapy followed by chemoradiotherapy in advanced head and neck cancer: a prospective study. *Int J Res Med Sci* 2014;2:476-80.