

Case Report

Primary systemic amyloidosis: a case report

Jayashankar CA^{1*}, D. S. Somasekar², Pavan Kumar Perugu³,
Santosh KV⁴, Manjunath Nandennavar⁵, Praveen Mathew⁶

¹Associate Professor, ²Professor and Head, ³Post graduate, Department of General Medicine, Vydehi Institute of Medical Sciences and Research Centre, Bangalore - 560066, Karnataka, India

⁴Professor, Department of Pathology, Vydehi Institute of Medical Sciences and Research Centre, Bangalore - 560066, Karnataka, India

⁵Assistant Professor, Department of Medical Oncology, Vydehi Institute of Medical Sciences and Research Centre, Bangalore - 560066, Karnataka, India

⁶Associate Professor, Department of Medical Gastroenterology, Vydehi Institute of Medical Sciences and Research Centre, Bangalore - 560066, Karnataka, India

Received: 6 January 2014

Accepted: 2 February 2014

***Correspondence:**

Dr. Jayashankar CA,

E-mail: drjayashankar.ca@gmail.com

© 2014 Jayashankar CA et al. This is an open-access article distributed under the terms of the Creative Commons Attribution Non-Commercial License, which permits unrestricted non-commercial use, distribution, and reproduction in any medium, provided the original work is properly cited.

ABSTRACT

Primary amyloidosis is a group of monoclonal plasma cell disorders, characterized by extracellular deposition of immunoglobulin light chain fibrils in multiple organs leading to progressive multiorgan dysfunction. It is a rare disease which usually occurs in elderly persons and has a poor prognosis. We report a 72-year-old male patient with chronic abdominal distension, bilateral pitting pedal edema with nephrotic range proteinuria and amyloid deposition in liver and bone marrow. Immunoelectrophoresis of serum demonstrated the presence of immunoglobulin light chains of the circulating monoclonal protein. He was treated with IV bortezomib and IV dexamethasone.

Keywords: AL Amyloidosis, Proteinuria, Hepatomegaly

INTRODUCTION

Amyloidosis is the term applied to a group of diseases characterised by extracellular deposition of fibrillar proteinaceous substance called amyloid having common morphological appearance, staining properties and physical structure but with variable biochemical composition.¹ Primary (AL type) amyloidosis is the most common form of systemic amyloidosis.¹ This is a rare disease with reported incidence of 12 cases/million population per year in Western countries.² Here we report one such case of primary systemic amyloidosis from our tertiary care centre.

CASE REPORT

A 65 year old male was admitted to our hospital with history of abdominal distension since 10 months and swelling of both legs since 8 months. Abdominal distension was insidious in onset, initially started in lower abdomen gradually became generalized with mild breathlessness on lying down in supine position. It was associated with generalized mild stretching type of abdominal pain.

Swelling of both legs was insidious in onset, started initially around ankle region, gradually progressed to level of middle 1/3rd of legs. There was no history of decreased urine output, puffiness of face or haematuria.

There was no history of breathlessness on exertion, chest pain, cough, asthenia, palpitations or syncope. He had no motor weakness and paraesthesia of distal parts of both lower and upper limbs. No history of vomiting, loose stools, constipation, dysphagia and jaundice. He denied dryness of eyes, mouth, swelling in anterior aspect of neck, joint pains, skin lesion around eyes, face and trunk. However he had loss of appetite and loss of weight of approximately 10 kgs since 10 months. Patient is not a known case of hypertension, diabetes mellitus or ischemic heart disease.

On general physical examination, patient was moderately built and poorly nourished, conscious oriented, pulse and oral temperature was normal. Blood pressure was 150/100 mm of Hg. There was mild pallor and bilateral pitting edema from ankle to mid 1/3rd of legs but no clubbing, cyanosis, lymphadenopathy or goitre. Examination of skin revealed no periorbital edema, purpura, petechiae or ecchymoses on the body. Examination of tongue revealed no obvious enlargement and no indentations. Jugular venous pressure was normal.

Abdominal examination revealed generalized non tender abdominal distension with fullness of flanks, moderate nontender hepatomegaly with shifting dullness.

Respiratory system examination revealed decrease in intensity of breath sounds in both infra-axillary areas.

Clinical examination of cardiovascular, nervous system and locomotor system was unremarkable.

Laboratory examination revealed Hb% of 10.4 gms%, normal total leucocyte count and platelet count. ESR (Erythrocyte sedimentation rate) was 120 mm in 1st hour. Peripheral blood smear showed normocytic, normochromic red blood cells. Rheumatoid arthritis (RA) factor was negative. Random blood glucose was 88mg/dl, blood urea 52.3 mg/dl (Normal: 16 to 40mg/dl), serum creatinine 2.37mg/dl (Normal: 0.4 to 1mg/dl) and serum potassium 4.5mEq/L (Normal: 3.5 to 5.1mEq/L). Serum sodium, chloride and calcium were normal.

Liver function test revealed: serum total bilirubin 0.7mg/dl (Normal : 0.3 to 1.2mg/dl), serum total protein 5.5grams/dl (Normal : 6.4 to 8.3gms/dl), serum albumin 2.0gms/dl (Normal: 3.4 to 4.8gms/dl), SGOT 67 IU/L (Normal :15 to 50IU/L), SGPT 48 (Normal :10 to 35IU/L), serum alkaline phosphatase 1135IU/L (Normal :56 to 153IU/L) and serum globulin 3.6grams/dl (Normal :1.8 to 3.6gms/dl).

Serum Alfa-fetoprotein was negative. HbsAg ELISA and anti-hepatitis C were negative. HIV ELISA was nonreactive.

Prothrombin time, activated partial thromboplastin time and INR (International normalized ratio) was normal.

Urine examination revealed proteinuria of 500mg/dl but no glycosuria or haematuria. Bence Jones protein in urine was negative. 24 hours urine protein was 4248mg/day (Normal: 50-80mg/day).

Chest X ray posterior anterior view revealed bilateral minimal pleural effusion.

Electrocardiogram revealed sinus rhythm with heart rate of 90/min. 2D Echocardiogram showed mild concentric left ventricular hypertrophy, grade 1 diastolic dysfunction and ejection fraction of 65%.

Ultrasonographic and MRI examination of abdomen and pelvis revealed: hepatomegaly (Right lobe 13cms and left lobe 7cms), normal biliary tract and moderate ascites with bilateral minimal pleural effusion.

In view of significant elevation of serum alkaline phosphatase, a possibility of infiltrative disease was considered and liver biopsy was done.

Liver biopsy showed lacy pattern of deposits of hyalinized material in a sinusoidal pattern separated by scattered atrophic hepatocytes suggestive of amyloidosis (Figure 1). Congo red stain (Figure 2) followed by polarizing microscopy depicted birefringence within hyaline deposits.

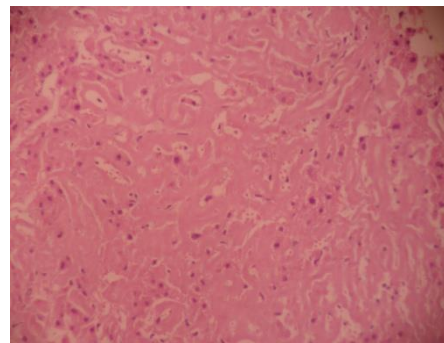


Figure 1: Amyloid deposits in liver: hyalinised areas with sinusoidal pattern, separated by hepatocytes. (H&E X100).

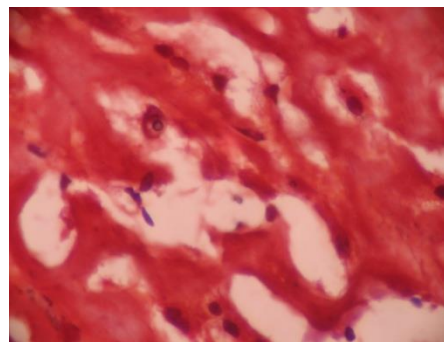


Figure 2: Amyloid deposits in liver: Congo red staining showing orange colour along the hyalinised areas. (Congo red stain X400).

Bone marrow biopsy also showed areas of Congo red positive hyalinized material; the marrow was otherwise within normal limits.

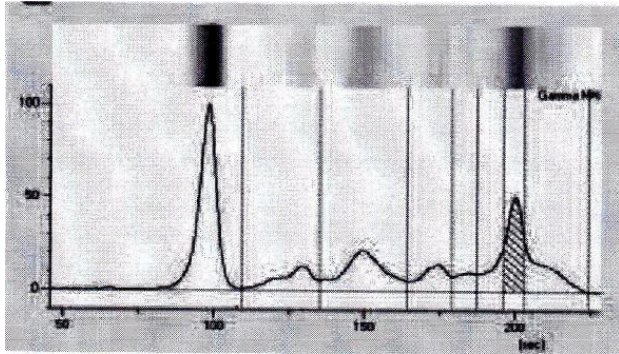


Figure 3: Serum protein electrophoresis: monoclonal gammopathy ("M" spike) seen in gamma region.

Serum protein electrophoresis revealed monoclonal spike (M spike) in Gamma region (Figure 3). Lateral X ray of skull was normal.

Immunohistochemistry done on liver biopsy tissue for kappa and lambda light chain showed that the deposits are positive for both (Figure 4).

A diagnosis of primary systemic amyloidosis with mild normocytic normochromic anaemia was made.

Patient was treated with oral frusemide 40mgs per day and IV antibiotics. Meanwhile the medical oncologist's opinion was sought and patient was started on subcutaneous injection of bortezomib 2mgs once a week. After a period of 2 months, patient showed significant symptomatic improvement in the form of reduction of abdominal distension due to ascites.

Oncquest Laboratories Ltd.			
3-Factory Road, New Delhi-29 Ph: 91-11-26101240			
			
Regd. Date	29/11/2013	Centre Details	Oncquest Laboratories Ltd- Bangalore
Name		Ref. By	Dr. Jaya shankar
Age	65 Yrs	Report Date:	06/12/2013 16:31:42
Sex	Male	Printed Date	27/12/2013
Reg. ID	241354719		
IMMUNOHISTOCHEMISTRY REPORT			
Any 2 IHC Markers			
Immunohistochemistry			
LAB. NO. : I/ 4723/13			
CLINICAL DETAILS :			
Case of amyloidosis			
SITE : Liver Bx			
SPECIMEN DETAILS :			
Received one paraffin block labeled as 3612/13 for IHC.			
MORPHOLOGY:			
Liver tissue submitted in one block labeled as 3612/13, morphologically shows homogenous perisinusoidal deposition resembling amyloid.			
IHC for kappa and lambda light chain show that the deposits are positive for both.			
No light chain restriction noted.			
This has been verified by repeat testing.			
-All controls show expected reactivity -Tests performed using Polymer detection system. -This is an opinion based on material and details provided, kindly correlate clinically to reach a confirmative diagnosis. -False negative/weak IHC results due to poor Antigen preservation in the material sent for evaluation cannot be excluded.			
*** End of Report ***			
 Dr. Seema Sachan MBBS, MD Pathology Consultant Pathologist			

Figure 4: Immunohistochemistry on liver biopsy tissue shows deposits are positive for kappa and lambda light chain.

DISCUSSION

Amyloidosis is divided clinicopathologically into 2 major categories. 1) Systemic (generalised) amyloidosis and 2) Localised amyloidosis. Systemic amyloidosis is further classified into a) Primary (AL) type, b) Secondary (AA), c) Haemodialysis-associated and d) Heredofamilial type. Localised amyloidosis is further classified into a) Senile cardiac, b) Senile cerebral c) Endocrine type d) Tumour forming (AL) type.¹

Primary amyloidosis which is the most common form of systemic amyloidosis is a plasma disorder that affects mostly the bone marrow, but usually is not associated with other diseases¹. However it may also occur in association with some form of plasma cell dyscrasia.¹ Virtually any organ can be affected in systemic primary (AL) amyloidosis except for central nervous system.

Secondary amyloidosis occurs in association with chronic inflammatory or infectious diseases, immunological disorders and neoplastic diseases. Hereditary or familial amyloidosis is rare and the only inherited form of the disease.²

Primary systemic amyloidosis affects men slightly more often than women. Primary systemic amyloidosis is a disease of elderly and the average age of patients at the time of diagnosis is 65 years and about 10% of patients are less than 50 years old.³

Primary systemic amyloidosis affects kidney, heart, liver, spleen, and gastrointestinal tract, peripheral nerves, carpal ligaments and skin. Kidney involvement is seen in 75% of patients, heart in 50%, macroglossia in 15%, hepatomegaly in 50%, splenomegaly in 10%, carpal tunnel syndrome in 25% of patients.^{3,4}

Since amyloidosis affects multiple organs it has highly varied clinical manifestations. Patients may present with fatigue, weight loss, early satiety, features of nephrotic syndrome such as generalised edema, congestive cardiac failure symptoms such as breathlessness, pedal edema secondary to restrictive cardiomyopathy, angina due to amyloid deposits in coronary arteries, giddiness on prolonged standing, impotency, diarrhoea or constipation due to autonomic neuropathy and dysphagia due to macroglossia.³

They may also present with signs of peripheral neuropathy, carpal tunnel syndrome hepatomegaly, hepatic failure, interstitial lung disease secondary to interstitial amyloid infiltration, joint pain due to progressive bilateral and symmetrical polyarthropathy involving fingers, wrists, shoulders, knees, sicca syndrome due to amyloid infiltration in exocrine glands, thyroid and adrenal deficiency due to amyloid infiltration in thyroid and adrenal gland respectively, easy bruising, ecchymosis and purpura due to vascular infiltration.³

The following four criteria must be met to diagnose a case of primary systemic amyloidosis (AL)⁵

- Presence of an amyloid-related systemic syndrome (such as renal, liver, heart, gastrointestinal tract or peripheral nerve involvement).
- Positive amyloid staining by Congo red in any tissue (e.g. fat aspirate, bone marrow or organ biopsy).
- Evidence that amyloid is light chain-related established by direct examination of the amyloid (immunohistochemical staining, direct sequencing, and so on) and
- Evidence of a monoclonal plasma cell proliferative disorder (serum or urine M protein, abnormal free light chain ratio or clonal plasma cells in the bone marrow).

Few authors^{6,7} have proposed a criteria to define organ involvement in AL Amyloidosis.

- Kidneys are involved if 24-hr urine protein is ≥ 0.5 g/day, presence of renal failure
- Heart if mean wall thickness in diastole by echocardiography is >12 mm with no other cardiac cause
- Liver if total liver span is >15 cm in the absence of heart failure, or alkaline phosphatase >1.5 times upper limit of normal level.

Our patient is an elderly man who presented with ascites and bilateral pitting pedal edema due to hypoalbuminemia secondary to nephrotic syndrome which in turn is probably due to amyloid deposits in kidneys. Our patient refused to undergo renal biopsy but few authors^{6,7} have suggested that in the absence of renal biopsy, a diagnosis of renal amyloidosis can be made on presence of histological evidence of amyloid deposits in other organs with proteinuria of >0.5 grams/day. In our patient there is evidence of amyloid deposits in liver and bone marrow. Further our patient has proteinuria of 4.248 grams/day. He had left ventricular hypertrophy with mean interventricular septal thickness of 1.2cm during diastole on echocardiographic examination.

Liver span in our patient is 13 cm but serum alkaline phosphatase is 1135 IU/L. Our patient did not have involvement of spleen, gastrointestinal tract, peripheral nerves, carpal ligaments and skin. All the four criteria mentioned above for diagnosing primary systemic amyloidosis are present in our patient.

Secondary amyloidosis, heredofamilial amyloidosis, Randall-type light chain deposition diseases were considered as differential diagnosis.³ There was no evidence of any etiology responsible for secondary amyloidosis and no family history of amyloidosis in our case. Randall-type light chain deposition disease is a systemic disease characterized by LC (light chain) deposition along basement membranes in most tissues

and microscopic haematuria is most commonly observed.³ Furthermore it is associated with multiple myeloma in 30 to 60% of cases.³ Our patient had no haematuria and there is no evidence of multiple myeloma.

Bortezomib with or without dexamethasone is reported to induce a rapid hematologic response and our patient is presently on bortezomib treatment and has symptomatically improved.

CONCLUSION

A 72 year old male presented with ascites, nephrotic range proteinuria, renal failure, amyloid deposits in liver and bone marrow, very high alkaline phosphatase, mild left ventricular hypertrophy and mild anaemia. Primary systemic amyloidosis should always be considered in any elderly patient who present with very high serum alkaline phosphatase, nephrotic range proteinuria with multiple organ involvement so that early institution of treatment will reduce the morbidity. Clinicians should be always aware of this clinical entity as it carries a poor prognosis.

Funding: No funding sources

Conflict of interest: None declared

Ethical approval: Not required

REFERENCES

1. Harsh Mohan. Immunopathology including amyloidosis. In: Praveen Mohan, Tanya Mohan, Sugandha Mohan, eds. Text Book of Pathology. 5th ed. New Delhi: Jaypee brothers; 2005: 83-92.
2. Khan MF, Falk RH. Amyloidosis. Postgrad Med J. 2001 Nov;77(913):686-93.
3. Estelle Desport, Frank Bridoux, Christophe Sirac, Sebastien Delbes, Sebastien Bender, Beatrice Fernandez et al. AL Amyloidosis. Orphan J Rare Dis. 2012 Aug;7:54.
4. Saoji V, Chaudhari S, Gohokar D. Primary systemic amyloidosis: three different presentations. Indian J Dermatol Venerol Leprol. 2009 Jul-Aug;75(4):394-7.
5. Rajkumar SV, Dispenzieri A, Kyle RA. Monoclonal gammopathy of undetermined significance, waldenstrom macroglobulinemia, AL amyloidosis, and related plasma cell disorders: diagnosis and treatment. Mayo Clin Proc. 2006;81:693-703.
6. Gertz MA, Comenzo R, Falk RH, Fermand JP, Hazenberg BP, Hawkins PN et al. Definition of organ involvement and treatment response in immunoglobulin light chain amyloidosis (AL): a consensus opinion from the 10th international symposium on amyloid and amyloidosis, tours, France, 18-22 April 2004. Am J Hematol. 2005;79:319-328.
7. Gertz MA, Merlini G. Definition of organ involvement and response to treatment in AL amyloidosis: an updated consensus opinion. Amyloid. 2010;17(Suppl 1):48-9.

DOI: 10.5455/2320-6012.ijrms20140571

Cite this article as: Jayashankar CA, Somasekar DS, Perugu PK, Santosh KV, Nandennavar M, Mathew P. Primary systemic amyloidosis: a case report. Int J Res Med Sci 2014;2:744-8.