

Original Research Article

Can Tc-99m labeled erythrocyte scintigraphy be an alternative non-invasive method to endometriosis diagnosis?

Fatih Demirel¹, Gokhan Koca², Koray Demirel², Huseyin Aydogmus¹, Aylin Akbulut²,
Murat Sadic^{2*}, Hasan Ikbal Atilgan², Meliha Korkmaz², Bulent Gokmen¹

¹Department of Obstetrics & Gynecology, Ministry of Health Ankara Training and Research Hospital, Ankara / Turkey

²Department of Nuclear Medicine, Ministry of Health Ankara Training and Research Hospital, Ankara / Turkey

Received: 05 December 2016

Accepted: 02 January 2017

*Correspondence:

Dr. Murat Sadic,

E-mail: mdmuratsadic@gmail.com

Copyright: © the author(s), publisher and licensee Medip Academy. This is an open-access article distributed under the terms of the Creative Commons Attribution Non-Commercial License, which permits unrestricted non-commercial use, distribution, and reproduction in any medium, provided the original work is properly cited.

ABSTRACT

Background: Endometriosis is defined as the implantation of endometrial gland and stroma ectopically outside the uterus. Clinically, it is a hormone dependent benign disease accompanied by pelvic pain and infertility. The aim of this study was to demonstrate the activated implants with 99m-Tc labeled erythrocyte scintigraphy (99mTc-RBCs) in patients with recurrent endometriosis and compare the results with pelvic MRI results.

Methods: Patients who were diagnosed histopathologically as endometriosis either with operation and / or therapeutic laparoscopy or laparotomy and, were included to present study. Thirty patients, who were diagnosed as recurrence by clinical, and laboratory terms and 10 healthy volunteer (control group) patients were included in the study. Between the second and fifth days of menstruation when the endometriotic lesions were highly activated, radionuclide imaging was performed by 99mTc-RBCs and compared with pelvic MRI findings.

Results: In 27 patients out of 30 patients (90%) pathological accumulation of radioactivity foci with 99mTc-RBCs were present. The focal pathological accumulation was significant in 26 patients and moderate in 1 patient. In 22 patients (81.5%) the increased radioactivity accumulation in radionuclide images was concordant with MRI images. Regarding the MRI as reference, the sensitivity of 99mTc-RBCs was determined as 96%, specificity 29%, positive predictive value 81% and negative predictive value was 66%.

Conclusions: Imaging of endometriosis regions with 99m-Tc-RBCs can be an alternative diagnostic procedure for the patients with recurrent endometriosis.

Keywords: Endometriosis, Magnetic resonance imaging, Tc-99m labeled erythrocyte scintigraphy

INTRODUCTION

Endometriosis is defined as the implantation of endometrial gland and stroma ectopically outside the uterus. Clinically, it is a hormone dependent benign disease accompanied by pelvic pain and infertility.¹⁻³

It can differ from little lesions to big endometriotic cysts causing distortion to normal anatomy and leading adhesions in pelvis. Moreover, it is an important

economic and social problem due to pelvic pain, dysmenorrhea and infertility. Inability to work, social isolation, and problems associated with infertility, and the high cost of diagnosis and treatment still render as an important problem throughout the world.¹⁻⁴

It affects approximately 176 million women of childbearing potential all over the world in 2010.⁵ The prevalence of endometriosis in women of childbearing age has been reported to be 10%.⁵

Definitive diagnosis of endometriosis can be achieved by the appearance of endometrial implants in laparoscopy or laparotomy and be concluded with the results of histopathological examination. However, recent approaches have led the idea that such methods may be unnecessarily challenging for the patient. Considering the perioperative risks and the economic burden of surgery, we believe that the new non-invasive methods should be developed, to obviate the need for laparoscopy and enable early diagnosis.

As a practical non-invasive method, our aim was to evaluate the endometrial implants with Tc-99m labeled erythrocyte scintigraphy (99mTc-RBCs) whether the active endometrial implants have radioactivity accumulation during menstruation period or not and also compare the results with pelvic magnetic resonance imaging (MRI) in patients suspected with recurrent endometriosis.

METHODS

The patients referred with complaints of dysmenorrhea, chronic pelvic pain, primary-secondary fertility and ovarian cystic mass that had diagnostic and/or therapeutic laparoscopy or laparotomy and diagnosed with endometriosis histopathologically were evaluated.

The study protocol was approved by the institutional review board of the Local Ethics Committee of our hospital and informed consent forms were obtained from all patients in the patient and control groups. Patient history, physical and pelvic examinations and routine biochemical tests were recorded. Serum CA-125 levels were measured at the time of referral to our hospital and at the day of scintigraphic imaging by chemoluminescence immunoassay method and the upper limit were considered as 35 U/ml. All patients had their MRI scan. Thirty patients with clinical recurrence were included as the patient group, following the necessary consultations and the ruling out of pregnancy, lactation and systemic diseases. Control group consisted of 10 asymptomatic healthy volunteers.

Both the patients and the control group underwent 99mTc-RBCs between the 2nd and the 5th days of menstruation when endometrial lesions were active. In the in-vivo method of 99mTc-RBCs the intravenous administration of Sn medronate kit prepared with 3cc serum physiological (Amerscan™) following an incubation period of 30 minutes, erythrocytes were labeled with tin.

Patient in supine position under the gamma camera, using a low energy all-purpose collimator, a simultaneous 20-minute imaging started after the administration of Tc-99m, scanning the anterior pelvic region. The images of erythrocytes labeled with in-vivo technique were scanned using Siemens E. cam (Siemens Medical Solutions, Hoffman Estates, IL - USA) single detector gamma

camera device. Perfusion images of 1 second each were taken at 64x64 matrixes with 1.23 zoom for 60 frames. Then, in the blood pool phase, a further 19 images, 1 minute each, were acquired, completing the dynamic study in a total of 20 minutes. In anterior and lateral positions, 2-minute static images were recorded at 128x128 matrixes and early SPECT (single photon emission computerised tomography) procedure was initiated. SPECT images were acquired at 128x128 matrixes with 1.45 zoom factor at 32 steps of 30 seconds each, using shoot mode. Two hours later static images of the patients were taken in anterior and lateral positions. Cases with a full bladder passed urine and all patients had their late SPECT imaging.

Two experienced nuclear medicine physicians interpreted the images. The healthy control group was evaluated primarily for the determination of normal physiological uptake areas in the female genitourinary system such as physiological uterus activity, activity accumulation in the urinary bladder and ureter, and major vascular structures. After that the patient group was evaluated randomly without any knowledge of which case is in which group. Beside the normal physiological uptake, the abnormal uptake patterns of 99mTc-RBCs in the pelvis and in the extrapelvic structures were documented. Positive interpretation criteria for active endometriosis implants were the visually increased radioactivity accumulation areas of radioactivity labeled erythrocytes, compared to the control group and afterwards these areas were compared with pelvic MRI.

Sample size estimation

We evaluated the differences in the prevalence of labeled erythrocyte scintigraphy involvement between case and control groups. A total sample size of 40 (30 for case group and 10 for control group owing to the allocation ratio was accepted as 3.0) was required to detect at least 65% difference between the groups with a power of 90% at the 5% significance level. The difference of 65% was taken from our clinical experience. Sample size estimation was performed using NCSS and PASS 2000 (NCSS LLC., Kaysville, Utah, USA) software.

Statistical analysis

Data analysis was performed by using SPSS for Windows, version 16.0 (SPSS Inc., Chicago, IL, United States). Shapiro Wilk test was used to determine whether the distributions of continuous data were normal or not. The mean age differences between groups were analyzed by using Student's t test, and Mann Whitney U test was applied for the comparisons of CA-125 levels. Nominal data were analyzed by Fisher's exact or Marginal Homogeneity test, where appropriate. Degree of association between MRI and scintigraphy findings in terms of location was calculated by coefficient of Phi. A p value less than 0.05, was considered statistically significant.

RESULTS

We have included 30 patients and 10 controls and their ages, symptoms, serum CA-125 levels at the time of referral are given in Table 1. In terms of age, the patient

and control groups' age were not significantly different ($p=0.086$). Dysmenorrhea was present at 90% of the patient group while in the control group the rate of dysmenorrhea was 30% ($p=0.001$).

Table 1: Characteristics of patients and controls.

Age (mean±sd) (years)	Patient	Control	p-value
	33.00±8.09	28.10±5.86	0.086
Age (min-max)	21-50	19-36	
Dysmenorrhea			
Present	27 (90%)	3 (30%)	< 0.001
Absent	3 (10%)	7 (70%)	
Dyspareunia			
Present	15 (50%)	2 (20%)	0.145
Absent	15 (50%)	8 (80%)	
Cyclic dysuria			
Present	1 (3.3%)	0 (0%)	1.000
Absent	29 (96.7%)	10 (100%)	
Chronic pelvic pain			
Present	17 (56.7%)	1 (10%)	0.01
Absent	13 (43.3%)	9 (20%)	
Serum CA-125 (mean±sd)			
>35 U/ml	16 (53.3%)	0 (0%)	0.003
<35 U/ml	14 (46.7%)	10 (100%)	

The rate of dyspareunia was 50%, 20% ($p=0.145$), chronic pelvic pain was present at 56.7% and 10% ($p=0.01$) respectively in the patient and the control groups. Cyclic dysuria was an existing complaint 3.3% in the patient group however there was no patient with cyclic dysuria in the control group ($p=1.00$). In the patient group dysmenorrhea was severe in 43.3%, moderate in 23.3% and mild in 26.7% of patients. Dyspareunia was severe in 13.7% of patients, moderate in 16.7% and mild in 20% (Figure 1).

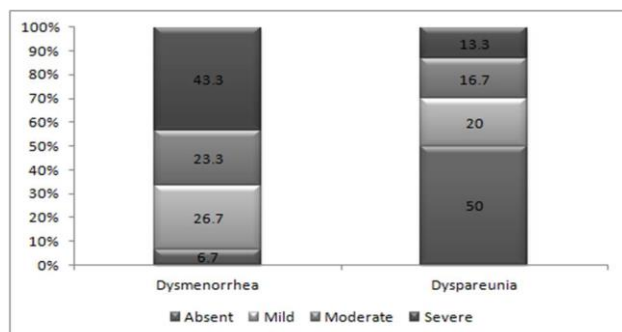


Figure 1: Presence and severity of dysmenorrhea and dyspareunia in patient group.

In the patient group, serum CA-125 level was above normal in 16 patients, whilst in the control group in all

patients CA-125 levels were below 35 U/ml. The patient groups' serum CA-125 level mean was 44.04 ± 35.95 U/ml while the control groups' was 17.89 ± 6.30 U/ml. The difference was statistically significant between the groups ($p=0.001$).

Table 2: Endometriosis localization in pelvic MRI and abnormal localization of activity accumulation in scintigraphy in patient group.

	Endometriosis localization in pelvic MRI	Localization of abnormal activity accumulation
Negative	7 (23.3%)	3 (10%)
Only ovarian	18 (60%)	19 (63.4%)
Only extraovarian	1 (3.3%)	2 (6.6%)
Combine *	4 (13.3%)	6 (20%)
Total	30 (100%)	30 (100%)

* Ovarian+Extraovarian, Distribution of localization with MRI and Scintigraphy were statistically similar according to Marginal Homogeneity Test ($p=0.41$).

MRI was positive in 23 patients (76.7%) and negative in 7 patients (23.3%) in the patient group. The MRI location of endometriosis areas in the patient group, were only ovarian in 18 patients (60%), only extraovarian in 1 patient (3.3%) and in 4 patients (13.3%) endometriosis

areas were both ovarian and extraovarian (Table 2). The extraovarian areas in 5 patients were; peritoneum in 2 patients, Douglas pouch in 2 patients and rectum in 1 patient. All patients in the control group were MRI negative (p=0.001). The size of endometrioma and implant areas was 5-10 mm in 1 patient, 10-20 mm in 5 patients, 20-30 mm in 9 patients and ≥30 mm in 8 patients.

99m-Tc-RBCs was positive in 27 patients (90%) and negative in 3 patients (10%) in the patient group. The 99m-Tc-RBCs location of endometriosis areas in the patient group, were only ovarian in 19 patients (63.4%), only extraovarian area in 2 patients (6.6%), both ovarian and extraovarian areas in 6 patients (20%) (Table 2).

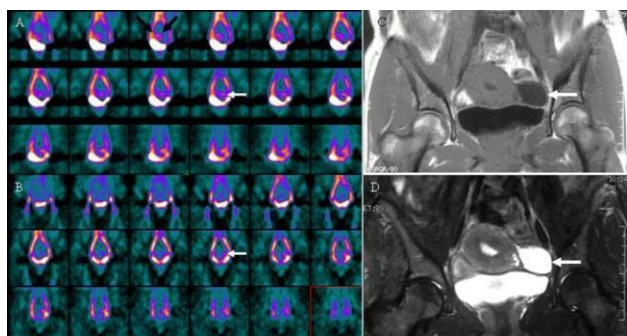


Figure 2: 36-year old woman with endometrioma of the left ovary. In the early images (A) of 99m-Tc red blood cell scintigraphy (99m-Tc-RBCs) showing physiological uptake of the uterus (upper arrow). 99m-Tc-RBCs delayed (B) coronal SPECT images showing increased radioactivity accumulation in the region of left ovarium (below arrow). T1-weighted (C), T2-weighted (D) coronal pelvic MRI images showing endometrioma in the left ovarium region.

The extraovarian involvement areas were; peritoneum in 3 patients, uterus in 3 patients, Douglas pouch in 1 patient and rectum in 1 patient with 99mTc-RBCs. 99m-Tc-RBCs findings were completely negative for the control

group (Figure 2, 3). The normal physiological activity at the uterus during menstruation was positive in 26 cases from the patient group (86.7%) and in 7 cases (70%) in the control group (p=0.24).

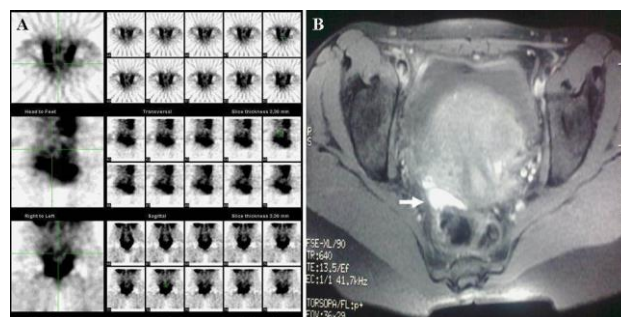


Figure 3: 35-year old woman with endometriosis on the anterior wall of the rectum. 99m-Tc-RBCs SPECT images (A) showing increased radioactivity accumulation in the anterior of the rectum. T2-weighted coronal MR image (B) showing endometrial implants on the anterior wall of the rectum (white arrow).

In present patient group the MRI findings were positive in 76.7% (23/30) of the patients, while in the control group no such findings were observed (p=0.009). In the present study, 99m-Tc-RBCs reported pathological radioactivity accumulation in 27/30 (90%) patients versus 3/30 (10%) negative in patients (p≤0.001). There was no significant difference between MRI and 99m-Tc-RBCs findings in terms of location and size of endometriosis lesions (p>0.05). Regarding the determination of positive findings consistent with endometriosis, there was a close correlation between MRI (76.7% positive in MRI) and 99m-Tc-RBCs (90% positive in 99mTc-RBCs) and this was statistically significant (phi=0.651 and p=0.001). Regarding the MRI as reference, the sensitivity of 99m-Tc-RBCs was determined as 96%, specificity 29%, positive predictive value 81% and negative predictive value was 66%. The descriptive statistics were shown in Table 3.

Table 3: Regarding the MRI as reference.

	MRI Positive	MRI Negative	Total
Scintigraphy Positive	22	5	27 (90%)
Scintigraphy Negative	1	2	3 (10%)
Total	23 (76.7%)	7 (23.3%)	30 (100%)

The sensitivity of TLES was determined as 22/23=96%, Specificity 2/7=29%, Positive Predictive Value 22/27=81%, Negative Predictive Value 2/3=66%.

DISCUSSION

Endometriosis is defined as the presence of endometrial gland and stroma outside the uterine cavity. It may vary

from microscopic endometriotic implants to large cysts (endometriomas). The facts about the definitive diagnosis from the histological appearance of ectopic endometrial gland and stroma, is bringing the high costs, perioperative

risks associated with the procedure, and the need for a fully equipped hospital. In addition, laparoscopy can be limited by the presence of dense pelvic adhesions, resulting in limited access to the Douglas pouch and adnexa. Therefore, there is an urgent need for non-invasive techniques, which will make early diagnosis possible. As non-invasive diagnostic methods are developed in the future, the need for laparoscopy will decrease. At present, the method of 'see the lesions surgically and diagnose histopathologically' is becoming increasingly impractical with many clinicians going from treatment to diagnosis.⁶

Regarding many conventional methods in the diagnosis of endometriosis like X-Ray, computed tomography and barium studies the appearance of implants and endometriomas is commonly non-specific. Ultrasound (US), which is one of the most frequently used non-invasive diagnostic method at present, theoretically might have been quite successful in the diagnosis of patients with endometriosis. Endometriomas typically contain internal echoes at diffuse low amplitude, and surrounded by an echogenic capsule. It has been proven that sonographic reflections, typical of endometrioma, represent erythrocyte degradation products.⁷ Nevertheless, ultrasonography is inadequate in showing pelvic adhesions, superficial lesions, large implants, peritoneal implants and extrapelvic foci.⁸

Magnetic resonance imaging (MRI) is another non-invasive method in diagnosis. The characteristic appearances of endometriomas on MRI are hyperintense areas with homogenous shadowing on T1-weighted images and relatively hypointense areas in T2-weighted images. The intensity of signals correlates with the amount of intracellular methemoglobin, which has a complex appearance related to blood clots and cellular debris.³

Even though cystic masses are successfully visualised in MRI, sensitivity is low for small implants superficial lesions and adhesions. In the detection of endometrial implants with MRI, sensitivity is 77% and specificity 78%. However, in the detection of endometriomas with MRI, the results are satisfactory with a sensitivity of 90-92%, and specificity of 91-98%.⁹ Although both US and MRI have low sensitivity in demonstrating implants and adhesions in the diagnosis of peritoneal endometriosis, they are practical for the diagnosis of ovarian endometriomas larger than 20 mm.¹⁰

Although there is currently no biochemical serum parameter with high sensitivity and specificity for the diagnosis of endometriosis, in women with advanced stage endometriosis, CA-125 levels are frequently increased.^{11,12} However, increased levels can also be present in early pregnancy, during normal menstruation, in acute pelvic inflammatory disease and in conditions such as leiomyoma. The sensitivity is too low to be used as an efficient screening tool for the diagnosis of

endometriosis, although the specificity is over 80%. However, when serum CA-125 levels are combined with US, it may help to differentiate ovarian origin endometriomas from other benign ovarian cysts.¹³ High CA-125 levels persisting in the postoperative period may predict a relatively unfavorable prognosis, but generally levels do not give an idea on the efficacy of the medical treatment.¹⁴

^{99m}Tc-RBCs is most commonly used in the determination of the bleeding focus in lower gastrointestinal tract bleeding, in the differential diagnosis of liver hemangioma and in cardiac multigated acquisition (MUGA). It is less commonly used for the investigation of spleen/accessory spleen, measurement of total erythrocyte volume; diagnosis of vascular malformations, gastrointestinal/cerebral and other hemorrhages, postoperative bleeding, deep vein thrombosis, tumor associated bleeding, and low flow bleeding which cannot be demonstrated by angiography.¹⁵⁻¹⁷ There has been only some case reports showing endometrioma with ^{99m}Tc-RBCs; Cerci et al¹⁸ presented a case of extrapelvic endometrial implant located at the anterior abdominal wall, in the rectus sheath as increased radioactivity area concordant with endometriosis.

Also in an experimental study by Hascalik et al, visualised endometrial implants with ^{99m}Tc-RBCs.¹⁹ After the experimental implantation of endometrial implants in 21 mice with greater than 2 mm in size, 15 mice underwent ^{99m}Tc-RBCs and 6 underwent radioactive Iodine -131 labeled Tamoxifen (I131-Tx) scintigraphy. In 11 of 15 mice with ^{99m}Tc-RBCs (73, 3%) has shown a significant focal increase of radioactivity accumulation observed in the peritoneal area on the side where the implants were present compared to the other side. In the histopathological examination of the implants with radioactive accumulation, hemosiderin-laden macrophages were observed, and a correlation was found between the quality of the scintigraphic images and the size of the implant and its vascularisation. In mice with negative ^{99m}Tc-RBCs, small implants with weakly vascularised adhesions were observed.

Other than ^{99m}Tc-RBCs, there has been few scintigraphic case studies in endometriosis, with I131-Tx scintigraphy, radioactively labeled Anti-CA 125 antibodies and Tc-99 labeled glutamate peptide-estradiol, I131 and also few PET case studies.¹⁹⁻²⁶

For instance from the same study of Hascalik et al above, in 6 mice underwent I131-Tx scintigraphy, however radioactivity accumulation on the side of the implant in the peritoneal area was found to be weaker than in those undergoing scintigraphy with ^{99m}Tc-RBCs.¹⁹ With ^{99m}Tc-RBCs, on the side of the implant, significantly higher focal hyperactivity was observed than in the controls and activity rates were found to be higher in comparison with I131-Tx (p<0.05).

In 2 cases of endometriosis with normal serum CA-125 levels, scintigraphic imaging with radioactively labeled Anti-CA 125 antibodies demonstrated ovarian endometrioma and periovarian implants in a hysterectomised 45-year old female and a 29 years old female with primarily infertility. In another study by Kennedy et al with 28 patients with infertility and/or endometriosis, underwent pre-op immunoscintigraphy with radiolabeled monoclonal antibody in 22 patients results were positive, 16 of whom were diagnosed as post-op endometriosis and of the remaining 6 patients, 3 were found to have pelvic adhesions, 2 had normal pelvic anatomy and 1 had pelvic inflammatory disease.²¹ These findings indicated that immunoscintigraphic examination was 89% sensitive and 33% specific in the diagnosis of endometriosis.

Another study has shown in-vitro uptake of 99m-Tc labeled glutamate peptide-estradiol is via estrogen receptor mediated. They have shown of 99m-Tc labeled glutamate peptide-estradiol accumulation in microinvasive endometrial tissue and this uptake can be blocked by tamoxifen, which could be an idea for radionuclide therapy.²²

There are few case reports presenting endometriosis lesion with F-18 Fluorodeoxyglucose Positron emission tomography (FDG-PET). However in some PET cases endometriosis areas was observed as a hypometabolic area and in some cases, they were observed as hypermetabolic areas attributed to activated macrophages and inflammatory cells.²³⁻²⁶ Therefore, further comprehensive studies are required with PET regarding the possibility of false positive results of endometriomas when searching for malignant masses, as its common clinical use.²⁷

Unlike the above cases, in a study by Fastrez et al the use of F-18 FDG PET-CT was not recommended in the diagnosis of endometriosis.²⁸ In an FDG-PET/CT investigation of 10 patients, endometriosis was found in 9 but F-18 FDG detected none of the cases. On the other hand, in a case report with elevated CA-125 levels FDG-PET revealed endometrioma in the left ovary and also in liver as increased accumulation in PET which was demonstrated as endometrioma in laparotomy, 3 months after surgery and GnRH analogue usage the liver lesion regressed both in MRI and in FDG-PET.²⁶ We believe this case is a good example of concordant results of imaging and surgery.

Evaluating the results of the limited number of studies on the scintigraphic imaging of endometriosis; to the best of our knowledge, the immunoscintigraphic studies by Kennedy et al are anecdotal studies and there are no comprehensive or experimental animal studies on endometriosis.^{20,21} The non-invasive diagnostics of endometriosis radionuclide imaging techniques have several advantages such as supplying information on function and metabolism, opportunity to screen the whole

body without extra radiation dose in a short period for extrapelvic endometriosis and also minimising the need for surgical intervention by clarifying the localisations of recurrent active implants. In present study, regarding the case reports and experimental studies in the literature 99m-Tc-RBCs was preferred because of its low radiation dose, low cost and easy accessiblens. Regarding these factors we believe that 99m-Tc-RBCs is a promising technique.

However in 99m-Tc-RBCs false positive results can be present in several conditions such as bleeding ovarian cysts, and intrapelvic bleeding. Nonetheless in such pathologies the bleeding is absorbed in time with a significant change in early and late scintigraphic appearance, whereas in endometriomas, the scintigraphic appearance will be constant in both early and late images. In our study, early and late 99m-Tc-RBCs images were compared to exclude intrapelvic hemorrhagia reasons and we had no such findings suggesting intrapelvic hemorrhagia in any patients.

Another limitation of 99m-Tc-RBCs evaluation is the location of the endometriosis areas. Endometriosis areas might be false negative with 99m-Tc-RBCs in areas with normal physiological radioactivity in images such as bladder, uterus and large vascular structures. In such conditions contrast resolution may be increased by the addition of SPECT, which will contribute to the visualisation of the endometriosis areas.

Present study in endometriosis patients with clinical recurrence, endometriosis areas detected with MRI were congruent with 99m-Tc-RBCs supporting the results of Cerci et al, Hascalik et al and Takahashi et al in the literature.^{18,19,22} The main limitation of present study is the lack of present histopathologic confirmation. Nevertheless present leading purpose on this study was to decrease the invasive procedures and to compare them with the non-invasive techniques that we rely on. A very recent review evaluating MRI, US and CT as most studied modalities and also F-18 FDG PET-CT for non-invasive imaging methods in endometriosis concluded that none of those modalities have enough accuracy that may suggest replacing surgery letting us to think about the future developments.²⁹

Newly a new 99m-Tc labeled Monoclonal Antibody Anti-VEGF has released and evaluated in rat endometriosis lesions. In addition there are experimental studies investing new non-invasive imaging methods like in vivo imaging of the fluorescent human endometriosis lesions in nude mouse models, however further studies are needed.^{30,31} In the present study, pathological radioactivity accumulation was observed in 99m-Tc-RBCs in 27/30 (90%) patients ($p \leq 0.001$). In the pelvic MRI of the endometriosis group for whom recurrence was considered clinically, findings compatible with recurrence were found in 76.7% (23/30) of the patients, while in the control group no such findings were

observed ($p=0.009$). Regarding the MRI as reference, the sensitivity of 99m-Tc-RBCs was determined as 96%, specificity 29%, positive predictive value 81% and negative predictive value was 66%. In the future, the development of radiopharmaceuticals with higher specificity for endometrial tissue, would definitely improve both the diagnosis and possibly the treatment options.³⁰

CONCLUSION

As far as we know, this is the first prospective study in literature carried out with 99m-Tc-RBCs on endometriosis cases. Our study with recurrent endometriosis cases, we have shown the pathological activity accumulation with 99m-Tc-RBCs in endometriosis areas as detected by MRI. 99mTc-RBCs, as a non-invasive imaging method, may therefore contribute to the evaluation of endometriosis cases.

Funding: No funding sources

Conflict of interest: None declared

Ethical approval: The study was approved by the Institutional Ethics Committee

REFERENCES

- Falcone T, Lebovic DI. Clinical management of endometriosis. *Obstet Gynecol.* 2011;118:691-705.
- Darrow SL, Vena JE, Batt RE, Zielesny MA, Michalek AM, Selman S. Menstrual cycle characteristics and the risk of endometriosis. *Epidemiology.* 2013;4:135-42.
- Taylor RN. Endometriosis. In: Barbieri RL, Strauss JF, eds. Yen and Jaffe's Reproductive Endocrinology. 5th ed. Philadelphia, PA: Elsevier/Saunders. 2004:691-711.
- Garry R, Clayton R, Hawe J. The effect of endometriosis and its radical laparoscopic excision on quality of life indicators. *Br J Obstet Gynaecol.* 2009;107:44-54.
- Giudice LC. Clinical practice. Endometriosis. *N Engl J Med.* 2010;362:2389-98.
- Ling F. Randomized controlled trial of depot leuprolide in patients with chronic pelvic pain and clinically suspected endometriosis. *Pelvic Pain Study Group. Obstet Gynecol.* 1999;93:51-8.
- Moore J, Copley S, Morris J, Lindsell D, Golding S, Kennedy S. A systematic review of the accuracy of ultrasound in the diagnosis of endometriosis. *Ultrasound Obstet Gynecol.* 2002;20:630-4.
- Patel MD, Feldstein VA, Chen DC, Lipson SD, Filly RA. Endometriomas: diagnostic performance of US. *Radiology.* 1999;210:739-45.
- Sugimura K, Okizuka H, Imaoka I, Kaji Y, Takahashi K, Kitao M, et al. Pelvic endometriosis: detection and diagnosis with chemical shift MR imaging. *Radiology.* 1993;188:435-8.
- Moore J, Copley S, Morris J, Lindsell D, Golding S, Kennedy S. A systematic review of the accuracy of ultrasound in the diagnosis of endometriosis. *Ultrasound Obstet Gynecol.* 2002;20:630-4.
- Barbieri RL, Niloff JM, Bast Jr RC, Schaetzi E, Kistner RW, Knapp RC. Elevated serum concentrations of CA-125 in patients with advanced endometriosis. *Fertil Steril.* 1986;45:630-4.
- Pittaway DE, Fayez JA. The use of CA-125 in the diagnosis and management of endometriosis. *Fertil Steril.* 1986;46:790-5.
- Van Calster B, Timmerman D, Bourne T, Testa AC, Van Holsbeke C, Domali E, et al. Discrimination between benign and malignant adnexal masses by specialist ultrasound examination versus serum CA-125. *J Natl Cancer Inst.* 2007;99:1706-14.
- Chen FP, Soong YK, Lee N, Lo SK. The use of serum CA-125 as a marker for endometriosis in patients with dysmenorrhea for monitoring therapy and for recurrence of endometriosis. *Acta Obstet Gynecol Scand.* 1998;77:665-70.
- Smith R, Copely DJ, Bolen FH. 99mTc-RBC scintigraphy: correlation of gastrointestinal bleeding rates with scintigraphic findings. *AJR Am J Roentgenol.* 1987;148:869-74.
- Howarth DM. The role of nuclear medicine in the detection of acute gastrointestinal bleeding. *Semin Nucl Med.* 2006;36:133-46.
- Sinzinger H, Rodrigues M. Chapter 8; Cellular labeling with Tc-99m chelates: Relevance of In vivo and In vitro viability testing. In: Zolle I, eds. Technetium-99m Pharmaceuticals: Preparation and Quality Control in Nuclear Medicine. 2nd ed. Berlin, Germany: Springer Berlin Heidelberg. 2007:103-7.
- Cerci S, Cerci C, Balci T, Komek H, Kılınç N. Abdominal wall endometriosis imaged with scintigraphy: report of a case. *SDÜ Tıp Fak Derg.* 2005;12:57-60.
- Hascalik S, Celik O, Kekilli E, Elter K, Karakas HM, Aydin NE. Novel noninvasive detection method for endometriosis: research and development of scintigraphic survey on endometrial implants in rats. *Fertility and Sterility.* 2008;90:209-13.
- Kennedy SH, Soper NDW, Mojiminiyi OA, Shepstone BJ, Barlow DH. Immunoscintigraphy of ovarian endometriosis. A preliminary study. *Br J Obstet Gynaecol.* 1988;95:693-7.
- Kennedy SH, Mojiminiyi OA, Soper NDW, Shepstone BJ, Barlow DH. Immunoscintigraphy of endometriosis. *Br J Obstet Gynaecol.* 1990;97:667-70.
- Takahashi N, Yang DJ, Kurihara H, Borne A, Kohanim S, Oh CS, et al. Functional imaging of estrogen receptors with radiolabeled-GAP-EDL in rabbit endometriosis model. *Acad Radiol.* 2007;14:1050-7.
- Chuang, Tzyy-Ling, Chun-Shuo Hsu, Yuh-Feng Wang. 131I SPECT/CT Demonstrated Ovarian Endometrioma. *Clin Nuc Med.* 2014;39:193-5.

24. Lin JH, Kok VC, Su JC. FDG-PET findings in an ovarian endometrioma, A case report. *Ann Nucl Med Sci.* 2008;21:109-13.
25. Derman AY, Sperling D, Merav A, Jain VR, Levin M, Jana S, et al. Endometrioma presenting as a cavitary lung mass with FDG uptake on PET-CT. *J Thorac Imaging.* 2007;22:172-5.
26. Jeffrey L, Kerrou K, Camatte S, Metzger U, Lelièvre L, Talbot JN, et al. Endometriosis with FDG uptake on PET. *Eur J Obstet Gynecol Reprod Biol.* 2004;117:236-9.
27. Ge J, Zuo C, Guan Y, Zhang X. Increased 18F-FDG uptake of widespread endometriosis mimicking ovarian malignancy. *Clin Nuc Med.* 2015;40:186-8.
28. Fastrez M, Nogarède C, Tondeur M, Sirtaine N, Rozenberg S. Evaluation of 18 FDG PET-CT in the diagnosis of endometriosis: a prospective study. *Reprod Sci.* 2011;8:540-4.
29. Nisenblat V, Bossuyt PM, Farquhar C, Johnson N, Hull ML. Imaging modalities for the non-invasive diagnosis of endometriosis. *Cochrane Database Syst Rev.* 2016;2:CD009591.
30. Machado DE, Perini JA, Orlando MM, Santos-Oliveira R. Developing a Noninvasive Procedure Using Labeled Monoclonal Antibody Anti-VEGF (Bevacizumab) for Detection of Endometriosis. *Biomed Res Int.* 2015;2015:751460.
31. Wang N, Hong S, Tan J, Ke P, Liang L, Fei H, et al. A red fluorescent nude mouse model of human endometriosis: advantages of a non-invasive imaging method. *Eur J Obstet Gynecol Reprod Biol* 2014;176:25-30.

Cite this article as: Demirel F, Koca G, Demirel K, Aydogmus H, Akbulut A, Sadic M et al. Can Tc-99m labeled erythrocyte scintigraphy be an alternative non-invasive method to endometriosis diagnosis? *Int J Res Med Sci* 2017;5:588-95.