

## Case Report

# Diffuse steatonecrosis - presenting as an obscure abdominal mass - a diagnostic dilemma

Binay Kumar<sup>1\*</sup>, Upasna Chachra<sup>1</sup>, Bhuvan<sup>2</sup>

<sup>1</sup>Department of Pathology, Government Medical College, Haldwani, Nainital, Uttarakhand, India

<sup>2</sup>Department of General Surgery, Government Medical College, Haldwani, Nainital, Uttarakhand, India

**Received:** 26 November 2016

**Revised:** 23 December 2016

**Accepted:** 23 December 2016

### \*Correspondence:

Dr. Binay Kumar,

E-mail: binaypgi@gmail.com

**Copyright:** © the author(s), publisher and licensee Medip Academy. This is an open-access article distributed under the terms of the Creative Commons Attribution Non-Commercial License, which permits unrestricted non-commercial use, distribution, and reproduction in any medium, provided the original work is properly cited.

### ABSTRACT

Diffuse steatonecrosis secondary to acute / gangrenous pancreatitis presenting as vague abdominal mass is difficult to diagnose and requires special method / techniques for demonstration of fatty acid crystalloids. We report a case of acute abdomen with palpable lump. On emergency exploratory laprotomy a large thick jumbled up omental mass was revealed adhered to parietal wall along with complete pancreatic necrosis. Biopsy show diffuse fat necrosis of pericolic fat, omentum / mesentery with involvement of gut submucosa and birefringent saponified fatty acid crystalloids were demonstrated. Steatonecrosis may cause diagnostic dilemma and should be considered as differential diagnosis in appropriate clinical setting.

**Keywords:** Pancreas, Steatonecrosis, Submucosa, Xanthogranulomatous reaction

### INTRODUCTION

Fat necrosis has been reported in the mesenteric, pericolic fat, gut serosa and distant sites like subcutaneous fat, fatty marrow.<sup>1</sup> Pancreatic steatonecrosis presenting as abdominal mass may cause diagnostic problems. Saponified free fatty acid crystalloids are formed which appear birefringent under polarized microscopy in unstained sections mounted by Canada balsam.

These crystalloids were seen in some of the foci of fat necrosis in Hematoxylin & Eosin stain, although difficult to demonstrate in every case of steatonecrosis due to prolonged exposure (more than 15 minutes) of tissue to 70% alcohol during rehydration step of H&E stain. The use of Ehrlich's Hematoxylin which contains fairly large amount of alcohol causes destruction of fatty acid crystalloids. Internet search and review of literatures revealed only a few cases reported up till now in which

crystalloids were seen. Our case is an unique in the sense that patient is a pregnant woman presented with acute abdominal lump having per-operative clinical suspicion of malignancy and it is second one in which submucosa is involved. Further xanthogranulomatous reaction associated with complete pancreatic necrosis is also seen.

### CASE REPORT

A 22 year old pregnant female was admitted in the emergency ward with complains of acute abdominal pain and lump abdomen umbilical region since 15 days. On palpation, abdomen was soft, non-tender with a large irregular lump felt in the para-umbilical region.

Investigations done in emergency were hemoglobin 6.1 gm%, Total leukocyte count- 4600 / cu mm, random blood sugar 98 mg/dl, total protein 5.5 gm/dl. Ultrasound abdomen revealed 7 weeks gestation sac in uterus along

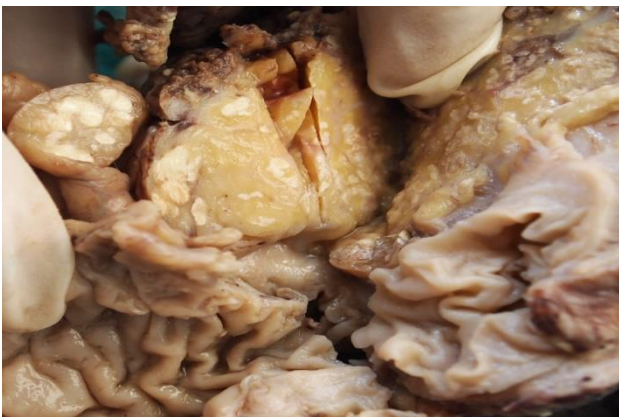
with calculus cholecystitis and a large anterior abdominal wall parietal mass measuring approximately 11 cms in greatest dimension with mixed echogenicity, internal irregular sonolucent echogenic area suggestive of abscess/ hematoma. Pancreatic pathology was not suspected in ultrasound. Emergency exploratory laprotomy was done with resection and anastomosis of mid-transverse colon along with cholecystectomy. Dilatation and curettage was also performed.

Intra-operatively a large thick omental mass adhered with parietal wall was found along with dense necrosis extending from right two third to part of left one third of transverse colon. Necrotic material in pancreatic region was adhered to duodenum, descending colon and undersurface of liver. Pancreas was completely necrosed. Gall bladder and resected bowel were sent for histopathological examination.

Diagnosis was unclear during surgery, differential diagnosis of carcinoma colon and primary colonic gangrene was made. Peritoneal fluid was also sent for malignant cytology which came out to be negative. Post-operative amylase and lipase were only marginally raised.

#### **Histopathological examination**

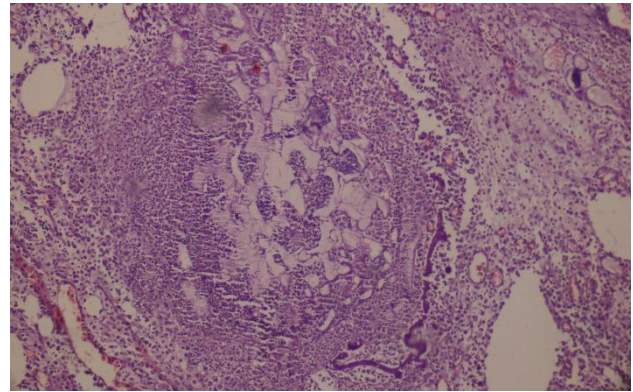
Grossing revealed thickened bowel wall and hypertrophied appendices epiploicae. On cut, thickened bowel wall, area of adhesions, subserosal fat and appendices epiploicae showed small, multiple, chalky white nodules (Figure 1).



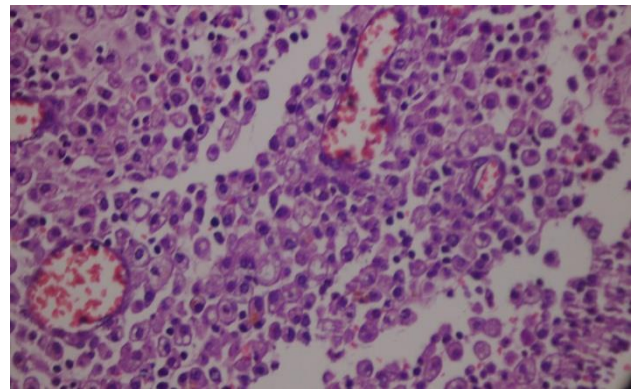
**Figure 1: Gross specimen showing opened up colonic segment with chalky white fat necrosis in pericolic fat (appendices apopliacae).**

Microscopy: Multiple sections taken from the thickened bowel wall, areas of adhesions and appendices epiploicae studied revealed multiple, circumscribed blotches of fat necrosis (Figure 2). Sections from both colonic and small bowel segments show numerous xanthoma cells with occasional multinucleate giant cells, inflammatory cells infiltrating from serosal aspect and reaching up to submucosa in occasional foci (Figure 3). Von kossa stain

done did not revealed calcium deposits, Sudan black staining revealed fat droplets.



**Figure 2: Blotches of fat necrosis surrounded by xanthoma well cells and inflammatory cells (10 X; H&E).**



**Figure 3: Numerous xanthoma cells and inflammatory cells in the sub mucosa. (40X; H&E).**

Birefringent crystalloids were seen in these foci of fat necrosis on polarized microscopy in most of the unstained Canada balsam mounted sections and in occasional foci of fat necrosis in H & E stained sections (Figure 4), Histopathological diagnosis of Diffuse steatonecrosis secondary to Necrotizing pancreatitis was made.



**Figure 4: Birefringent crystalloids on polarized microscopy (40 X; Unstained section).**

## DISCUSSION

Fat necrosis occurs because of enzymes released from necrosed pancreas and is caused by death of adipose tissue with formation of small, dull chalky, gray white foci which represent small quantities of calcium soaps formed in affected tissue when fat is hydrolyzed to glycerol and fatty acids by lipase.

Keen CE et al cited a case of fat necrosis presenting as obscure abdominal mass where birefringent saponified fatty acid crystalloids gave clue to diagnosis.<sup>2</sup> They studied three cases and performed histochemical analysis using Nile blue sulphate for lipid, Holczinger's copper rubeanate for fatty acids and Alizarin red for calcium. In each of these cases, true nature of mass was not apparent to the surgeon. Histopathological examination revealed ghost adipocytes, containing numerous polarizing crystalloids. On histochemical analysis, crystalloids behaved as calcium salts of free fatty acids. Kusum D, et al presented a case of chronic pancreatitis wherein fat necrosis was seen in the small intestinal serosa extending through the muscularis propria with splaying of muscle fibers and reaching to submucosa. They studied 11 autopsy cases of chronic pancreatitis over a period of one year, five of them showed evidence of fat necrosis, saponified fatty acid crystalloids not seen in every case.<sup>1</sup> Agarwal S, et al cited an unusual case of cutaneous pancreatic fat necrosis which presented clinically as diffuse erythema and subcutaneous nodules in pretibial region.<sup>3</sup> Diffuse erythema is an unusual presentation of pancreatic fat necrosis. Cannon JR, et al presented a case of subcutaneous fat necrosis with initial manifestation of attack of acute pancreatitis, accompanying features of respiratory distress, leukemoid reaction, shock, pulmonary edema and arthritis due to periarticular fat necrosis. Autopsy revealed pancreatic pseudocyst, serofibrinous peritonitis, pleuritis, pericarditis and fat necrosis not only in subcutaneous fat but also in pericardial, pleural, mediastinal, mesenteric, retroperitoneal and pericardial fat.<sup>4</sup> Saag KG et al presented a case of subcutaneous fat necrosis associated

with acute arthritis.<sup>5</sup> Uncommonly arthritis is seen associated with acute pancreatitis. Birefringent crystal like structures led to initial diagnostic confusion with gout.

## CONCLUSION

Diffuse steatonecrosis secondary to gangrenous pancreatitis presenting as vague abdominal mass with intestinal gangrene may cause diagnostic dilemma and may mimic carcinoma intra-operatively. Diffuse steatonecrosis should be considered in the differential diagnosis in the case of such clinical setting.

*Funding: No funding sources*

*Conflict of interest: None declared*

*Ethical approval: Not required*

## REFERENCES

1. Kusum D, Semrani S, Deshpande. Migration of steatonecrosis in pancreatitis. Indian J Pathol Microbiol. 2006;49(4):546-7.
2. Keen CE, Buk SJA, Brady K, Levison DA. Fat necrosis presenting as obscure abdominal mass: Birefringent saponified fatty acid crystalloids as a clue to diagnosis. J Clin Pathol. 1994;47:1028-31.
3. Agarwal S, Nelson JE, Stevens SR, Gilliam AC. Diffuse erythema as an unusual presentation of pancreatic fat necrosis. J Cutan Med Surg. 2002;6(1):16-8.
4. Cannon JR, Pitha JN, Everett MA. subcutaneous fat necrosis in pancreatitis. J Cutan Pathol. 1979;6(6):501-6.
5. Saag KG, Niemann TH, Warner CA, Naides SJ. subcutaneous pancreatic fat necrosis associated with acute arthritis. J Rheumatol. 1992;19(4):630-2.

**Cite this article as:** Kumar B, Chachra U, Bhuvan. Diffuse steatonecrosis - presenting as an obscure abdominal mass - a diagnostic dilemma. Int J Res Med Sci 2017;5:734-6.