

Case Report

Antenatal diagnosis of Thanatophoric dysplasia: a case report and review of literature

Keerthi Kocherla*, Vasantha Kocherla

Department of Obstetrics and Gynaecology, Keerthi Hospital, Nalgonda-508001, Andhra Pradesh, India

Received: 30 April 2014

Accepted: 4 May 2014

***Correspondence:**

Dr. Keerthi Kocherla,

E-mail: key3cool@gmail.com

© 2014 Kocherla K et al. This is an open-access article distributed under the terms of the Creative Commons Attribution Non-Commercial License, which permits unrestricted non-commercial use, distribution, and reproduction in any medium, provided the original work is properly cited.

ABSTRACT

Thanatophoric dysplasia is the lethal skeletal dysplasia characterized by marked underdevelopment of the skeleton and short-limb dwarfism. Foetus has short neck, narrow thoracic cage and protruberant abdomen. Other anatomical features include a relatively enlarged head with frontal bossing, platyspondyly, telephone handle femurs. Thanatophoric dysplasia is usually diagnosed using second trimester ultrasonography. We report this rare entity from rural India with emphasis on its anatomical features along with review of relevant literature.

Keywords: Thanatophoric dysplasia, Lethal bone dysplasia, Prenatal diagnosis, Fibroblast growth factor receptor 3 gene mutation.

INTRODUCTION

Thanatophoric dysplasia is a type of neonatal lethal skeletal dysplasias characterized by marked underdeveloped skeleton and short-limb dwarfism. Thanatophoric Dysplasia (TD) is one of the rare, lethal osteochondrodysplasia characterized by shortening of the limbs, small conical thorax with shortened ribs, platyspondyly and macrocephaly.

TD is divided into 2 clinically defined subtypes type 1 and 2 with some clinical overlap between the 2 subtypes. Autosomal dominant mutations in the fibroblast growth factor receptor 3 gene (FGFR3), which has been mapped to chromosome band 4p16.3, results in both subtypes. Currently, majority of cases are due to de novo mutations in FGFR3 gene. It is of two major subtypes viz. a short curved femur characterizes type 1, while a straighter femur with clover leaf skull characterizes type 2.

It was reported that hypochondroplasia, achondroplasia and thanatophoric dysplasia are the different types of mutation in FGFR3 with hypochondroplasia being the mildest and TD, the most severe form.

The characteristic sonographic features suggest the diagnosis prenatally.

We report a case of Type I thanatophoric dwarfism showing typical imaging findings, along with a review of the literature.

CASE REPORT

A 26-year-old, healthy, married woman with history of one previous spontaneous abortion was brought to the hospital at 26 weeks of gestation for antenatal evaluation. There was no family history of genetic disorders.

Ultrasound examination revealed a single live foetus in cephalic presentation with abnormal biometry and

morphology. Humerus, radius and ulna, tibia and fibula were short. Femurs were both short and bowed showing typical telephone receiver deformity with femoral length corresponding to 17 to 18 weeks. Femur length was less than 4 standard deviation and all other long bones are on 2nd centile.

Femur to foot length was <0.8 suggesting skeletal dysplasia. Femur length/abdominal circumference was 0.2 (normal is <0.12). The thoracic cavity was hypoplastic and narrow with short ribs with absolute thoracic circumference measurement corresponding to 10th centile. Skull revealed mild frontal bossing. However, all the bones show normal mineralization. Based on these findings, a diagnosis of lethal bony dysplasia was offered.

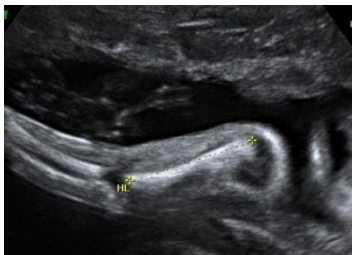


Figure 1

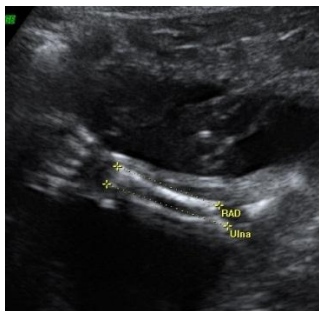


Figure 2

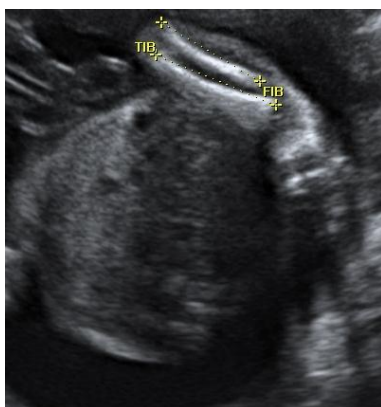

Figure 3

Figure 1-3: Gray scale ultrasound images reveal micromelia involving the long bones. All the long bones are on 2nd centile.

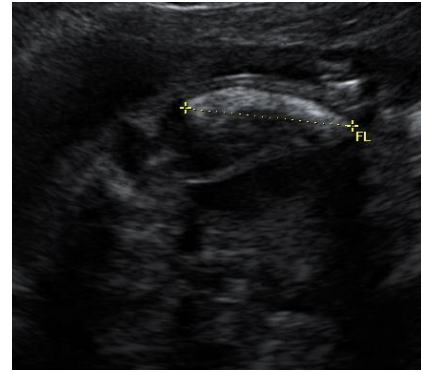

Figure 4: Gray scale ultrasound image reveals short and bowed femur.

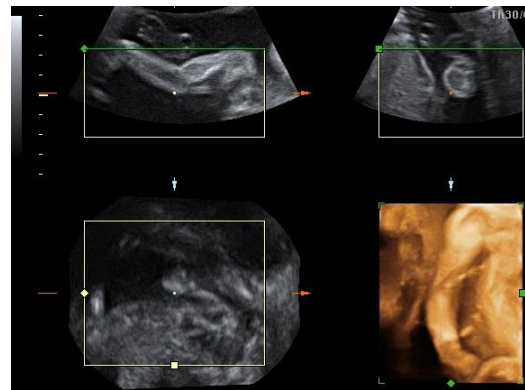


Figure 5: 3D imaging findings reveal short and bowed femur.

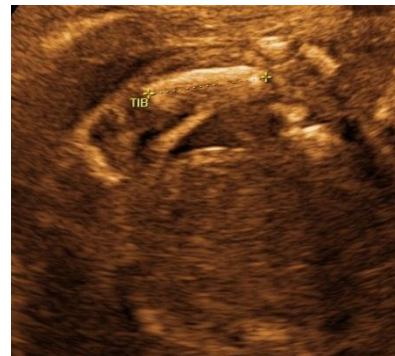

Figure 6: 3D imaging findings reveal shortened tibia.

The macrocranium with no clover leaf-shaped skull and the presence of telephone receiver femurs suggests type I thanatophoric dysplasia.

Patient opted for termination of pregnancy. Photographs and radiographs of aborted fetus were taken. Aborted foetus showed micromelia, narrow thorax, frontal bossing.

Radiograph showed severe tetra micromelia with bowing prominently seen in femur (telephone receiver deformity), narrow thorax, platyspondyly and small pelvis, frontal bossing.

This case report emphasizes the need into the insight regarding the problem of congenital malformations and their early prenatal diagnosis, which will aid in an alternative option of termination of pregnancy when an affected fetus is detected.

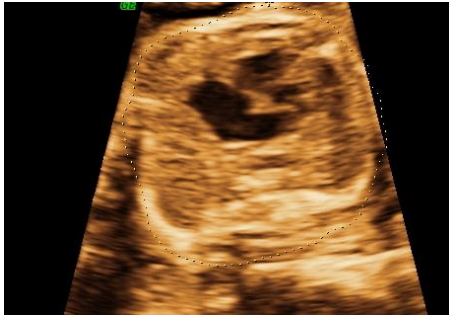

Figure 7: 3D imaging reveals narrow, hypoplastic thorax. Absolute thoracic circumference corresponding to 10th percentile.

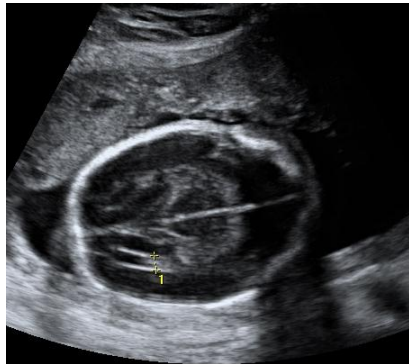

Figure 8: Gray scale imaging reveals frontal bossing of skull.

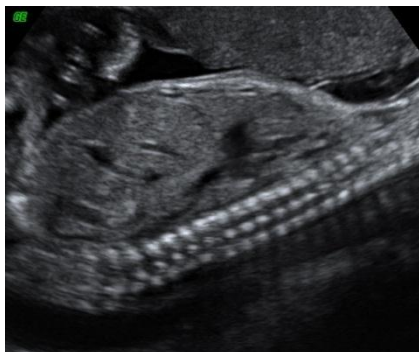

Figure 9: Gray scale ultrasound image reveals narrow thorax and protruberant abdomen.

DISCUSSION

The term thanatophoric dysplasia is derived from the Greek word thanatophorus, meaning death bearing. It has an incidence of 0.24 to 0.69 out of 10000 births.¹⁻³

Thanatophoric dysplasia is divided into 2 clinically defined subtypes: thanatophoric dysplasia type I (TDI or TD1) and thanatophoric dysplasia type II (TDII or TD2).

Both TDI and TDII are caused by an autosomal dominant point mutation in the fibroblast growth factor receptor 3 (FGFR3). The gene, FGFR3, is mapped to the short-arm of chromosome 4(4p16.3). Currently, all cases of thanatophoric dysplasia are due to de novo mutations in FGFR3.^{4,5}

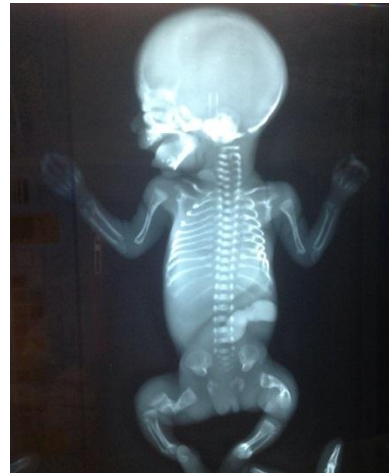

Figure 10: Anteroposterior post natal radiograph shows frontal bossing, tetra micromelia, narrow thorax with short ribs, telephone receiver deformity of both femurs, protuberant abdomen.

It is a lethal skeletal dysplasia characterised by a large head with frontal bossing, depressed nasal bridge, short long bones (micromelia), platyspondyly, narrow chest and short ribs. However the length of the trunk is normal.^{6,7}

TDI, the more common subtype (80%) is characterized by a normal-shaped skull and curved long bones (shaped like the old-fashioned telephone receivers); the femurs are most affected.⁸

TDII is the less common type (20%) associated with a cloverleaf-shaped skull and straight femurs. vertebral bodies are a little taller than in type I.^{9,10}

In addition, reported cases have cited clinical overlap between these subtypes.

Association of soft tissue syndactyly of fingers and toes was for the first time reported by Brodie et al.¹¹

Thanatophoric dysplasia is always lethal, due to severe pulmonary and thoracic hypoplasia.¹²

Polyhydramnios is common in both types. other less common findings include ventriculomegaly, corpus callosal agenesis, cardiac defects and thickening of

nuchal translucency¹³⁻²¹ Antenatal sonography in second trimester not only confirms the diagnosis but also differentiates it from the other non-lethal dysplasias. Three dimensional ultrasound is able to visualize the thickened redundant skin fold, limb and craniofacial anomalies more clearly.²²

X-ray examination must be performed after birth to confirm various findings which along with the autopsy diagnosis helps in counselling of the parents.²³

Funding: No funding sources

Conflict of interest: None declared

Ethical approval: Not required

REFERENCES

1. Connor JM, Connor RA, Sweet EM, Gibson AA, Patrick WJ, McNay MB, et al. Lethal neonatal chondrodysplasias in the west of Scotland 1970-1983 with a description of a thanatophoric, dysplasia like autosomal recessive disorder, Glasgow variant. *Am J Med Genet.* 1985;22:243.
2. Rasmussen SA, Bieber FR, Benacerraf BR, Lachman RS, Rimoin DL, Holmes LB. Epidemiology of osteochondrodysplasia: changing trends due to advances in prenatal diagnosis. *Am J Med Genet.* 1996;61:49-58.
3. Spranger J. International nomenclature of constitutional bone diseases (the Paris nomenclature). *Fortschr Geb Rontgenstr Nuklearmed.* 1971;15:283-7.
4. Martinez-Frias ML, Egues X, Puras A, Hualde J, de Frutos CA, Bermejo E, et al. Thanatophoric dysplasia type II with encephalocele and semilobar holoprosencephaly: insights into its pathogenesis. *Am J Med Genet A.* 2011 Jan;155A(1):197-202.
5. Naveen NS, Murlimanju BV, Kumar V, Pulakunta T. Thanatophoric dysplasia: a rare entity. *Oman Med J.* 2011 May;26(3):196-7.
6. Beetham FGT, Reeves JS. Early ultrasound diagnosis of thanatophoric dwarfism. *J Clin Ultrasound.* 1984;12:43.
7. Moore QS, Banik S. Ultrasound scanning in a case of thanatophoric dwarfism with clover-leaf skull. *Br J Radiol.* 1980;53:241-5.
8. Brodie SG, Kitoh H, Lipson M, Sifry-Platt M, Wilcox WR. Thanatophoric dysplasia type I with syndactyly. *Am J Med Genet.* 1998;80:260-2.
9. Weber M, Johannison R, Carstens C, Pauschert R, Niethard FU. Thanatophoric dysplasia type II: new entity? *J Paediatr Orthop B.* 1998;7:10-22.
10. Isaacson G, Blakemore KJ, Chervenak EA. Thanatophoric dysplasia with clover leaf skull. *Am J Dis Child.* 1983;137:896-8.
11. Brodie SG, Kitoh H, Lachman RS, Nolasco LM, Mekikian PB, Wilcox WR. Platypondylic lethal skeletal dysplasia, San Diego type is caused by FGFR3 mutation. *Am J Med Genet.* 1999;84:476-80.
12. Paladini D, Volpe P. Ultrasound of congenital foetal anomalies: differential diagnosis and prognostic indicators. Taylor & Francis, Informa UK Ltd. 2007:294-6.
13. Fink IJ, Filly RA, Callen PW, Fiske CC. Sonographic diagnosis of thanatophoric dwarfism in utero. *J Ultrasound Med.* 1982;1:337-9.
14. Mahony BS, Filly RA, Callen PW, Golbus MS. Thanatophoric dwarfism with the cloverleaf skull: a specific antenatal sonographic diagnosis. *J Ultrasound Med.* 1985;4:151.
15. Sun CC, Grumbach K, DeCosta DT, Meyers CM, Dungan JS. Correlation of prenatal ultrasound diagnosis and pathologic findings in foetal anomalies. *Paediatr Dev Pathol.* 1999;2:131-42.
16. Beetham FGT, Reeves JS. Early ultrasound diagnosis of thanatophoric dwarfism. *J Clin Ultrasound.* 1984;12:43-4.
17. Burrows PE, Stannard MW, Pearrow J, Sutterfield S, Baker ML. Early antenatal sonographic recognition of thanatophoric dysplasia with clover leaf skull deformity. *Am J Roentgenol.* 1984;143:841-3.
18. Elejalde BR, de Elejalde MM. Thanatophoric dysplasia: foetal manifestations and prenatal diagnosis. *Am J Med Genet.* 1985;22:669.
19. Weiner CP, Williamson RA, Bonsib SM. Sonographic diagnosis of clover leaf skull and thanatophoric dysplasia in the second trimester. *J Clin Ultrasound.* 1986;14:463-5.
20. Harten van der JJ, Brons JTT, Dijkstra PF. Some variants of lethal neonatal short-limbed platyspondylic dysplasia: a radiologic, ultrasonographic, neuro-pathologic and histopathologic study of 22 cases. In: Brons JTT, van der Harten JJ, eds. *Skeletal Dysplasia: Pre and Postnatal Identification, an Ultrasonographic, Radiologic and Pathologic Study.* 1st ed. Amsterdam: Free University Hospital; 1988:111.
21. Chervenak FA, Blakemore KJ, Isaacson G, Mayden K, Hobbins JC. Antenatal sonographic findings of thanatophoric dysplasia with cloverleaf skull. *Am J Obstet Gynaecol.* 1983;146:984.
22. Garjian KV, Pretorius DH, Budorick NE, Cantrell CJ, Jhonson DD, Nelson TR. Foetal skeletal dysplasias: three dimensional ultrasound: initial experience. *Radiology.* 2000;214:717-23.
23. Sauer I, Klein B, Leeners B, Cotarello C, Heyl W, Funk A. Lethal osteochondrodysplasias: prenatal and postnatal differential diagnosis. *Ultraschall Medizin.* 2000;21:112-21.

DOI: 10.5455/2320-6012.ijrms20140830

Cite this article as: Kocherla K, Kocherla V. Antenatal diagnosis of thanatophoric dysplasia: a case report and review of literature. *Int J Res Med Sci* 2014;2:1176-9.