

## Case Report

# Intrauterine retention of foetal bone: an IUCD effect

Balaji P. Nalwad<sup>1</sup>, Pradnya V. Gurude<sup>2\*</sup>

<sup>1</sup>Department of Obstetrics and Gynaecology, MIMSR Medical College, Latur, Maharashtra, India

<sup>2</sup>Department of Anatomy, BJGMC, Pune, Maharashtra, India

**Received:** 30 June 2014

**Accepted:** 13 July 2014

### \*Correspondence:

Dr. Pradnya V. Gurude,

E-mail: chinmaydev@yahoo.co.in

© 2014 Nalwad BP et al. This is an open-access article distributed under the terms of the Creative Commons Attribution Non-Commercial License, which permits unrestricted non-commercial use, distribution, and reproduction in any medium, provided the original work is properly cited.

## ABSTRACT

Intrauterine retention of foetal bone is a rare complication of abortion. These patients may present with irregular bleeding per vaginum, dysmenorrheal, pelvic pain and secondary infertility. A 27 year old female (G2, P1, L1, A1) referred by a general practitioner to our OPD as a case of secondary infertility. Patient was asymptomatic and had a second trimester abortion three years back. USG showed a foreign body in the uterine cavity. There was no history of IUCD insertion. On the advice of general practitioner, CT scan was done, which showed similar finding. Then this case was referred to us for further clinical evaluation. On hysteroscopy, we found foetal bones impacted between two Ostia which were removed with difficulty in the same setting. Dye test for patency of tubes was negative, probably due to edema. After that, patient conceived naturally within four months and delivered a healthy baby. Retained foetal bone in the uterine cavity was causing secondary infertility by its IUCD effect. Hysteroscopy is the gold standard method for diagnosis and treatment of foreign body in the uterine cavity.

**Keywords:** Intrauterine foetal bone, Abortion, Infertility, Hysteroscopy

## INTRODUCTION

Globally mid-trimester abortion procedures constitute 10 to 15% of all abortion being done.<sup>1</sup> Despite the liberalization of abortion services and the introduction of safer abortion techniques, complications do occur. Intrauterine retention of foetal bone is a rare complication of it. These patients may present with pelvic pain, dysmenorrhea, abnormal bleeding per vaginum and infertility. It is speculated that the presence of the bones may act as a uterine synechia or an IUCD and thus prevent pregnancy. It is also possible that the presence of foetal bones near the fundal region can lead to elevation of endometrial prostaglandins and thus impair implantation.<sup>2</sup>

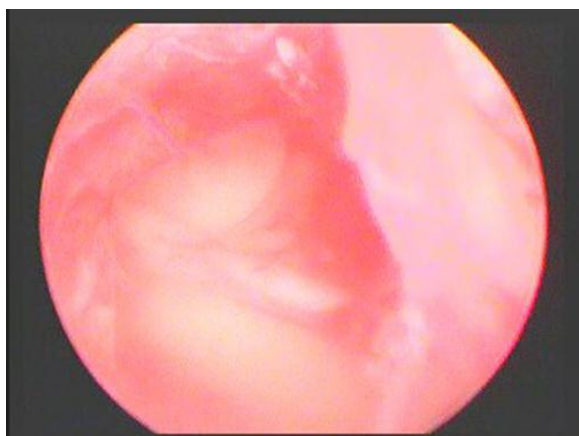
In the present study, we reported a case of secondary infertility due to prolonged retention of intrauterine bone with the history of second trimester abortion. There are

only few case reports of intrauterine retention of foetal bones after abortion or following removal of macerated foetus, so the present case report is an attempt to put forward such a rare finding. Hysteroscopic removal of such bony fragments may restore fertility in many patients as in present case.<sup>3</sup>

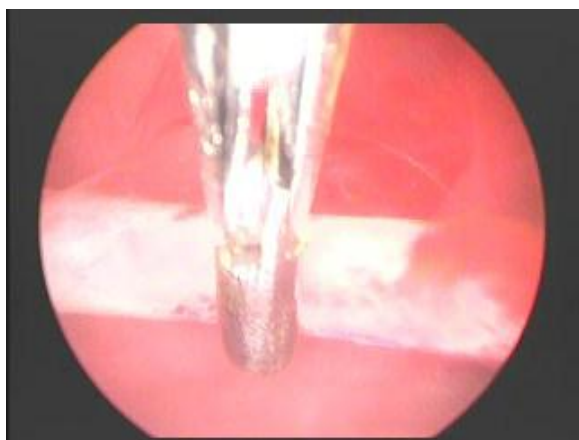## CASE REPORT

A 27 year old female patient (G2, P1, L1, A1) had approached a general practitioner for not been able to conceive for a second issue. Her child was of four years. Whereas her history highlights second trimester abortion three years back. Details of abortion were not available. On investigation, USG showed a foreign body in the uterine cavity, but there was no history of IUCD insertion. After that, general practitioner advised CT scan which showed similar finding as that of USG. This case was then referred to our OPD for further clinical

evaluation. General and systemic examinations were found to be normal. On per speculum examination cervix and vagina were normal. On per vaginal examination, uterus was of average size, normal shape, mobile, fornix non-tender. Hysteroscopy showed foetal bone impacted in between two Ostia. Bone was removed with difficulty in the same setting. Dye test for the patency of tubes was negative may be due to inflammatory cause. After the removal of retained bone hysteroscopically, the patient conceived naturally within four months and delivered 2.75 kg male baby.



**Figure 1: Foreign body in uterine cavity on hysteroscopy.**



**Figure 2: Hysteroscopic removal of foreign body.**

## DISCUSSION

In developing countries, infections are the leading cause of secondary infertility.<sup>4</sup> Intrauterine retention of foetal bone is rare complication of abortion, causing infertility due to its IUCD effect.

Taylor et al.<sup>5</sup> in a study of nine patients reported secondary infertility in seven, pelvic pain in one, and passage of bony fragments in one. Moon<sup>6</sup> reported eleven cases of secondary infertility caused by residual intrauterine foetal bone after mid-trimester abortion. Sahinoglu<sup>7</sup> described a case of postmenopausal bleeding

and pelvic pain caused by prolonged retention of foetal bones after a mid-trimester abortion. Verma<sup>8</sup> and Gupta<sup>9</sup> presented a case of unusual cause of pelvic pain due to intrauterine retention of foetal bone. Songshu Xiao<sup>10</sup> described an unusual case of retention of a large number of foetal bones with nearly intact morphology.

On the contrary, Van den Bosch<sup>11</sup> showed that uterine intramural bone persisting after mid-trimester termination of pregnancy may not affect fertility.

## CONCLUSION

Hysteroscopy has both diagnostic and therapeutic values. Hysteroscopic removal of the bony pieces should be regarded as the gold standard of the treatment since it enables a complete removal of the bones under direct vision. So, we recommend that every woman with complains of pelvic pain, bleeding per vaginum or infertility with past history of abortion, should be evaluated by transvaginal ultrasound or hysteroscopy. With advances in technology, now a days office hysteroscopy is also used to perform a panoramic visualization of the uterine cavity. A high success rate may be expected following the removal of any retained bones.

## ACKNOWLEDGEMENTS

The authors express their gratitude to Dr. Sheetal Joshi for her guidance to write this article.

*Funding: No funding sources*

*Conflict of interest: None declared*

*Ethical approval: Not required*

## REFERENCES

1. Lalitkumar S, Bygdeman M, Gemzell-Danielsson K. Midtrimester induced abortion. A review. Hum Reprod Update. 2007;13:37-52.
2. Dawood MY, Jarrett JC. Prolonged intrauterine retention of foetal bones after abortion causing infertility. Am J Obstet Gynaecol. 1982 Jul;143(6):715-7.
3. Goldberg JM, Roberts S. Restoration of fertility after hysteroscopic removal of intrauterine bone fragments. Obstet Gynaecol. 2008;112(2Pt 2):470-2.
4. Farley TMM, Belsey EM. The prevalence and etiology of infertility. In: Farley TMM, Belsey EM, eds. Proceeding of the African Population Conference. Dakar: International Union for the Scientific Study of Population (IUSSP); 1988: 1-33.
5. Taylor PJ, Hamou J, Mencaglia L. Hysteroscopic detection of heterotopic intrauterine bone formation. J Reprod Med. 1988;33:337-9.
6. Moon HS, Park YH, Kwon HY, Hong SH, Kim SK. Iatrogenic secondary infertility caused by residual intrauterine foetal bone after mid-trimester abortion. Am J Obstet Gynaecol. 1997 Feb;176(2):369-70.

7. Sahinoglu Z, Kuyumcuoglu U. An unusual case of postmenopausal vaginal bleeding: retention of foetal bone. *Arch Gynaecol Obstet.* 2003;267:160-2.
8. Verma U, Chong D, Perez I, Medina C. Foetal bones retained in the uterine cavity as a rare cause of chronic pelvic pain: a case report. *J Reprod Med.* 2004 Oct;49(10):853-5.
9. Gupta Nupur, Singh Neeta, Mittal Suneeta, Misra Renu, Dadhwal Vatsla. Intrauterine retention of foetal bones: an unusual cause of pelvic pain. *J Obstet Gynaecol India.* 2009;59(4):584-5.
10. Songshu Xiao, Qi Tian, Min Xue. Infertility caused by intrauterine fetal bone retention: a case report. *J Med Case Rep.* 2014;8:177.
11. Van den Bosch T, Van Schoubroeck D, Timmerman D, Deprest J. Uterine intramural bone after mid-trimester termination of pregnancy may not affect fertility: a case report. *Ultrasound Obstet Gynaecol.* 2003;22:407-8.

DOI: 10.5455/2320-6012.ijrms20140883

**Cite this article as:** Nalwad BP, Gurude PV. Intrauterine retention of foetal bone: an IUCD effect. *Int J Res Med Sci* 2014;2:1229-31.