

## Research Article

# Study of variations in the branching pattern of thoracodorsal nerve

Santosh Manohar Bhosale\*, Nagaraj S. Mallashetty

Department of Anatomy, S.S.I.M.S & R.C, Davangere, Karnataka, India

**Received:** 16 July 2014

**Accepted:** 10 August 2014

**\*Correspondence:**

Dr. Santosh Manohar Bhosale,

E-mail: drsantoshbhosale07@gmail.com

**Copyright:** © the author(s), publisher and licensee Medip Academy. This is an open-access article distributed under the terms of the Creative Commons Attribution Non-Commercial License, which permits unrestricted non-commercial use, distribution, and reproduction in any medium, provided the original work is properly cited.

### ABSTRACT

**Background:** Purpose of current study was to describe the variations in the origin of the thoracodorsal nerve of the posterior cord of brachial plexus and its distance of origin from mid-clavicular point in the South Indian population. These variations are important during surgical approaches to the axilla and upper arm, administration of anesthetic blocks, interpreting effects of nervous compressions and in repair of plexus injuries. The patterns of branching show population differences. Data from the South Indian population is scarce.

**Methods:** Forty brachial plexuses from twenty formalin fixed cadavers were explored by gross dissection. Origin and order of branching of axillary nerve and its distance of origin from mid-clavicular point was recorded. Representative photographs were then taken using a digital camera (Sony Cybershot R, W200, 7.2 Megapixels).

**Results:** In forty specimens studied, 72.5% of thoracodorsal nerves originated from posterior cord, which was predominant (75%) on the left side, 15% arose from axillary nerve which was observed in 20% of the right sided specimens and 12.5% had origin from the common trunk which was significant (15%) on the left side. In 32.5% of specimens, thoracodorsal nerve had origin at a distance of 4.1-4.5 cm, in 32.5% at a distance of 4.6-5.0 cm, in 17.5% at a distance of 5.1-5.5 cm, in 12.5% at a distance of 3.6-4.0 cm and in 5% at a distance of t more than 5.5 cm from mid-clavicular point.

**Conclusion:** Majority of thoracodorsal nerves in studied population display a wide range of variations. Significant number of thoracodorsal nerve also takes origin from axillary nerve and from common trunk at various distances from a fixed point. Anesthesiologists administering local anesthetic blocks, clinicians interpreting effects of nerve injuries of the upper limb and surgeons operating in the axilla should be aware of these patterns to avoid inadvertent injury and this study provide the necessary insight into the branching pattern of the thoracodorsal nerve and its distance of origin. Further study of the origin of thoracodorsal nerve of posterior cord of brachial plexus and its distance of origin from mid-clavicular point is recommended

**Keywords:** Posterior cord, Thoracodorsal nerve, Axillary, Common trunk, Mid-clavicular point

### INTRODUCTION

The brachial plexus is a complex network of nerves which extends from the neck to the axilla and supplies motor, sensory and sympathetic fibres to the upper extremity.

The brachial plexus is formed by platuing of ventral rami of the lower four cervical and the first thoracic nerves.

The plexus extends from the inferior lateral portion of the neck downward and laterally over the first rib, posterior to the clavicle and enters the axilla. The brachial plexus is divided into supraclavicular part and infraclavicular part. The infraclavicular part consists of three cords-lateral, medial and posterior. The posterior cord runs posterior to the second part of the axillary artery behind the pectoralis minor muscle and gives off the following branches - upper subscapular nerve, thoracodorsal nerve, lower

subscapular nerve, axillary nerve and then continues as a large terminal branch, the radial nerve.

The thoracodorsal nerve is highly variable in its origin, course and supply to the muscles; its variations become important as it is involved breast reconstructive surgery with latissimusdorsi flap, twitching of latissimusdorsi in post-operative breast cancer patients and neurotisation procedures.

Descriptions of nerve variations are useful in clinical/surgical practice since an anatomical variation can be the cause of a nerve palsy syndrome due to a different relation of a nerve and a related muscle.

Knowledge of variations in the origin of thoracodorsal nerves highly important in the surgical exploration of axilla, fracture of scapula, shoulder dislocation, transference of thoracodorsal nerve to axillary nerve or musculocutaneous nerve in old traumatic injury, thoracodorsal nerve used as graft for facial nerve in facial nerve injuries, the anatomical features of the thoracodorsal nerve make it particularly appropriate to match its trunk to the stump of the facial nerve at its exit from the stylomastoid foramen.

Anatomical variations in the origin of thoracodorsal nerve have been described by many authors, although these have not been extensively catalogued. These may be due to an unusual formation during the development of the trunks, divisions, or cords and they usually occur at the junction or separation of the individual parts.

For a surgeon, to know the variational patterns of origin of the thoracodorsal nerve at his finger's ends is essential in the light of not only the frequency with which the surgery is performed in the axilla and the surgical neck of the humerus and the rapid development of microsurgical techniques but also to give explanations when encountering an incomprehensible clinical sign.

Thus knowledge of variations in the origin and branching pattern of thoracodorsal nerve from the brachial plexus and its distance of origin from fixed point that is mid-clavicular point is important to anatomists, radiologists, surgeons and anesthesiologists in infraclavicular brachial plexus block and has gained importance due to the wide use and reliance on computer imaging in diagnostic medicine.

Literature on the variations in the origin of thoracodorsal nerve of the posterior cord of the brachial plexus and its distance of origin from mid-clavicular point among Indians is scanty and altogether lacking in South Indians.

The present study describes the variations in the branching pattern of lower subscapular nerve from the posterior cord of the brachial plexus observed in South Indian population.

## METHODS

### *Source of data*

The specimens for the study were obtained from the department of anatomy, S.S.I.M.S & R.C, Davangere.

Requisite consent had been obtained from the head of the department to conduct the study.

### *Sample size*

The study was carried out on forty upper limbs of adult human cadavers of both sex and age group between 30-60 years.

### *Inclusion criteria*

- All normal cadavers were included for the study.

### *Exclusion criteria*

- Deformed or traumatized upper limbs were excluded from the study.

### *Materials*

1. Dissection instruments
2. Measuring scale
3. Geometric radius
4. Sony cyber shot camera

### *Dissection procedure*

The cadaver was positioned in supine position with upper limb abducted at 90 degrees. The incision made on the skin over lateral part of thoracic wall in the mid axillary line at the level of nipple which is carried up to the lateral wall of axilla at the junction of anterior 2/3 and posterior 1/3 with two horizontal incisions medial and lateral to this point skin is elevated. The loose connective tissue, fat, and lymph nodes from the axilla were removed to expose its contents. The axillary artery and vein and the large nerves surrounding them were exposed. The smaller tributaries of the vein were removed in order to get a clear view of the nerves.

The radial nerve was identified behind the artery. It was traced upwards and at the lower border of subscapularis, the axillary nerve was seen passing backwards with the posterior humeral circumflex artery.

The pectoralis minor was cut across and the axillary vessels were followed to the outer border of the first rib. The anterior surface of subscapularis was exposed and the upper subscapular nerves entering it were identified.

The upper and lower subscapular and thoracodorsal nerves were traced to their origin from the posterior cord of the brachial plexus.

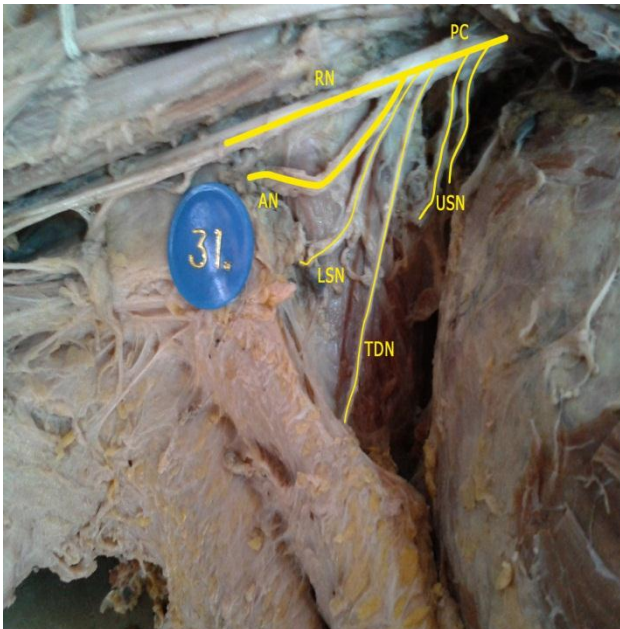
The distance of origin of thoracodorsal nerve from mid-clavicular point was noted and the origin of thoracodorsal nerve was studied.

Representative photographs were taken using a Sony Cybershot R (DSC W50, 7.2 MP) digital camera.

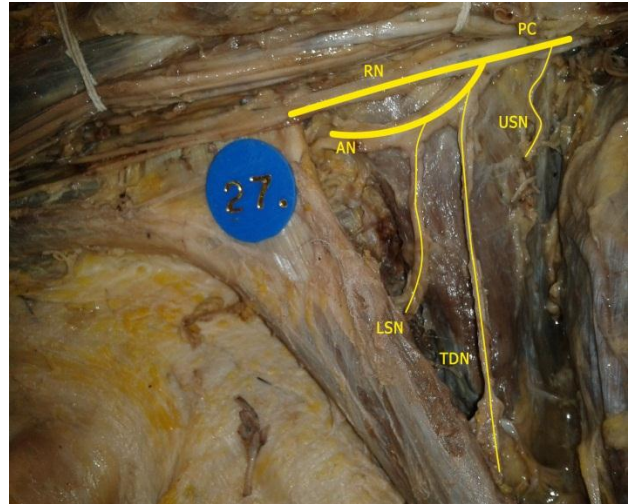
**RESULTS**

In forty specimens studied, 72.5% of thoracodorsal nerves originated from posterior cord, which was predominant (75%) on the left side (Figure 1), 15% arose from axillary nerve which was observed in 20% of the right sided specimens (Figure 2) and 12.5% had origin from the common trunk along with the axillary nerve (Figure 3) which was significant (15%) on the left side (Table 1).

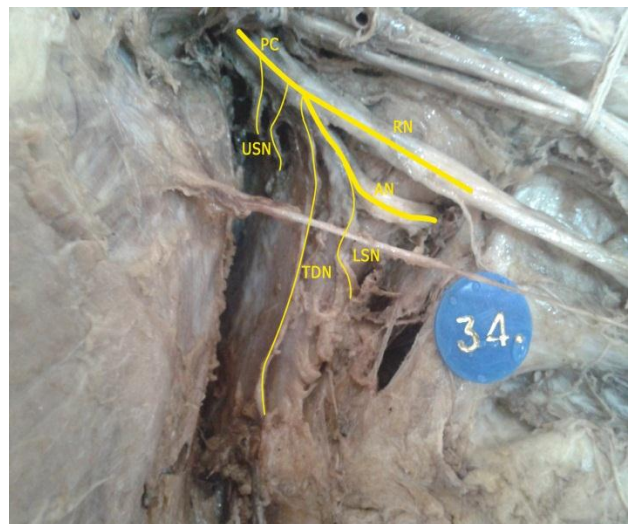
In 32.5% of specimens, thoracodorsal nerve had origin at a distance of 4.1-4.5 cm which was predominant (40%) on the left side, in 32.5% at a distance of 4.6-5.0 cm which was seen in maximum number (35%) on the right side, in 17.5% of specimens nerve originated at a distance of 5.1-5.5 cm which was significant (25%) on the left side, in 12.5% at a distance of 3.6-4.0 cm which was observed in majority (20%) on the right side and in 5% at a distance of more than 5.5 cm from mid-clavicular point which was seen only on the right side (Table 2).



**Figure 1: Showing origin of thoracodorsal nerve from posterior cord, list of abbreviations used: PC-Posterior cord, USN-Upper subscapular nerve, TDN-Thoracodorsal nerve, LSN-Lower subscapular nerve, AN-Axillary nerve, RN-Radial nerve.**



**Figure 2: Showing origin of thoracodorsal nerve from axillary nerve, list of abbreviations used: PC-Posterior cord, USN-Upper subscapular nerve, TDN-Thoracodorsal nerve, LSN-Lower subscapular nerve, AN-Axillary nerve, RN-Radial nerve.**



**Figure 3: Showing origin of thoracodorsal nerve from common trunk along with axillary nerve. List of abbreviations used: PC-Posterior cord, USN-Upper subscapular nerve, TDN-Thoracodorsal nerve, LSN-Lower subscapular nerve, AN- Axillary nerve, RN-Radial nerve.**

**Table 1: Showing frequency distribution of origin of thoracodorsal nerve on right and left sides.**

Site of origin	Rt. (N=20)	Lt. (No=20)	Total (N=40)
	n (%age)	n (%age)	n (%age)
Posterior cord	14 (70%)	15 (75%)	29 (72.5%)
Axillary nerve	04 (20%)	02 (10%)	06 (15%)
Common trunk	02 (10%)	03 (15%)	05 (12.5%)



**Table 2: Showing frequency distribution of distance of origin of thoracodorsal nerve on right and left sides.**

Distance from MCP	Rt. (N=20)	Lt. (No=20)	Total (N=40)
	n (%age)	n (%age)	n (%age)
3.6-4.0 cm	4 (20%)	1 (5%)	5 (12.5%)
4.0-4.5 cm	5 (25%)	8 (40%)	13 (32.5%)
4.6-5.0 cm	7 (35%)	6 (30%)	13 (32.5%)
5.1-5.5 cm	2 (10%)	5 (25%)	7 (17.5%)
>5.5 cm	2 (10%)	0	2 (5%)

## DISCUSSION

Brachial plexus forms the innervations of the upper limb.

During the early stages of development the upper limb buds lie opposite the lower five cervical and upper two thoracic segments. As soon as the limb buds form, the ventral primary rami of the spinal nerves penetrate into the mesenchyme of the limb bud.<sup>1</sup> At first each ventral ramus enters with isolated dorsal and ventral branches, but soon these branches unite to form large dorsal and ventral nerves for the extensor and flexor musculature of the upper extremity respectively. Immediately after the nerves enter the limb bud, they establish an intimate contact with the differentiating mesodermal condensations and the early contact between the nerve and muscle cells is a prerequisite for their complete functional differentiation.<sup>2</sup>

Several signaling molecules and transcription factors have been identified which induce the differentiation of the dorsal and ventral motor horn cells. Misexpression of any of these signaling molecules can lead to abnormalities in the formation and distribution of particular nerve fibres.<sup>3</sup>

In the current study among 40 specimens, thoracodorsal nerves have origin from posterior cord in 72.5% of specimens, from axillary nerve in 15% of specimens and from common trunk in 12.5% of specimens.

In a case reported by Bhat KMR and Girijavallabhan V the posterior cord was splitting into thick posterior and thin anterior roots, enclosing the subscapular artery near its origin. The two roots, after enclosing the subscapular artery were fused to continue as radial nerve. Thoracodorsal nerve was originating from thick posterior root of the cord.<sup>4</sup> No such variation was encountered in the present study.

Muthoka et al. in their study of 75 posterior cords mentioned that the thoracodorsal nerve originated from posterior cord in 66 (88%), from axillary nerve in 8 (10.7%) and from a common trunk with upper and lower subscapular nerves in 1 (1.3%).<sup>5</sup> this finding correlates with the present study.

Baliyan R et al. reported that the posterior cord branched into three upper subscapular nerves and a common trunk for the thoracodorsal nerve and lower subscapular nerve.<sup>6</sup> In current study 12.5% of thoracodorsal nerves have origin from common trunk.

Fazan VPS et al. conducted a study on 54 upper limbs and observed that the thoracodorsal nerve had origin from axillary nerve in 13% cases and from radial nerve in 5.5%.<sup>7</sup> This is coinciding with the observations in the study.

Chung CH and Yim JH et al. reported that the thoracodorsal nerve branched from the axillary nerve in 27.6%.<sup>8</sup>

The thoracodorsal nerve originated from the posterior cord in 98.5% of the cases and in 1.5% of the cases directly from the proximal segment of the radial nerve. The thoracodorsal nerve always originated as a single nerve from the brachial plexus.<sup>9</sup> The latter observation correlates with the present study.

## CONCLUSION

Majority of thoracodorsal nerves in studied population display a wide range of variations. Anesthesiologists administering local anesthetic blocks, clinicians interpreting effects of nerve injuries of the upper limb and surgeons operating in the axilla should be aware of these patterns to avoid inadvertent injury. Further study of the origin of thoracodorsal nerve of posterior cord of brachial plexus and its distance of origin from mid-clavicular point is recommended.

*Funding: No funding sources*

*Conflict of interest: None declared*

*Ethical approval: The study was approved by the institutional ethics committee*

## REFERENCES

1. Standring S. Brachial plexus. In: Standring S, eds. Gray's anatomy. The Anatomical Basis Of Clinical Practice. 40th ed. London: Elsevier Churchill Livingstone; 2008: 821-822.
2. Sandler TW. Brachial plexus. In: Sandler TW, eds. Langman's Medical Embryology. 10th ed. Philadelphia: Lippincott Williams and Wilkins; 2006: 146-147.
3. Satyanarayana N, Vishwakarma N, Kumar GP, Guha R, Datta AK, Sunitha P. Variation in relation of cords of brachial plexus and their branches with axillary and brachial arteries: a case report. *Nepal Med Coll J.* 2009;11(1):69-72.
4. Bhat KMR, Girijavallabhan V. Variation in the branching pattern of posterior cord of brachial plexus: a case report. *Neuroanatomy.* 2008;7:10-1.
5. Muthoka JM, Sinkeet SR, Shahbal SH, Matakwa LC, Ogeng'o JA. Variations in branching of the

- posterior cord of brachial plexus in a Kenyan population. *J Brachial Plexus Peripheral Nerve Injury.* 2011;6:1.
6. Baliyan R, Mehta V, Arora J, Nayyar AK, Suri RK, Rath G. Unilateral intercordal neural communication coexistent with variant branching pattern of posterior cord of brachial plexus. *Acta Medica (Hradec Králové).* 2011;54(3):131-4.
  7. Fazan VPS, Amadeu ADS, Caleffi AL, Filho OAR. Brachial plexus variations in its formation and main branches. *Acta Cir Bras.* 2003;18(5):1-8.
  8. Chung IH, Yim JH. Branching pattern and morphometry of the axillary nerve. *Korean J Anat.* 2000 Jun;33(3):373-9.
  9. Tubbs RS, Loukas M, Shahid K, Judge T, Pinyard J, Shoja MM, et al. Anatomy and Quantitation of the Subscapular nerves. *Clin Anat.* 2007;20:656-9.

DOI: 10.5455/2320-6012.ijrms20141116

**Cite this article as:** Bhosale SM, Mallashetty NS. Study of variations in the branching pattern of thoraco-dorsal nerve. *Int J Res Med Sci* 2014;2:1329-33.