

Case Report

Anomalous branching pattern of common hepatic artery: a case report

Sushant S. Das*, Babita Pangtey, Sabita Mishra

Department of Anatomy, Maulana Azad Medical College, New Delhi 110002, India

Received: 21 August 2014

Accepted: 5 September 2014

***Correspondence:**

Dr. Sushant S. Das,

E-mail: susvick@gmail.com

Copyright: © the author(s), publisher and licensee Medip Academy. This is an open-access article distributed under the terms of the Creative Commons Attribution Non-Commercial License, which permits unrestricted non-commercial use, distribution, and reproduction in any medium, provided the original work is properly cited.

ABSTRACT

A number of hepatic artery variations exists which is continuously proving a hindrance for the surgeons and radiologists. During routine dissection in the subhepatic region in 50 year old male cadaver for undergraduate teaching, a variation in the branching pattern of common hepatic artery was noticed. We observed an unusual branching of the common hepatic artery into seven terminal branches, of which two were left hepatic arteries, two were right gastric arteries and the remaining three were right hepatic artery, cystic artery and gastroduodenal artery. Hepatic artery proper was absent. Embryological basis of these variations were discussed. The present case is a rarity and will further throw light on the knowledge of the hepatic artery variations, thus assisting surgeons and radiologists in various surgical and diagnostic procedures.

Keywords: Common hepatic artery, Left hepatic artery, Right hepatic artery, Hepatic artery proper

INTRODUCTION

The celiac trunk which is a ventral branch of abdominal aorta typically divides into 3 branches, the left gastric, the splenic and the common hepatic artery. The common hepatic artery passes anteriorly and laterally below the epiploic foramen to the upper aspect of the first part of the duodenum. It gives the gastroduodenal artery and then the right gastric artery and continues as the hepatic artery proper. The hepatic artery proper passes anterior to the portal vein and ascends anterior to the epiploic foramen between the layers of lesser omentum. It is medial to the common bile duct and anterior to the portal vein. It divides further into right and left hepatic arteries; which supply right and left lobes of the liver respectively.¹ According to literature, this typical pattern of hepatic arterial system is found in only 52 to 80% of individuals.²

A number of hepatic artery variations have been reported.^{3,4} The pre-operative knowledge of these hepatic artery variations are of particular importance to surgeons and radiologists while doing liver transplantation, transarterial chemo-embolization for hepatic tumors and

to prevent vascular injuries during laproscopic cholecystectomy. We are reporting this unusual case of common hepatic artery dividing into seven terminal branches with absence of hepatic artery proper and presence of two left hepatic artery and two right gastric arteries.

CASE REPORT

During a routine abdominal dissection of a 50 year old male cadaver in the Department of Anatomy, Maulana Azad Medical College, New Delhi, a variation of hepatic arterial pattern was noticed. The common hepatic artery had its origin from the celiac trunk running towards the right side and upwards. Its length was 3.5 cm. At the porta, it directly divided into seven branches outside the liver. These included one gastroduodenal artery, two right gastric arteries, one right hepatic artery, one cystic artery and two left hepatic arteries. Hepatic artery proper was absent. The length of each artery was measured from its origin to termination. The gastroduodenal artery was 3.8 cm, the right gastric arteries were 2.5 and 3 cm, the left hepatic arteries were 1.5 and 2.5 cm, the right hepatic artery was 1.5 cm and the cystic artery was 4 cm (Figure 1).

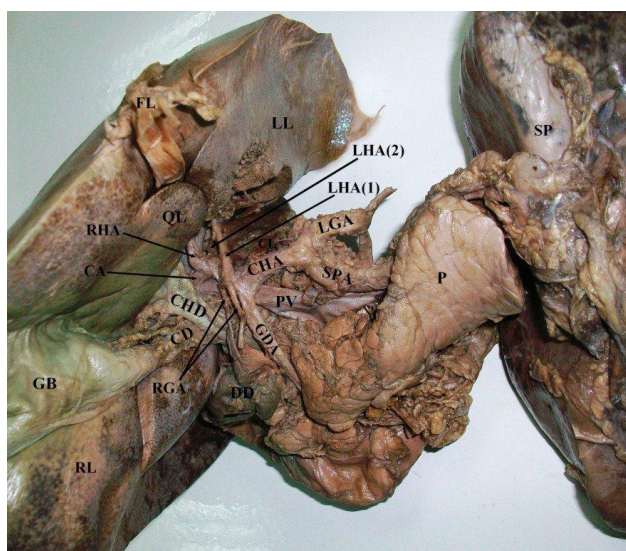


Figure 1: Photograph showing the common hepatic artery dividing into seven terminal branches in a 50 year old male cadaver. CHA common hepatic artery, RHA right hepatic artery, LHA(1) first left hepatic artery supplying II, III, IV hepatic segments, LHA(2) second left hepatic artery supplying caudate lobe, RGA two right gastric arteries, GDA gastroduodenal artery, SPA splenic artery, LGA left gastric artery, LL left hepatic lobe, RL right hepatic lobe, CL caudate lobe, QL quadrate lobe, DD duodenum, P pancreas, SP spleen, FL falciform ligament, CD cystic duct, CHD common hepatic artery.

The gastroduodenal artery ran inferiorly behind the first part of duodenum and divided into superior pancreaticoduodenal and right gastroepiploic arteries. The two right gastric arteries also ran inferiorly towards the pylorus and supplied the stomach. The cystic artery passed behind the common hepatic duct and then between the inferior surface of liver and upper surface of gall bladder to supply the gall bladder. The right hepatic artery passed anteriorly to the portal vein and medial to the common bile duct and was traced into the parenchyma of the liver. It was seen supplying the right hepatic lobe which included segments V, VI, VII, and VIII of liver. The remaining two branches supplied the left hepatic lobe as the left hepatic arteries out of which one passed anterior and medial to the portal vein and another ran posterior to the portal vein. They were further traced into the substance of the liver. It was observed that the anterior branch supplied II, III, IV (quadrate lobe) hepatic segments; the posterior branch supplied the caudate lobe (segment I). The course and origin of splenic and left gastric arteries were normal.

DISCUSSION

A number of variations in the hepatic arterial pattern have been reported by various authors. Michel categorized the origin of hepatic artery from ten different sources.³ The type I was normal pattern, in type II, a replaced right

hepatic artery was present arising from left gastric artery. In type III, a replaced left hepatic artery from superior mesenteric artery and in type IV, replaced left and right hepatic artery from left gastric and superior mesenteric artery respectively was present. In type V and VI, an accessory left or right hepatic artery was present originating from left gastric and superior mesenteric artery respectively. In type VII, both accessory left and right hepatic artery was present originating from left gastric and superior mesenteric artery respectively whereas in type VIII, they were seen originating from superior mesenteric artery and left gastric respectively. In type IX and X, the common hepatic artery was seen originating from superior mesenteric artery and left gastric respectively. Similarly, Hiatt et al. in a study of 1000 patients described six different origins of hepatic artery⁴: the typical anatomy (type I), left hepatic artery arising from left gastric artery (type II), right hepatic artery from superior mesenteric artery (type III), replaced left and right hepatic artery from left gastric and superior mesenteric artery respectively (type IV), common hepatic artery from superior mesenteric artery (type V), common hepatic artery from aorta (type VI). These two classifications are universally accepted. Our finding does not fall into any of these categories and has seldom been reported.

Covey et al. reported the division of the common hepatic artery into four branches viz. the gastroduodenal, the right hepatic, the left hepatic and the middle hepatic arteries in 0.5% of the 600 cases.⁵ A division of the common hepatic artery into a maximum of seven branches viz. two right hepatic arteries, three left hepatic arteries, the superior pancreatico-duodenal and the right gastroepiploic artery has been reported by Sharmila Saran et al.⁶ In the present case, the common hepatic artery is also dividing into seven branches which are different from above viz. one right hepatic artery, two left hepatic arteries, one cystic artery, two right gastric arteries and one gastroduodenal artery. This type of variation has not been reported in literature.

Accessory left hepatic arteries are reported in 11% of cases with origin mainly from the left gastric artery, hepatic artery proper or the celiac trunk.² But incidence from the common hepatic artery is very rare as reported by Futura et al⁷ and Pai et al.² In the present case, both left hepatic artery were found to arise from the common hepatic artery. Ugurel et al. reported that the incidence of the variations of celiac trunk and hepatic arteries increased with the presence of the accessory renal arteries. However, the renal arteries were normal in the present case.⁸

The anomalous branching pattern of hepatic artery has an embryological basis. In embryonic life, the dorsal aorta gives many vitelline branches. These arteries start fusing and regressing which finally give rise to the celiac, the superior and inferior mesenteric arteries. The left hepatic artery, the middle hepatic artery and the right hepatic

artery initially arise from the left gastric artery, the celiac axis and the superior mesenteric artery respectively. Later on, the embryonic left and right hepatic arteries regress and the middle hepatic artery persists as the hepatic artery proper in adults. The hepatic artery proper divides into right and left hepatic artery near the hilum of liver. Variable branching pattern or accessory hepatic arteries are due to failure of regression of these arteries.^{6,9} Each and every variation is important as ignorance of its knowledge may lead to potential risks or complications.

The anomalous branching pattern of hepatic artery may be attributed to the errors in the complex developmental stages of vascular pattern. In intrauterine period, hepatocystic bud arises from the junction of the foregut and midgut. This bud receives blood supply from the direct branches of aorta, coeliac trunk and the superior mesenteric artery. Consecutively, some of these vessels persists and others are absorbed, resulting in the mature vascular pattern.^{6,9} Any errors in this complex process results in an unusual vascular pattern as observed in this case.

Funding: No funding sources

Conflict of interest: None declared

Ethical approval: None required

REFERENCES

1. Standring S, ed. Gray's Anatomy. The Anatomical Basis of Clinical Practice. 40th Ed., Edinburg, Churchill & Livingstone. 2008;1231-3.
2. Pai RS, Hunnargi AS, Srinivasan M. Accessory left hepatic artery arising from common hepatic artery. The Indian journal of surgery 2008;70(2):80-2.
3. Michels NA. Newer anatomy of the liver and its variant blood supply and collateral circulation. American journal of surgery 1966;112(3):337-47.
4. Hiatt JR, Gabbay J, Busuttil RW. Surgical anatomy of the hepatic arteries in 1000 cases. Annals of surgery 1994;220(1):50-2.
5. Covey AM, Brody LA, Maluccio MA, Getrajdman GI, Brown KT. Variant hepatic arterial anatomy revisited: digital subtraction angiography performed in 600 patients. Radiology 2002;224(2):542-7.
6. Sharmila Saran rajendran SkA, Aruna Subramaniam, M.S Thotakura Balaji, Hannah Sugirthabai Rajila Rajendran. Variable branching pattern of the common hepatic artery and the celiac artery. Journal of Clinical and Diagnostic Research 2011;5(7):1433-6.
7. Futara G, Ali A, Kinfu Y. Variations of the hepatic and cystic arteries among Ethiopians. Ethiopian medical journal 2001;39(2):133-42.
8. Ugurel MS, Battal B, Bozlar U, Nural MS, Tasar M, Ors F, Saglam M, Karademir I. Anatomical variations of hepatic arterial system, coeliac trunk and renal arteries: an analysis with multidetector CT angiography. The British journal of radiology 2010;83(992):661-7.
9. Schwarz L, Huet E, Yzet T, Fuks D, Regimbeau JM, Scotte M. An extremely uncommon variant of left hepatic artery arising from the superior mesenteric artery. Surg Radiol Anat 2013:1-4.

DOI: 10.5455/2320-6012.ijrms20141198

Cite this article as: Das SS, Pangtey B, Mishra S. Anomalous branching pattern of common hepatic artery: a case report. Int J Res Med Sci 2014;2:1740-2.