

Case Report

Bilateral high division of sciatic nerve

K. Shwetha^{1,*}, KR Dakshayani¹

¹Department of Anatomy, Mysore Medical College and Research Institute, Mysore-570001, Karnataka, India

Received: 12 October 2014

Accepted: 26 October 2014

***Correspondence:**

Dr. K. Shwetha,

E-mail: shwethajagannath85@gmail.com

Copyright: © the author(s), publisher and licensee Medip Academy. This is an open-access article distributed under the terms of the Creative Commons Attribution Non-Commercial License, which permits unrestricted non-commercial use, distribution, and reproduction in any medium, provided the original work is properly cited.

ABSTRACT

Sciatic nerve is the thickest nerve in the body formed by the sacral plexus from L4 to S3 in the lesser pelvis. It emerges through the greater sciatic foramen below the piriformis and enter the gluteal region. Then the nerve passes on the back of the thigh and at the level of superior angle of popliteal fossa it terminates by dividing into tibial and common peroneal nerve. The knowledge of anatomical variations in the division of nerve is important for various surgical and anaesthetic procedures. During routine dissection in the department of anatomy, Mysore Medical College & Research Institute, Mysore, a rare bilateral high division of sciatic nerve was observed in a female cadaver aged about 40 years. In the present case there was bilateral high division of sciatic nerve. The nerve was seen dividing into two branches before it emerges through the greater sciatic foramen. The tibial nerve was entering the gluteal region below the piriformis muscle and common peroneal nerve was entering by piercing the piriformis. The knowledge of this variation is important as the nerve may get compressed with surrounding anatomical structures resulting in non discogenic sciatica. The awareness of variations is important for surgeons during various procedures like fracture, posterior dislocation of hip joint and hip joint replacement. The anatomical variations are important during deep intramuscular injections in gluteal region and also for anaesthetists during sciatic nerve block.

Keywords: Sciatic nerve, Piriformis, Tibial nerve, Common peroneal nerve

INTRODUCTION

Sciatic nerve is the thickest nerve in the human body. It is formed in the lesser pelvis by ventral division of L4 to S3. It leaves the pelvis and enters the gluteal region through greater sciatic foramen, below the piriformis muscle. It runs in the posterior aspect of the thigh. Then at the superior angle of popliteal fossa it divides into tibial and common peroneal nerve.¹

There may be numerous variations in the course, division and distribution of the nerve. The variations in the relationship between sciatic nerve and piriformis muscle are common and are clinically significant. Sometimes it divides into terminal branches at high level while still in the pelvis, then it exit in different ways. Accordingly the relation between the nerve and piriformis muscle is classified into different types.²

The knowledge of these anatomical variations of nerve is important for surgeons, anaesthetists and clinicians during various procedures and diagnosing various clinical conditions.

CASE REPORT

During routine dissection in the department of anatomy, Mysore Medical College & Research Institute, Mysore, a rare bilateral high division of sciatic nerve was observed in a female cadaver aged about 40 years.

In the present case there was bilateral high division of sciatic nerve. The nerve was seen dividing into two branches before it emerges through the greater sciatic foramen. The tibial nerve was entering the gluteal region below the piriformis muscle and common peroneal nerve was entering by piercing the piriformis.

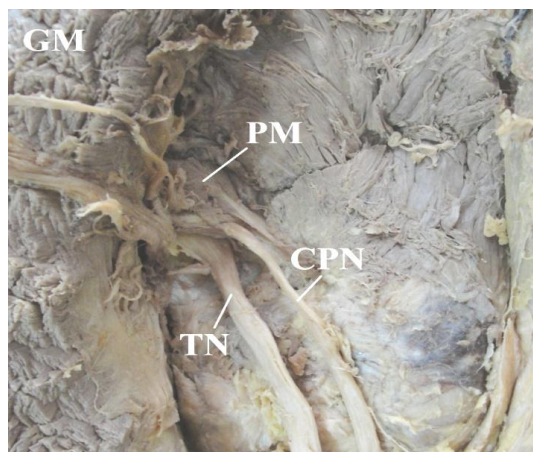


Figure 1: Right side, GM- Gluteus Maximus, PM- Piriformis Muscle, CPN- Common Peroneal Nerve TN-Tibial Nerve.

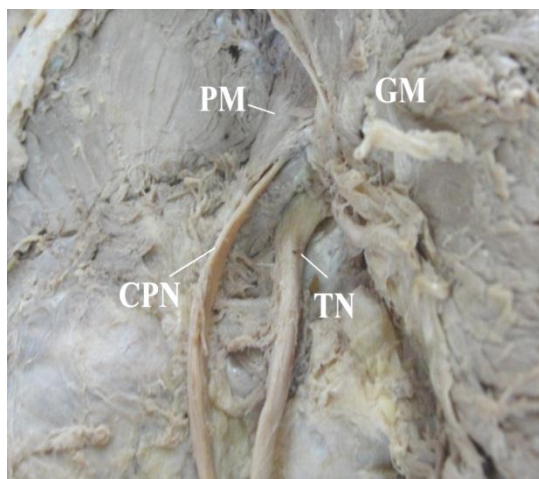


Figure 2: Left side, GM- Gluteus Maximus, PM- Piriformis Muscle, CPN- Common Peroneal Nerve TN- Tibial Nerve.

DISCUSSION

There are various studies conducted on the variations of sciatic nerve division. The nerve is formed in the lesser pelvis and runs in the gluteal region, back of the thigh and terminates in the superior angle of popliteal fossa. There are numerous reports in the literature of terminal division of the sciatic nerve that, it can be divided at any point from its origin to termination.³

Accordingly the level of division of nerve can be classified into different groups. Group A consists of sciatic nerve division proximally to its exit in the gluteal region. In Group B, it divides in the gluteal region. In Group C, D and E it divides in the upper, middle and lower region of the thigh respectively. In Group F the nerve divides in the popliteal fossa.⁴

If the sciatic nerve divides while still in the pelvis, then the relation between the nerve and the piriformis muscle

varies.¹ These variations are usually bilateral and if it is unilateral then the other side will mostly remains normal.²

Beaton and Anson classified variations of the piriformis muscle and the sciatic nerve in 240 specimens in 1938 into different types. The classification is known as Beaton and Anson classification, is as follows.²

Type 1: Undivided nerve below undivided muscle

Type 2: Division of nerve between and below undivided muscle

Type 3: Division above and below undivided muscle

Type 4: Undivided nerve between heads

Type 5: Division between and above heads

Type 6: Undivided nerve above undivided muscle

In the present case Type 2 variation was seen bilaterally, which is the most common type. A study conducted by Smoll NR in 2010, by a systemic review and meta-analysis of literature, assessing the prevalence of anatomical variations from 18 anatomical studies on over 6062 limbs observed 10.5% of type 2 variation.⁵ In another study conducted by K Natis in 2013, in 294 limbs noted the type 2 variation in 12 limbs(4.1%).⁶ Beaton and Anson, in their study have observed type 2 variation in 11.7% limbs.⁷ A rare variation was observed by Babinski et al, they have noted, the common peroneal nerve passed superior and tibial nerve inferior to superior gemellus muscle.⁷

Interpretation of nerve variations in the limb requires a consideration of phylogeny and development of sacral plexus. There is a wide consensus in the literature that the variants of the sciatic nerve most likely result from a stochastic process of separation of the primitive elements of the sciatic nerve. The lower limb bud is initially associated with the primitive lumbar and sacral plexuses. As the limb elongates and widens, the nervous elements are drawn distally and are separated into dorsal and ventral components, distributed into the developing anterior and posterior muscles and overlying integument. The sciatic nerve is formed by parallel development of the dorsal and ventral components of the growing sacral plexus which give to common peroneal and tibial nerve respectively. These two nerves are ensheathed by common epineural sheath to a variable length in the definitive form. But the sciatic nerve can divide into its terminal branches at any level and lead to variations in the level of division of nerve.³

The anatomical variations of the nerve have important clinical implications. The variation in the relationship between the sciatic nerve and the piriformis muscle lead to compression of the nerve resulting in piriformis syndrome or non discogenic sciatica.² During popliteal block for

surgeries of foot and ankle region, the sciatic nerve is approached 5-7 cm above the transverse popliteal crease. In such procedures the high division of nerve lead to failure of sciatic nerve block.⁸ The knowledge of variation of nerve is important for surgeons during various procedures taking place in the gluteal region like posterior dislocation of hip, total hip replacement, hemiarthroplasty. Also this knowledge is very important for nurses and junior doctors to prevent nerve injury during deep intra muscular injections in the gluteal region.²

CONCLUSION

The variations in the level of division of sciatic nerve and its relation to piriformis muscle are not a rare condition. The awareness of these variations plays an important part for surgeons, anaesthetists and clinicians during various procedures and diagnosing various clinical conditions.

ACKNOWLEDGEMENTS

We thank all the teaching and non-teaching staff members of the Department of Anatomy, Mysore Medical College and Research Institute, Mysore for their constant support and co-operation.

Funding: None

Conflict of interest: Not declared

Ethical approval: Not required

REFERENCES

1. W Andrew, LMN Richard, SD Mart, C Patricia. Pelvic girdle, gluteal region and hip joint. Gray's

Anatomy, The anatomical basis of clinical practice, 39th ed. Edinburgh: Elsevier Churchill Livingstone; 2006.1456- 1458.

2. P Shailesh, S Mitesh, V. Rakesh, Z Ankur, Rathod SP. A variation in the high division of the sciatic nerve and its relation with piriformis muscle. NJMR: 2011; 1(2); 27-30.
3. P Diogo et al. Sciatic nerve high division: Two different anatomical variants, Acta Med Port, 2013; 26(3): 208-211.
4. Brooks JBB, Silva CAC, Soares SA, Kai MR, Cabral RH, Fragosa YD. Anatomical variations of the sciatic nerve in a group of Brazilian cadaver. Rev dor, 2011;12(4):332-336.
5. Smoll NR. Variations of the piriformis and sciatic nerve with clinical consequence: A review. Clin Anat 2010; 23(1):8-17.
6. N Konstantinos, et al. Anatomical variations between the sciatic nerve and the piriformis muscle: A contribution to surgical anatomy in piriformis syndrome. Radiol Anat, 2014; 36(3):273-280.
7. S Saritha, et al. Anatomical variations in the bifurcation of sciatic nerve a cadaveric study and its clinical implications. Anat Physiol 2012; 2(5): 1-4.
8. K Muthu, Srimathi, R Ananda, L Sumathi. A cadaveric study of sciatic nerve and its level of bifurcation. JCDR;2011; 5(8); 1502-4.

DOI: 10.5455/2320-6012.ijrms201411114

Cite this article as: Shwetha K, Dakshayani KR. Bilateral high division of sciatic nerve. Int J Res Med Sci 2014;2:1785-7.