

## Original Research Article

# Clinical significance of presence of accessory foramen transversarium in typical cervical vertebrae

Esakkiammal N.\*, Renu Chauhan

Department of Anatomy, University College of Medical Sciences, Delhi, India

**Received:** 04 September 2016

**Revised:** 14 September 2016

**Accepted:** 06 October 2016

**\*Correspondence:**

Dr. Esakkiammal N.,

E-mail: [esakki510@gmail.com](mailto:esakki510@gmail.com)

**Copyright:** © the author(s), publisher and licensee Medip Academy. This is an open-access article distributed under the terms of the Creative Commons Attribution Non-Commercial License, which permits unrestricted non-commercial use, distribution, and reproduction in any medium, provided the original work is properly cited.

### ABSTRACT

**Background:** The cervical vertebrae are smallest of all the vertebrae present in the vertebral column. It is characterized by a foramen in each transverse process. The foramen transversarium (FT) of 6<sup>th</sup> to 1<sup>st</sup> cervical vertebrae transmits vertebral vessels and sympathetic nerves. Presence of another foramen apart from FT in the transverse process of cervical vertebrae is called accessory FT. Anatomical knowledge of these variations are helpful for conducting cervical spinal surgeries by the surgeons in order to prevent injury to vertebral vessels and sympathetic nerves.

**Methods:** The present study was conducted in the department of anatomy, UCMS and GTB Hospital, Delhi, India. A total number of 241 dried cervical vertebrae were collected from the bone bank of the Department of Anatomy. Presence of any variation from the normal anatomy of the cervical vertebrae were noted and photographed.

**Results:** Out of 241 cervical vertebrae (typical and atypical), the accessory FT was noted in typical cervical vertebrae only. Accessory FT was seen in 37 (27.6%) vertebrae, out of 134 typical cervical vertebrae. These accessory FT were either bilateral complete in 4 (2.9%) or incomplete 9 (6.7%) or unilateral complete 6 (4.5%) and unilateral incomplete 12 (8.9%) were observed. Six (4.5%) typical cervical vertebrae showed presence of complete accessory FT on one side and incomplete accessory FT on the other side in the same vertebra.

**Conclusions:** Knowledge of variations of the presence of accessory FT in the typical cervical vertebrae is not only important to anatomist but also to radiologist in identifying the presence of duplicate vertebral artery and hence helping the neuro surgeons in preventing accidental bleeding from the vertebral artery while performing surgery on the cervical spine.

**Keywords:** Accessory foramen transversarium, Foramen transversarium, Typical cervical vertebrae, Variations in foramen transversarium

### INTRODUCTION

The foramen transversarium (FT) is a typical feature of cervical vertebrae. Both typical and atypical cervical vertebrae have FT. The presence of FT differentiates cervical vertebrae from other vertebrae. The FT of 6<sup>th</sup> to 1<sup>st</sup> cervical vertebrae transmits the 2<sup>nd</sup> part of the vertebral artery, vertebral veins, and sympathetic nerves from inferior cervical ganglion.<sup>1</sup> Presence of another

foramen apart from FT in the transverse process of cervical vertebrae is called accessory FT which is smaller in size than the primary foramen. Generally, it is found in the sixth cervical vertebra and less frequently in other typical cervical and 7<sup>th</sup> cervical vertebrae.<sup>2</sup> This accessory FT lies posterior to the normal FT. Any variation in the FT may affect the course of vertebral artery and may cause serious complications like vertebrobasilar insufficiency.<sup>3</sup> Under such circumstances, the course of

the vertebral artery may be distorted. The variations in number and size of FT may be one of the causes for complaints like headache, migraine and fainting attacks. These symptoms may be due to the compression of vertebral artery.<sup>4</sup> Understanding the surgical anatomy of cervical spine is essential while performing complex surgical procedures on cervical spine.<sup>5</sup>

This importance of awareness of frequency of occurrence of accessory FT leads us to conduct the present study. Therefore, 134 typical cervical vertebrae were studied to see the presence of accessory FT.

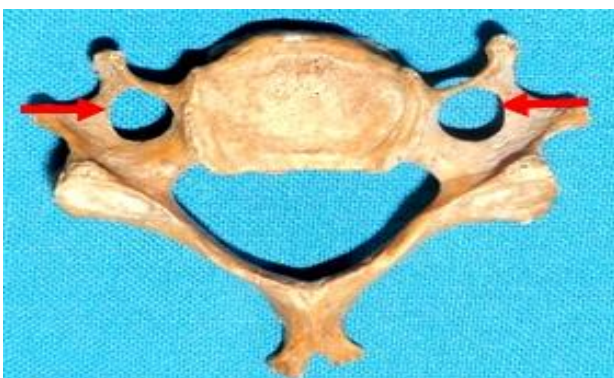The knowledge of presence of accessory FT and its variations is important not only to the clinicians while diagnosing a patient presenting with history of frequent headaches, migraine or fainting attacks but also to the radiologists in interpreting X- ray and CT scans.<sup>6</sup> The variations and clinical importance of accessory FT has been discussed in this paper.

**METHODS**

The present study was conducted in the department of anatomy, UCMS and GTB Hospital, Delhi, India. A total number of 241 dried cervical vertebrae of unknown age and sex were collected from the bone bank of the Department of Anatomy. Amongst them, 107 were atypical i.e. C1, C2 and C7 and 134 were typical cervical vertebrae i.e. C3 - C6. Grossly, all the cervical vertebrae were examined thoroughly. Presence of any variation from the normal anatomy of the cervical vertebrae were noted and photographed.

**RESULTS**

Out of the 241 cervical vertebrae which included typical and atypical cervical vertebrae, presence of accessory FT was noted in typical cervical vertebrae only. Therefore only 134 typical cervical vertebrae were considered. Out of this 97 typical cervical vertebrae showed normal FT (Figure 1).

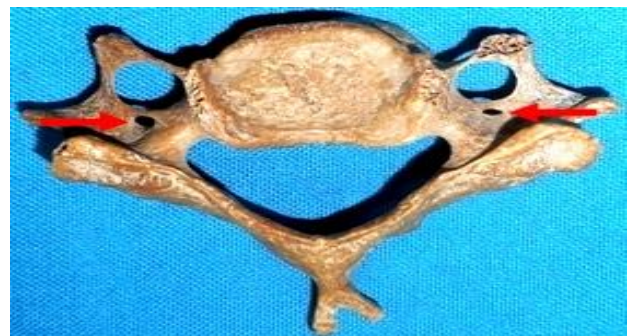

**Figure 1: Superior aspect of normal typical cervical vertebra showing arrows pointing at foramen transversarium (FT).**

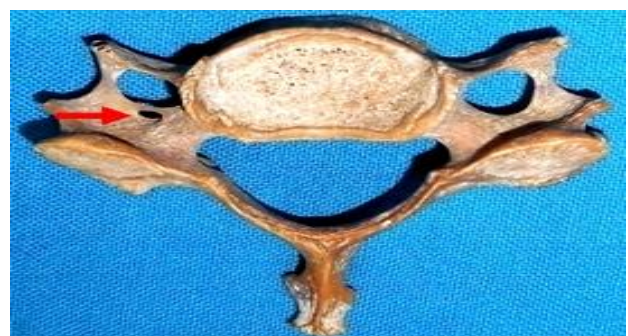Accessory FT was seen in 37 (27.6%) typical cervical vertebrae (Figure 2-9) (Table 1). Among this bilateral complete accessory FT was observed in 4 (2.9%) typical cervical vertebrae (Figure 2).

**Table 1: Presence of different varieties of accessory FT in a typical cervical vertebra in the present study.**

Type of accessory FT	Typical cervical vertebrae with presence accessory FT (n=134)	Accessory FT %
Bilateral complete	4	2.9
Unilateral complete	9 Left : Right, 6 : 3	6.7
Bilateral incomplete	6	4.5
Unilateral incomplete	12 Left : Right, 9 : 3	8.9
Both unilateral complete & unilateral incomplete	6	4.5



**Figure 2: Superior aspect of typical cervical vertebra showing arrows pointing at complete accessory FT present bilaterally.**



**Figure 3: A typical cervical vertebra from the superior aspect. Arrow pointing at left sided unilateral complete accessory FT.**

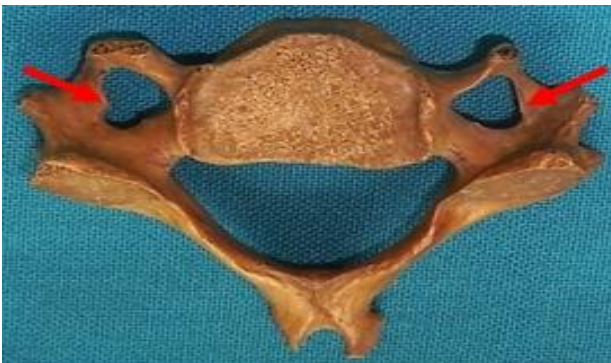Out of the total typical cervical vertebrae (134) examined, 9 (6.7%) of them showed presence of unilateral complete accessory FT. Six (4.5%) were present on the left side

and 3 (2.2%) on the right side (Figure 3 and 4). Bilateral incomplete accessory FT was seen in 6 (4.5%) of the total number of typical cervical vertebrae (Figure 5).



**Figure 4: A typical cervical vertebra from the superior aspect. Arrow pointing at unilateral complete accessory FT on the right side.**

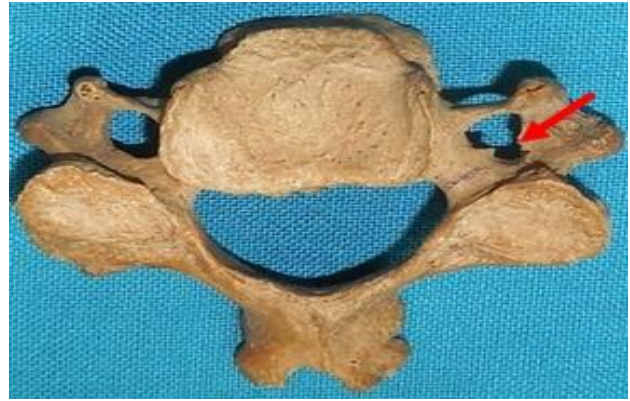Unilateral incomplete accessory FT was observed only in 12 (8.9%) typical cervical vertebrae. Out of this, 9 (6.7%) typical cervical vertebrae had unilateral incomplete accessory FT on the left side (Figure 6) and 3 (2.2%) on the right side (Figure 7).



**Figure 5: Superior aspect of a typical cervical vertebra. Arrows pointing at incomplete accessory FT present bilaterally.**

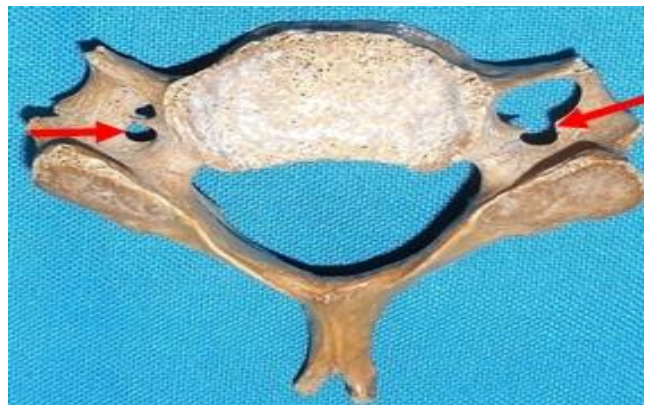

**Figure 6: Arrow pointing at left sided incomplete accessory FT in a typical cervical vertebra as seen from the superior aspect.**



**Figure 7: Arrow pointing at right sided incomplete accessory FT in a typical cervical vertebra as seen from the superior aspect.**

In the same typical cervical vertebra, 6 (4.5%) vertebrae showed presence of complete accessory FT on one side and incomplete accessory FT on the other side. Two (1.5%) vertebrae had complete accessory FT on left side and an incomplete on right side (Figure 8) and 4 (2.9%) vertebrae had incomplete accessory FT on left side while complete on right side (Figure 9).



**Figure 8: Superior aspect of typical cervical vertebra showing presence of complete accessory FT on the left side and incomplete accessory FT on the right side.**



**Figure 9: Superior aspect of typical cervical vertebra showing presence of incomplete accessory FT on the left side and complete accessory FT on the right side.**

**DISCUSSION**

Among all the various population groups studied type II Presence of FT in cervical vertebra is a result of the special formation of the cervical transverse processes. It is formed by the costal element fused to the body and the true transverse process of the vertebra. Anatomically, the transverse foramen is described to be divided by a fibrous or bony ridge separating the artery and the vein.<sup>7</sup> Double transverse foramina could mean duplication of vertebral artery.<sup>8</sup>

Embryologically, the vertebral artery is developed from the fusion of the longitudinal anastomosis that link the cervical inter segmental arteries which branch off from the dorsal division of somatic inter segmental artery in region of neck. These inter segmental arteries eventually regress except for the seventh artery which forms the proximal portion of the subclavian artery and the beginning of vertebral arteries.<sup>9</sup> Sim et al described that sometimes there occurs failure of the controlled regression of this portion of the primitive dorsal aorta along with the two inter segmental arteries which leads to the double origin and duplication of the vertebral arteries.<sup>10</sup> The bilateral occurrence of these failures is the reason behind the bilateral duplication of the vertebral arteries. The vertebral vessels are responsible for the formation of the transverse foramen. It can be assumed that variations in the course of vertebral vessels will cause variations in the transverse foramen.<sup>11</sup>

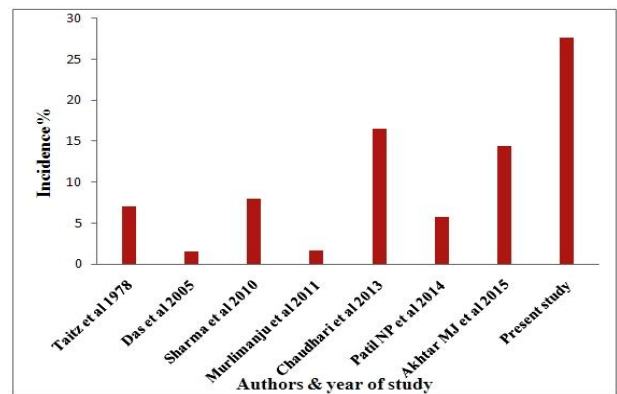
Many authors have reported anatomical variations in FT of cervical vertebrae previously (Table 2). Taitz et al studied 480 dried cervical vertebrae and found accessory FT in 34 (7%) cervical vertebrae.<sup>11</sup> In 2005, Das S et al examined 132 dried cervical vertebrae and reported accessory FT to be present only in 2 (1.5%) of them.<sup>6</sup> Accessory FT was observed in only 16 (8%) cervical vertebrae out of 200 cervical vertebrae studied by Sharma et al. They reported that the accessory FT was more commonly found in C6 vertebrae according to their study.<sup>12</sup>

**Table 2: Comparison of presence of accessory FT in typical and atypical cervical vertebrae (Between previous studies and the current study).**

Study conducted by various authors	Total number of cervical vertebrae	Presence of accessory FT in cervical vertebrae
Taitz et al <sup>11</sup>	480	34
Das et al <sup>6</sup>	132	2
Sharma et al <sup>12</sup>	200	16
Murlimanju et al <sup>13</sup>	363	6
Chaudhari et al <sup>14</sup>	133	22
Patil NP et al <sup>15</sup>	175	10
Akhtar et al <sup>16</sup>	174	25
Present study	241	37

Murlimanju et al studied 363 cervical vertebrae and found accessory FT amongst 6 (1.6%) vertebrae only. Of these cervical vertebrae, 5 (1.4%) had unilateral accessory FT and 1 (0.3%) had bilateral.<sup>13</sup> Chaudhari et al studied 133 cervical vertebrae and noticed accessory FT in 22 (16.5%) vertebrae of them. Unilateral accessory FT was present in 14 (14.73%) and bilateral accessory FT was present in 8 (8.42%) of these cervical vertebrae.<sup>14</sup> Patil NP et al observed 175 cervical vertebrae and found accessory FT only in 10 (5.71%) vertebrae. Of these 6 (3.42%) were unilateral and 4 (2.28%) were bilateral. According to them unilateral accessory FT was more common than bilateral. Also, that accessory FT was more common in lower cervical vertebrae i.e. from C4-C7.<sup>15</sup>

Akhtar et al conducted study on 174 cervical vertebrae and found 25 (14.4%) cervical vertebrae had accessory FT. amongst these, accessory FT was present unilaterally in 20 (11.5%) and bilaterally in 5 (2.9%) cervical vertebrae.<sup>16</sup> In the recent study, 134 typical cervical vertebrae were examined and accessory FT was found only in 37 (27.6%) vertebrae. In the present study, unilateral accessory FT was seen more commonly which is consistent with the study of previous authors. Accessory FT was seen only in typical cervical vertebrae in the current study. This is not in accordance to the previous studies which reported accessory FT to be present both in typical and atypical cervical vertebrae. Accessory FT was found more often in the present study as compared to that seen in studies conducted by various authors (Figure 10).



**Figure 10: Bar diagram depicting comparison between incidence of accessory FT as seen by various authors and the present study.**

Mishra et al studied 220 typical cervical vertebrae and found 31(14.09%) vertebrae had accessory FT. Out of these, 18 (8.1%) were bilateral complete, 6 (2.7%) were unilateral complete, 3 (1.3%) were bilateral incomplete and 4 (1.8%) were unilateral incomplete accessory FT.<sup>17</sup> Accessory FT in the typical cervical vertebrae were seen only in 37 (27.6%) vertebrae in the present study. Out of these, 4 (2.9%) were bilateral complete, 9 (6.7%) were unilateral complete, 6 (4.5%) were bilateral incomplete and 12 (8.9%) were unilateral incomplete. The incidence

of presence of accessory FT in typical cervical vertebrae were similar to that reported by Mishra et al, however, according to them accessory FT was more frequent bilaterally. On the contrary, accessory FT was more frequently seen unilaterally in the present study. Both

complete and incomplete accessory FT in the same typical cervical vertebrae was found only in 6 (4.5%) vertebrae in the current study. This finding has not been seen in the study conducted by Mishra et al (Table 3) (Figure 11).

**Table 3: Incidence of accessory FT present in typical cervical vertebrae – Mishra et al study vs Present study.**

Authors	Bilateral complete accessory FT	Unilateral complete accessory FT	Bilateral incomplete accessory FT	Unilateral incomplete accessory FT	Both complete & incomplete accessory FT	% of accessory FT in typical cervical vertebrae
Mishra et al <sup>17</sup>	18	6	3	4	Not seen	14.09
Present study	4	9	6	12	6	27.6

Double FT may be correlated by the presence of duplicate vertebral arteries.<sup>8-11,13,18,19</sup> Absence of FT could mean absence of the vertebral artery.<sup>11</sup> A duplicate vertebral artery may potentially serve to protect patients against ischemic attacks to the brain and provide collateral blood flow to the basilar artery. Fenestrated double vertebral arteries may carry more risk of thrombus formation and embolization leading to severe transient ischemic attacks.<sup>18</sup> Fenestrated vertebral arteries have been demonstrated histologically to be weak with irregular elastic fibers in the vessel wall.<sup>9,19</sup> Compression of vertebral artery will not only lead to neurological symptoms but also to hearing disturbances.<sup>19</sup>

accessory FT in typical cervical vertebrae will be helpful to both radiologists and neurosurgeons in preventing vascular catastrophe due to accidental damage of vertebral artery.

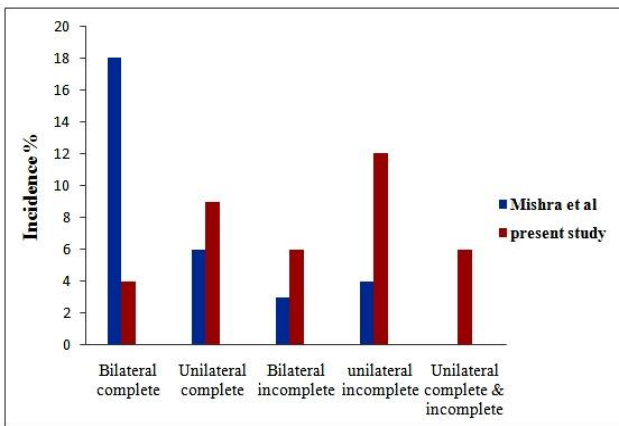
**CONCLUSION**

Only typical cervical vertebrae showed the presence of 27.6% of accessory FT in the present study. Accessory FT was present more often unilaterally on the left side of the vertebra. Embryologically, presence of accessory FT could be due to developmental variations in the vertebral artery. Knowledge of variations of the presence of accessory FT in the typical cervical vertebrae is not only important to anatomist but also to radiologist in identifying the presence of duplicate vertebral artery and hence helping the neuro surgeons in preventing accidental bleeding from the vertebral artery while performing surgery on the cervical spine.

*Funding: No funding sources*

*Conflict of interest: None declared*

*Ethical approval: The study was approved by the Institutional Ethics Committee*



**Figure 11: Bar diagram depicting comparison between the study of Mishra et al and present study for the presence of various kinds of accessory FT in typical cervical vertebrae.**

Maintaining the vertebral artery intact constitutes an important concern to neuro surgeons while performing surgeries on the cervical spine since minor accidental damage to vertebral artery can lead to grave consequences and even death.<sup>11</sup> Hence, the knowledge of all kind of variations in the anatomy and morphology of

**REFERENCES**

- Rosse C, Gaddum Rosse P. The vertebral column. Hollinshead’s Text Book of Anatomy. 5<sup>th</sup> ed. Philadelphia: Lippincott Raven. 1997:117.
- Bergman RA, Thompson SA, Afifi AK, Saadeh FA. Compendium of Human Anatomic Variation. Germany: Urban and Schwarzenberg. 1988:197.
- Kaya S, Yilmaz ND, Pusat S, Kural C, Kirik A, Izci Y. Double foramen transversarium variation in ancient Byzantine cervical vertebrae: Preliminary report of an anthropological study. Turk Neurosurg. 2011;21:534-8.
- Caovilla HH, Gananca MM, Munhoz MS, Silva ML, Gananca FF, Silva ML, et al. Syndrome

- cervical. *Quadros Clinicos Otoneurologicos Mais Comuns.* Sao Paulo. Atheneu. 2000:95-100.
5. Bridwell KH, Anderson PA, Boden SD, Vaccaro AR, Wang J. What's new in spine surgery? *J Bone Joint Surg Am.* 2008;90:1609-19.
  6. Das S, Suri R, Kapur V. Double foramen transversaria. An osteological study with clinical implications. *Int Med J.* 2005;12:311-3.
  7. Standring S. *Gray's Anatomy, The Anatomical Basis of Clinical Practice.* 39th Ed. Spain: Elsevier Churchill Livingstone; 2005. Chapter 45, The Back. 743.
  8. Shah TS. Study of accessory foramen transversarium in cervical vertebrae. *GCSMC J Med Sci.* 2014;3(2):21-4.
  9. Ionete C, Omojola MF. MR angiographic demonstration of bilateral duplication of the extracranial vertebral artery: Unusual course and review of the literature. *AJNR.* 2006;27:1304-6.
  10. Sim E, Vaccaro AR, Berzlanovich A, Thaler H, Ullrich CG. Fenestration of the extracranial vertebral artery: Review of the literature. *Spine.* 2001;26:139-42.
  11. Taitz C. Anatomical observations of the foramina transversaria. *J Neurol Neurosurg Psychiatry.* 1978;41(2);19:170-6.
  12. Sharma A, Singh K, Gupta V, Srivastava S. Double foramen transversarium in cervical vertebra an osteological study. *J Anat Soc India.* 2010;59(2):229-31.
  13. Murlimanju BV, Prabhu LV, Shilpa K, Rai R, Dhananjaya KVN, Jiji PJ. Accessory transverse foramina in the cervical spine: incidence, embryological basis, morphology and surgical importance. *Turk Neurosurg.* 2011;21(3):384-7.
  14. Chaudhari ML, Maheria PB, Bachuwar SP. Double foramen transversarium in cervical vertebra. Morphology and clinical importance. *Indian J Basic Appl Med Res.* 2013; 8(2):1084-8.
  15. Patil NP, Dhapate SS, Porwal S, Bhagwat VB. The study of incidence of accessory foramen transversaria in the cervical vertebra. *J Dent Med Sci.* 2014;13(7):85-7.
  16. Akhtar MJ, Madhukar PK, Rahman S, Kashyap N. A morphometric study of foramen transversarium of dried cervical vertebrae. *Int J Res Med Sci.* 2015;3:912-6.
  17. Mishra GP, Kumari S, Bhatnagar S, Singh B. Sixth cervical vertebra with bilateral double foramen transversarium and non-bifid spine: a rare case. *Int J Res Med Sci.* 2015;3(1):352-3.
  18. Malik SW, Stemper BD, Metkar U, Yoganandan N, Shender BS, Rao RD. Location of the transverse foramen in the subaxial cervical spine in a young asymptomatic population. *Spine.* 2010;35(12):E514-9.
  19. Romanov VA, Miller LG, Gaevyĭ MD. The effect of the vertebral nerve on circulation in the inner ear (cochlea). *Biull Eksp Biol Med.* 1973;75:10-2.

**Cite this article as:** Esakkiammal N, Chauhan R. Clinical significance of presence of accessory foramen transversarium in typical cervical vertebrae. *Int J Res Med Sci* 2016;4:5231-6.