

## Original Research Article

# Study of safety and efficacy of autologous platelet rich plasma combined with fractional CO<sub>2</sub> laser in the treatment of post acne scars: a comparative simultaneous split-face study

Sidhartha D. Shah\*, Bipin D. Mehta, Milind A. Borkar, Reshma C. Aswani

Department of Dermatology, NKP Salve Institute of Medical Science and Research Center, Nagpur, Maharashtra, India

**Received:** 01 March 2017

**Accepted:** 14 March 2017

**\*Correspondence:**

Dr. Sidhartha D. Shah,

E-mail: Sidd\_d\_s@yahoo.co.in

**Copyright:** © the author(s), publisher and licensee Medip Academy. This is an open-access article distributed under the terms of the Creative Commons Attribution Non-Commercial License, which permits unrestricted non-commercial use, distribution, and reproduction in any medium, provided the original work is properly cited.

### ABSTRACT

**Background:** Many treatments are available for treating post acne scars but optimized treatment does not exist still. Hence, this study was conducted with the aim to evaluate the safety and efficacy of autologous platelet rich plasma combined with fractional CO<sub>2</sub> laser for treatment of acne scars when used in Indian skin.

**Methods:** Thirty patients attended to the Dermatology OPD were enrolled in the study after meeting inclusion criteria. They underwent split-face therapy. They received ablative fractional carbon dioxide (CO<sub>2</sub>) laser combined with autologous platelet-rich plasma (PRP) treatment on one half of their face and ablative fractional CO<sub>2</sub> laser with intradermal normal saline on the other half. The injections were administered immediately after laser therapy. Each participant received 4 treatments spaced by 1 month and were followed up for a period of 4 months.

**Results:** The outcome among the study subjects were assessed using Goodman and Baron Scale at different time intervals. Significant reduction in acne scars was observed in both PRP injection site and normal saline injection site but better reduction of acne scars was noted at the PRP site. The blinded physician's assessment and patient satisfaction was better at PRP injected side as compared to the normal saline injected side. The incidence of adverse effects and pain during the procedure was significantly lower in PRP injected side compared normal saline injected side.

**Conclusions:** This study demonstrated that PRP should be considered as an adjuvant therapeutic option for dermatologic procedures such as fractional CO<sub>2</sub> laser resurfacing for treatment of post acne scars as it might have additional benefit of reducing the adverse effects such as persistent erythema and edema.

**Keywords:** Acne scars, Adverse effects Autologus PRP, Fractional CO<sub>2</sub> laser

### INTRODUCTION

Acne vulgaris is a common chronic inflammatory disorder of pilosebaceous unit affecting adolescents and young adults psychologically. Untreated acne especially the inflammatory type results in often distressing and difficult to treat scars. Acne scar formation results either due to increased tissue formation or damage of local tissue.<sup>1</sup> The severity of scarring depends upon degree of

tissue damage, inflammatory reaction and time lapsed from the onset of tissue inflammation.<sup>2,3</sup> Severe scarring affected by acne is associated with psychological distress, particularly in young adults, and often results in decreased self-confidence and diminished quality of life.<sup>4</sup>

Various modalities shown in literature for the treatment of acne scars include predominantly physical modalities and surgical modalities like chemical peeling,

dermabrasion, subcision, tissue augmentation using fillers, punch excision, punch elevation and ablative and non-ablative laser techniques.<sup>3</sup>

In fact, facial resurfacing with fractional CO<sub>2</sub> lasers currently appears to be one of the most valuable treatment for facial scars.<sup>5</sup> The improvement in appearance of acne scars following fractional CO<sub>2</sub> laser is due to the combination of processes of healing that initiates new collagen deposition after ablation (called the vertical effect) and collagen remodelling initiated by the zone of coagulation surrounding the ablated area (call the horizontal effect).<sup>6</sup> Regardless of its efficiency in treating post acne scars, its use had some limitations like post-inflammatory hyperpigmentation, long procedure time etc.

Autologous platelet rich plasma (PRP) has become popular now-a-days in the field of plastic surgery and dermatology for scar restoration.<sup>7-11</sup> PRP releases platelet derived growth factors and regenerates damaged bone and soft tissue.<sup>12-15</sup> In this aspect, we hypothesized that because of its regenerative properties PRP may reduce the post acne scars when combined with fractional CO<sub>2</sub> lasers and minimize the post procedural adverse effects.

This study is aimed to evaluate the safety and efficacy of autologous PRP combined with fractional CO<sub>2</sub> laser for treatment of acne scars when used in Indian skin.

**METHODS**

Thirty subjects with moderate to severe atrophic facial acne scars presenting to Dermatology OPD of NKP Salve institute of medical science and research centre and Lata Mangeshkar Hospital Nagpur, Maharashtra, India between November 2014 and May 2016 were enrolled in the study. Grade of post- acne scarring was assessed with a qualitative scarring grading system by Goodman and Baron, The Global Acne Scarring Classification.<sup>16</sup>

After getting approval from the institutional ethical committee, written informed consent was obtained from all participants before enrolment.

**Inclusion criteria**

Patients willing to participate in the study, patients with moderate to severe facial atrophic acne scar (grade 2-4 on the Global Acne Scarring Classification) attending the Dermatology OPD, patients between the age of 18-45 years.

**Exclusion criteria**

Patients with active acne, predisposition to keloid formation, patients with active herpes infection, pregnant and lactating mothers, patients who have taken isotretinoin within previous 6 months, patients with

unreasonably high expectations, bleeding diathesis, HIV, HBV infection.

**Sample size calculation**

The sample size of the current study was calculated to be 30 patients. The calculation done using Open Epiby taking the data of a reference study.<sup>7</sup> The confidence limit (1 - α) was fixed at 95% and power of the study (1 - β) was set at 80%.

The formula used to calculate the sample size was:

$$N = [(Z_{\alpha/2} + Z_{\beta})^2 \times 2\sigma^2] (\mu_1 - \mu_2)^2$$

Where n = sample size required in each group; μ<sub>1</sub> - μ<sub>2</sub> = statistically significant difference between CO<sub>2</sub> + PRP group and CO<sub>2</sub> group; σ = standard deviation; Z<sub>α/2</sub> = 1.96; Z<sub>β</sub> = 0.84.

The sample size calculated was 30.

**Study intervention**

Digital photographs of all patient’s face were taken before and 4 weeks after procedure. Before procedure, all treatment areas were gently cleansed and a topical anesthetic cream was applied for 45 minutes. Each patient entire face was treated with Unixel Geosmatic fractional CO<sub>2</sub> laser (10600 nm). After 5 days of fractional CO<sub>2</sub> laser resurfacing, facial halves were randomly assigned to receive treatment with autologous PRP on one side and normal saline on other side. Each participant received 4 treatments spaced by 1 month and were followed up for a period of 4 months. In each treatment session, the following fractional CO<sub>2</sub> laser settings were used as given in Table 1. After CO<sub>2</sub> laser was done, patients were advised to apply non-occlusive moisturizer 6 hourly for the first 5 days.

**Table 1: Fractional CO<sub>2</sub> laser settings.**

Parameters	Area	
	Scarred area	Unaffected area
Level	12 (2.5 W)	13 (2.5 W)
Points of shot	3 (pulse stacking)	1 (pulse stacking)
Pulse width	400 μs	400 μs
Beam diameter	70 μm	70 μm
Density	144 M T Z/cm <sup>2</sup>	99 M T Z/cm <sup>2</sup>
Pitch Mode	0.9 × 0.9 mm Random	0.9 × 0.9 mm Random
Energy	0.432 J/cm <sup>2</sup>	0.099 J/cm <sup>2</sup>

**Preparation of PRP injection**

Under aseptic precautions, required amount patient’s blood sample was collected from antecubital vein in a

vacutainer containing anticoagulant sodium citrate in 1:9 ratio. Collected blood was subjected to centrifugation using REMI 8 C. First spin was done at the speed of 1500 revolutions per minute (RPM) for 6 minutes. After first spin, we identified three layers as plasma, buffy coat and red cell clot at bottom. Supernatant fluid which is plasma without platelets was aspirated with the help of tuberculin syringe. Buffy coat along with remaining portion was collected with help of Finn pipette and transferred to another test tube. A second spin of 2500 RPM for 15 minutes was done leading to settlement of platelets at the bottom.

After second spin, plasma was taken out. Remaining portion of plasma containing platelets (platelet rich plasma) was taken in a tuberculin syringe containing calcium chloride (CaCl<sub>2</sub>). Ration was maintained at 1 part CaCl<sub>2</sub> and 9 part PRP. Calcium chloride was the activator for platelets. Application site on face was prepared with betadine and spirit. Using tuberculin syringe, a volume of 3 cc PRP was injected at each site of post acne scar. Patients were asked to report if any adverse reactions that they may experience after the injections.

After the ablative CO<sub>2</sub> laser resurfacing treatment, each patient was administered autologous platelet-rich plasma on one half of the face (selected randomly) and normal saline was administered on the other half. Injection sites were located within 2 cm intervals to receive 0.3 ml platelet-rich plasma or normal saline. Afterwards, the participants were required to compress their faces with gauze for 15 min before leaving.

All patients were asked to avoid direct sun exposure, heat and friction on the treated areas. They were advised to apply sunscreen of sun protection factor (SPF) 30. One month after the initial treatment session, all participants received the second treatment session with the same protocol.

#### **Patient assessment**

Participants were required to undergo serial photography of the lesions at baseline and after each treatment session (one month apart), using a digital camera. Camera setting, lighting and positioning were kept identical for all serial photographs. A quartile grading scale: poor, <25% improvement; fair, 25-50% improvement; good, 51-75% improvement and excellent, >75% improvement was used by two blinded dermatologists (who did not perform the procedures) to evaluate the overall clinical improvement.

Each participant was instructed to evaluate his/her scar severity after the last treatment on a scale of 1–10 where 1 is least severe and 10 being most severe. Adverse events recorded were persistent erythema, edema, post-inflammatory hyperpigmentation and pain as perceived by participants after treatment. Finally, the occurrence of other possible side adverse events including secondary infection, acneiform eruption, dyschromia and new scar formation was assessed by a blinded dermatologist. Scoring of acne scars was done on basis of Goodman and Baron's quantitative global acne scarring grading system as shown in Table 2.

**Table 2: Goodman and Baron quantitative global scarring grading system.**

Grade	Number of lesions		
	1-10	11-20	>20
A Mild scarring (1 point each) Macular erythematous, pigmented, mildly atrophic dish like	1 point	2 points	3 points
B Moderate scarring (2 point each) Punched out small scars with, shallow bases (<5mm width), Shallow but broad atrophic scars	2 points	4 points	6 points
C Severe scarring (3 points each) Punched out scars with deep but normal bases, small scars (<5mm), Punched out scars with deep but abnormal bases, small scars (<5mm), Linear or troughed dermal scarring, Deep and broad atrophic scars	3 points	6 points	9 points
D Hyperplastic papular scars	2 points	4 points	6 points
E Hypertrophic keloidal/hypertrophic scars	Area <5cm <sup>2</sup> 6 points	Area 5-20 cm <sup>2</sup> 12 points	Area >20cm <sup>2</sup> 18 points

#### **Statistical analysis**

Statistical tool used was R VERSION 3.2. Scoring of acne scars were checked for normality using Shapiro-Wilk test and were found to be non-normally distributed

(p-value <0.05). Hence, the non-parametric equivalent of paired and unpaired t-test were applied i.e. Wilcox Signed Rank Test for paired data and Mann-Whitney U - Test for unpaired data.

**RESULTS**

In the present study, a total of 30 patients were enrolled in the study. Table 1 presents the characteristics of the study participants. The mean age of the patients was 24.7±3.44 years with the minimum age 19 years and the maximum age was 35 years. It was observed that majority of the study subjects belong to the age group 20-24 years (46.67%) followed by 25-29 years of age (40%). Male: Female ratio was 3:2. Majority of the study subjects belonged to an urban background (76.67%) and 23.33% belonged to a rural background. According to Goodman and Baron acne scar grading scale, 9 (30%) cases were presented with Grade II (moderate), 13 patients (43.3%) presented with Grade III (severe) and 8 patients (26.7%) presented with Grade IV (hyperplastic) on both sides of face.

**Treatment outcome**

The outcome among the study subjects were assessed using Goodman and Baron Scale at different time intervals- baseline, at the end of 1 month, at the end of 2 months, at the end of 3 months and at the end of 4 months. In this study, each side of the face is considered into each group. It was observed that there was

significant reduction in acne scars in both PRP injection site (mean Goodman and Baron grading was 14.83 at baseline and 4.2 at 4 months) and normal saline injection site (mean Goodman and Baron grading was 15.23 at baseline and 7.5 at 4 months) as given in Table 4.

**Table 3: Summary of the patient’s characteristics.**

Characteristics	No. of patients	Percentage
<b>Age</b>		
18-20	2	6.67
20-24	14	46.67
25-29	12	40
30-45	2	6.67
<b>Gender</b>		
Male	18	60
Female	12	40
<b>Residence</b>		
Rural	7	23.3
Urban	23	76.67
<b>Acne scar grading in number of patient sat baseline on both sides of face</b>		
Moderate	9	30
Severe	13	43.3
Hyperplastic	8	26.7

**Table 4: Comparison of reduction of acne scar according to Goodman and Baron quantitative scale at baseline and 4 months after treatment.**

Time interval	N	Mean±SD	W-statistic	p-value
Base line	30	14.83±4.28	15.23±4.28	9100.5
1 <sup>st</sup> month	30	12.43±4.02	13.57±4.05	0.004156
2 <sup>nd</sup> month	30	9.4±4.06	11.8±3.86	
3 <sup>rd</sup> month	30	7.9±3.36	9.53±3.67	
4 <sup>th</sup> month	30	4.21±2.57	7.5±3.32	

**Physician’s assessment**

Physician’s assessment was done by two blinded dermatologists using digital photographs. Improvement was noted on quartile scale where 0-25% was considered as mild improvement, 25-50% as moderate improvement, 50–75% as good improvement and 75-100% as excellent improvement.

14 treatment sites (23.33%) showed excellent response to treatment of which 10 belonged to PRP site and 4 belonged to normal saline site. Good improvement was seen in 19 treatment (31.67%) of which 12 were treated with PRP and 7 were treated with normal saline.

21 showed moderate improvement (35%) of which majority were normal saline sites (n = 14). Of the 6 sites

that had poor improvement, only 1 belonged to PRP treated site and the rest to normal saline treated sites as given in Table 5.

**Patient satisfaction based on scar severity**

Table 6 presents the patients satisfaction score before and after treatment. The mean patient satisfaction score at baseline in PRP and normal saline injection site was 4.9±1.54 and 5.2±1.71 respectively.

After treatment, the mean score was significantly lower in the PRP injection group (1.7±0.95) as compared to normal saline (2.5±1.17). Highly statistical significance was found (p-value <0.01) when Mann-Whitney U -Test was applied, suggesting that the patient satisfaction was better with PRP as compared to normal saline.

**Table 5: Improvement based on physician’s assessment.**

Physician’s Assessment	Treatment groups		Total	Fisher’s exact test, P value 0.03265
	FCL+PRP	FCL+Normal saline		
Mild improvement	1	5	6	0.03265
Moderate improvement	7	14	21	
Good improvement	12	7	19	
Excellent improvement	10	4	14	
Total	30	30	60	

**Table 6: Patient satisfaction at baseline and post treatment.**

Time Interval	N	Treatment groups		W - statistic	P value
		FCL+PRP	FCL+Normal saline		
Base line	30	4.9±1.54	5.2±1.71	276	0.0074
Post treatment	30	1.7±0.95	2.5±1.17		

**Adverse effects**

Table 7 presents the adverse effects of the treatment reported by the patients in both the groups. In the current study, all patients (100%) developed post laser transient erythema.

However, persistent erythema was seen in 11 patients (36.67%). 25 patients (83.33%) developed edema, 10 patients (33.33%) developed post-inflammatory hyperpigmentation (PIH), 11 patients (36.67%) developed acneiform eruptions. Higher proportion of

adverse effects was noted in the normal saline group as compared to the PRP group.

**Pain score**

Patients were evaluated for pain during procedure based on a VAS scale with a minimum score of 0 (no pain) to 10 (unbearable pain). The mean pain score during the procedure at both the sides was 4.82±1.32. The minimum VAS score of the patients was 1 and the maximum was 8. It was observed that pain during procedure was lesser at the PRP side (4.37±1.52) as compared to normal saline side (5.27±0.91).

**Table 7: Adverse effects among study population.**

Adverse effects		Treatment groups			P value
		FCL+PRP	FCL+Normal saline	Total	
Persistent erythema	Present	3	8	11	0.0453
	Absent	27	22	49	
Edema	Present	7	18	25	0.008829
	Absent	23	12	35	
Post-inflammatory hyperpigmentation	Present	4	6	10	0.729
	Absent	26	24	50	
Acneiform eruption	Present	3	8	11	0.182
	Absent	27	22	49	

**Table 8: Pain scores of the study population during procedure.**

Treatment group	N	Mean±SD	Independent Sample t-Test	P value
FCL+PRP	30	4.37±1.52	2.7853	0.0076
FCL+normal saline	30	5.27±0.91		

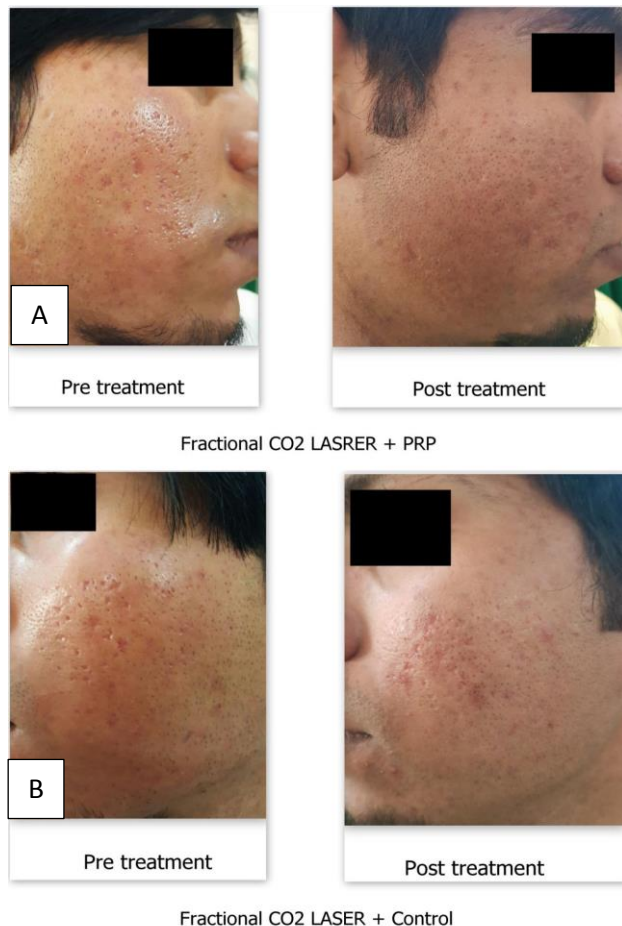
**DISCUSSION**

Post-acne scarring is a very distressing for the patient and difficult for dermatologists to treat. Several authors have

attempted to classify the acne scars but there is still no standardization for it. Historically the abrasive techniques have been commonly used to treat post-acne scarring with inconstant results.<sup>17</sup> However, newer techniques like

laser resurfacing and platelet rich plasma have gained popularity in recent years.

Fractional CO<sub>2</sub> laser resurfacing was developed to reduce the complications of conventional CO<sub>2</sub> laser resurfacing. But still some adverse effects like scarring and infection were observed if it is used alone.<sup>18</sup>



**Figure 1: a) shows pre and post treatment picture of fractional CO<sub>2</sub> laser + PRP side, b) shows pre and post treatment picture of fractional CO<sub>2</sub> laser + control side.**

Autologous PRP is the plasma portion of sourced blood with an iatrogenically high platelet concentration.<sup>19</sup> Many studies have suggested that PRP can reduce inflammation, postoperative blood loss and infection, in addition to accelerating osteogenesis and wound and soft tissue healing.<sup>20</sup>

The effectiveness of platelet-rich plasma combined with ablative 10,600 nm fractional CO<sub>2</sub> laser for the treatment of atrophic acne scars with reduced laser side effects, erythema and edema was reported in many studies.<sup>7</sup> In the present study good to excellent improvement was seen in 73% cases. In this study, the mean age of the study population was 24.7±3.44 years and majority of the study subjects were male. This was similar with the studies

done by Faghihi et al.<sup>21</sup> Also, 76% of the study population comes from an urban background which might be due to the common notion that acne scar as an urban condition. Though acne scar is seen in rural population it is seldom reported as a cause of distress to the patient. This coupled with better access to healthcare, quality services, increased self-awareness might explain the gap in the demographic.

In the current study, all the participants showed significant reduced acne scar scores in both the injection sites. However, there was better reduction of acne scars at the PRP site as compared to the normal saline site and the end of 4 months (p-value <0.0001). These results correlate with results of other studies who found that platelet-rich plasma used after fractional carbon dioxide resurfacing for acne scars had greater improvement in scarring in the presence of PRP.<sup>7,9</sup>

In the current study, the dermatologist's assessment found that there was significantly better improvement on the PRP side as compared to the normal saline side. These results are supported by Gadwat et al.<sup>9</sup> He found that the areas treated using the fractional CO<sub>2</sub> laser – autologous PRP combination showed significantly better results (p =0.03) about clinical improvement of skin smoothness as assessed by a blinded dermatologist on the 4-point scale than the area treated using fractional CO<sub>2</sub> laser alone.<sup>9</sup> This could be attributed to the synergistic effect of both modalities together, naturally giving this combination an advantage. PRP may actively correct atrophic scarring, which is a common sequel from loss of collagen and elastic fibres after inflammatory processes.

The present study shows that patients rated a significantly lower scar severity score on the PRP side (1.7±0.95) as compared to the normal saline treated side (2.5±1.17). The patient satisfaction was significantly better with PRP as compared to normal saline (p-value <0.05). Studies done by various other authors also found better patient satisfaction with PRP group as compared to normal saline group.<sup>7,9,22</sup>

The results of the study show that adverse effects such as persistent erythema and edema were significantly lower in PRP side as compared to the normal saline group. These observations were in accordance with the findings of Faghihi et al.<sup>22,23</sup>

These results verify that adjuvant PRP treatment may help promote the recovery of laser-damaged skin and decrease downtime. One of the earlier proposed mechanism of action for these observed effects may be the numerous growth factors present in PRP. Specifically, platelet-derived growth factor may help to stimulate the production of other growth factors important in tissue remodelling, promoting connective tissue healing by upregulating collagen and protein synthesis. Higher levels of transforming growth factor beta may also expedite tissue recovery through the up regulation of

cellular migration and proliferation, as well as by directly stimulating cell replication and fibronectin binding interactions. Insulin-like growth factor may also assist in the proliferation and migration of fibroblasts and increase collagen production. Although the effects of epithelial growth factor are limited to the basal layer of the epidermis, it also promotes cell differentiation and re-epithelialization.<sup>24</sup> These growth factors may enhance the recovery of laser-damaged skin and shorten the duration and degree of postoperative erythema, and edema.<sup>19,25,26</sup>

The current study did not find any difference in post-inflammatory hyper-pigmentation and acneiform eruptions in both the groups. However, our study found that pain during procedure was significantly lower in PRP side as compared to the normal saline side. Pain during procedure was lesser at the PRP side ( $4.37 \pm 1.52$ ) as compared to normal saline side ( $5.27 \pm 0.91$ ). Similar results were also seen in a study done by Shin et al in 2012, where the pain score was  $1.38 \pm 0.55$  for the fractional CO<sub>2</sub> laser treatment group and  $1.27 \pm 0.57$  for the combination treatment group. However, the authors did not find any significant difference between the groups.<sup>27</sup> The exact mechanism of pain relief by PRP is not known. However, the application of autologous PRP in pain management has been well-documented.<sup>27-29</sup> Infect, a study done by Mishra et al shows that PRP was superior to bupivacaine in pain relief for patients suffering from elbow tendinopathy.<sup>30</sup>

## CONCLUSION

In conclusion, our results show that PRP treatment after ablative CO<sub>2</sub> fractional resurfacing provides better overall clinical improvement and expedites the recovery of laser-damaged skin. We suggest that PRP should be considered as an adjuvant therapeutic option for dermatologic procedures such as fractional CO<sub>2</sub> laser resurfacing as it might have additional benefit of reducing the adverse effects such as persistent erythema and edema. Three or four sessions of combination treatments may be suitable for patients with moderate to severe acne which might significantly improve his or her quality of life.

*Funding: No funding sources*

*Conflict of interest: None declared*

*Ethical approval: The study was approved by the Institutional Ethics Committee*

## REFERENCES

- Rivera AE. Acne scarring: a review and current treatment modalities. *J Am Acad Dermatol.* 2008;59(4):659-76.
- Kadunc BV, de Almeida ART. Surgical treatment of facial acne scars based on morphologic classification: a brazilian experience. *Dermatol Surg.* 2003;29(12):1200-9.
- Dreno B, Khammari A, Orain N, Noray C, Merial-Kieny C, Mery S, et al. Ecce grading scale: an original validated acne scar grading scale for clinical practice in dermatology. *Dermatol.* 2006;214(1):46-51.
- Loney T, Standage M, Lewis S. Not just 'skin deep': Psychosocial effects of dermatological-related social anxiety in a sample of acne patients. *J Health Psychol.* 2008;13:47-54.
- Geronomus RG. Fractional photo-thermolysis: Current and future applications. *Lasers Surg Med.* 2006;38:169-76.
- Sardana K, Garg VK, Arora P, Khurana N. Histological validity and clinical evidence for use of fractional lasers for acne scars. *J Cutaneous Aesthetic Surg.* 2012;5(2):75.
- Lee JW, Kim BJ, Kim MN, Mun SK. The efficacy of autologous platelet rich plasma combined with ablative carbon dioxide fractional resurfacing for acne scars: A simultaneous split-face trial. *Dermatol Surg.* 2011;37:931-8.
- Cervelli V, Nicoli F, Spallone D, Verardi S, Sorge R, Nicoli M, et al. Treatment of traumatic scars using fat grafts mixed with platelet-rich plasma, and resurfacing of skin with the 1540 nm nonablative laser. *Clin Exp Dermatol.* 2012;37:55-61.
- Gawdat HI, Hegazy RA, Fawzy MM, Fathy M. Autologous platelet rich plasma: Topical versus intradermal after fractional ablative carbon dioxide laser treatment of atrophic acne scars. *Dermatol Surg.* 2014;40:152-61.
- Nita AC, Orzan OA, Filipescu M, Jianu D. Fat graft, laser CO<sub>2</sub> and platelet-rich-plasma synergy in scars treatment. *J Med Life.* 2013;6:430-3.
- Nofal E, Helmy A, Nofal A, Alakad R, Nasr M. Platelet-rich plasma versus CROSS technique with 100% trichloroacetic acid versus combined skin needling and platelet rich plasma in the treatment of atrophic acne scars: A comparative study. *Dermatol Surg.* 2014;40:864-73.
- Boswell SG, Cole BJ, Sundman EA, Karas V, Fortier LA. Platelet-rich plasma: A milieu of bioactive factors. *Arthroscopy.* 2012;28:429-39.
- Lacci KM, Dardik A. Platelet-rich plasma: Support for its use in wound healing. *Yale J Biol Med.* 2010;83:1-9.
- Cho JW, Kim SA, Lee KS. Platelet-rich plasma induces increased expression of G1 cell cycle regulators, type I collagen, and matrix metalloproteinase-1 in human skin fibroblasts. *Int J Mol Med.* 2012;29:32-6.
- Kim SA, Ryu HW, Lee KS, Cho JW. Application of platelet-rich plasma accelerates the wound healing process in acute and chronic ulcers through rapid migration and upregulation of cyclin A and CDK4 in HaCaT cells. *Mol Med Rep.* 2013;7:476-80.
- Goodman GJ, Baron JA. Postacne scarring—a quantitative global scarring grading system. *J Cosmetic Dermatol.* 2006;5(1):48–52.
- Sanchez FH. Treatment of Acne Scars, in *Dermatologic Surgery: Step by Step.* Oxford, UK: Wiley-Blackwell; 2012: 195–206.

18. Fife DJ, Fitzpatrick RE, Zachary CB. Complications of fractional CO<sub>2</sub> laser resurfacing: four cases. *Lasers Surgery Med.* 2009;41(3):179-84.
19. Eppley BL, Pietrzak WS, Blanton M. Platelet-rich plasma: a review of biology and applications in plastic surgery. *Plastic Reconstructive Surg.* 2006;118(6):147-59.
20. Smith RG, Gassmann CJ, Campbell MS. Platelet-rich Plasma: Properties and Clinical Applications. *J Lancaster General Hospital.* 2007;2(2):73-8.
21. Faghihi G, Nouraei S, Asilian A, Keyvan S, Abtahi-Naeini B, Rakhshanpour M, et al. Efficacy of punch elevation combined with fractional carbon dioxide laser resurfacing in facial atrophic acne scarring: A randomized split-face clinical study. *Dermato Surg Round.* 2015;60(5):473-8.
22. Faghihi G, Keyvan S, Asilian A, Nouraei S, Behfar S, Nilforoushzadeh MA, et al. Efficacy of autologous platelet-rich plasma combined with fractional ablative carbon dioxide resurfacing laser in treatment of facial atrophic acne scars: A split-face randomized clinical trial. *Indian J Dermatol, Venereol, Leprol.* 2016;82(2):162.
23. Na JI, Choi JW, Choi HR, Jeong JB, Park KC, Youn SW, et al. Rapid healing and reduced erythema after ablative fractional carbon dioxide laser resurfacing combined with the application of autologous platelet-rich plasma. *Dermatol Surg.* 2011;37(4):463.
24. Sampson S, Gerhardt M, Mandelbaum B. Platelet rich plasma injection grafts for musculoskeletal injuries: a review. *Curr Rev Musculoskeletal Med.* 2008;1(3-4):165-74.
25. Marx RE. Platelet-rich plasma: Evidence to support its use. *J Oral Maxillofac Surg.* 2004;62:489-96.
26. Robiony M, Polini F, Costa F, Politi M. Osteogenesis distraction and platelet-rich plasma for bone restoration of the severely atrophic mandible: Preliminary results. *J Oral Maxillofac Surg.* 2002;60:630-5.
27. Shin MK, Lee JH, Lee SJ, Kim NI. Platelet-rich plasma combined with fractional laser therapy for skin rejuvenation. *Dermatol Surg.* 2012;38(4):623-30.
28. Mahindra P, Yamin M, Selhi HS, Singla S, Soni A. Chronic plantar fasciitis: Effect of platelet-rich plasma, corticosteroid, and placebo. *Orthopedics.* 2016;39(2):285-9.
29. Khoshbin A, Leroux T, Wasserstein D, Marks P, Theodoropoulos J, Ogilvie-Harris D, et al. The efficacy of platelet-rich plasma in the treatment of symptomatic knee osteoarthritis: a systematic review with quantitative synthesis. *Arthroscopy: J Arthroscopic Rel Surg.* 2013;29(12):2037-48.
30. Mishra A, Pavelko T. Treatment of chronic elbow tendinosis with buffered platelet-rich plasma. *Am J Sports Med.* 2006;34(11):1774-8.

**Cite this article as:** Shah SD, Mehta BD, Borkar MA, Aswani RC. Study of safety and efficacy of autologous platelet rich plasma combined with fractional CO<sub>2</sub> laser in the treatment of post acne scars: a comparative simultaneous split-face study. *Int J Res Med Sci* 2017;5:1344-51.