

## Case Report

# A peculiar case of dural venous sinuses with resulting atypical bony markings in posterior cranial fossa

Gitanjali Khorwal\*, Sunita Kalra

Department of Anatomy, University College of Medical Sciences, Delhi, India

**Received:** 20 March 2017

**Accepted:** 19 April 2017

**\*Correspondence:**

Dr. Gitanjali Khorwal,

E-mail: [gitanjalikhorwal@gmail.com](mailto:gitanjalikhorwal@gmail.com)

**Copyright:** © the author(s), publisher and licensee Medip Academy. This is an open-access article distributed under the terms of the Creative Commons Attribution Non-Commercial License, which permits unrestricted non-commercial use, distribution, and reproduction in any medium, provided the original work is properly cited.

### ABSTRACT

A paramedian or midline suboccipital approach for craniotomies and craniectomies is commonly employed for decompression or tumour resections from posterior cranial fossa. The reference for midline is taken as the line joining the nasion andinion on the surface of the skull which is the estimated position of superior sagittal sinus. In the interior, the internal occipital protuberance is the site of confluence of sinuses which presents a spectrum of variations. An unusual pattern of drainage of dural venous sinuses was observed at the site of customary confluence during routine dissection of head region for undergraduate medical students in a sixty-year-old female cadaver. The superior sagittal sinus continued as right transverse sinus as usual but it was connected to the left transverse sinus through a venous channel. There was no appreciable confluence of sinuses at this site. A prominent and atypical cerebellar process emerged from right hemisphere of cerebellum and projected between right transverse sinus and the venous channel connecting right and left transverse sinuses. In the posterior cranial fossa, the internal occipital crest was present on the left of midline separated from internal occipital protuberance. Another small ridge was present to the right of midline. A triangular fossa thus formed on the right side of internal occipital crest was occupied by the unusual prominent process emerging from the right hemisphere of cerebellum. Pre-operative assessment of dural venous sinuses is imperative before any surgical intervention especially around the confluence of the sinuses.

**Keywords:** Craniotomy, Dural venous sinus, Internal occipital crest, Superior sagittal sinus, Torcular herophili Transverse sinus

### INTRODUCTION

Dural venous sinuses are enclosed within dural septae that are formed by reflection of the endosteal and meningeal layers of dura mater covering the brain. These sinuses are lined by endothelium and are devoid of valves and muscular tissue in their walls. The dural folds present at the posterior cranial fossa comprise of falx cerebri, falx cerebelli and tentorium cerebelli. Falx cerebri lies in the sagittal plane and occupies the longitudinal fissure between the two cerebral hemispheres; attached to crista galli, frontal crest and lips of the groove alongside sagittal suture enclosing superior sagittal sinus (SSS). The posterior end of falx cerebri gains its attachment to

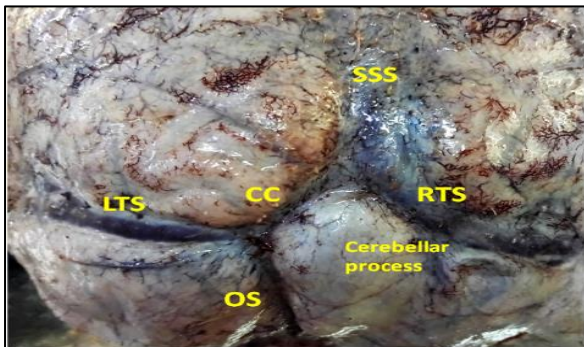
the internal occipital protuberance (IOP) where it joins the superior surface of tentorium cerebelli along a line enclosing the straight sinus. Tentorium cerebelli separates cerebellum from the occipital lobes of the cerebral hemispheres. Its free anterior border reaches forwards to attach to the anterior clinoid process leaving a gap for brainstem called tentorial incisure. The rest is attached to the apex and superior angle of petrous part of temporal bone, transverse groove on occipital bone reaches up to the internal occipital protuberance enclosing right and left transverse sinuses. The transverse groove is incessant with the sigmoid sulcus lodging sigmoid sinus on both the sides. The falx cerebelli projects forward between the two cerebellar hemispheres from undersurface of the

tentorium cerebelli. Its posterior end is attached to the internal occipital crest (IOC) and the protuberance enclosing occipital sinus.

These dural partitions facilitate to steady the brain within the cranial cavity and the enclosed sinuses form a confluence of sinuses at the IOP.<sup>1</sup> Usually the posterior part of SSS, IOP and IOC lie in the same line.<sup>2</sup> The confluence of sinuses is documented to be present only in 35% of dried skull specimens; the bifurcation of SSS to drain in bilateral transverse sinuses was seen in 14% and the commonest pattern of SSS draining into right transverse sinus was noted in 41%. The SSS draining into left transverse sinus was least common and observed in 10% of specimens.<sup>3</sup>

### CASE REPORT

An uncommon pattern of dural venous sinuses was observed in the posterior cranial fossa of a 60-year-old female cadaver in the department of Anatomy during routine dissection for teaching purposes for undergraduate medical students. The superior sagittal sinus continued as dominant right transverse sinus. It was connected to the left transverse sinus through a 2.6 cm long venous channel. The length of corresponding ridge on occipital bone was smaller as compared to this venous channel. There was no appreciable confluence of sinuses at this site. The occipital sinus was also deviated more to the left side from the midline and joined the left transverse sinus at the spot where the venous connection present between left and right transverse sinuses joined it (Figure 1).

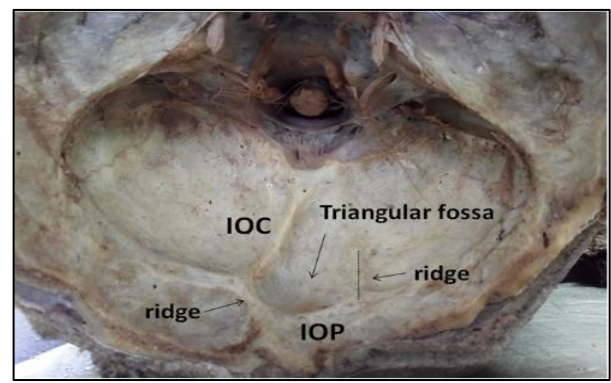


**Figure 1: Site of confluence of sinuses showing superior sagittal sinus (SSS) continuing as right transverse sinus (RTS). Left (LTS) and right transverse sinuses (RTS) connected by a connecting channel (CC).**

Alternately, it can also be stated that this venous channel is a bifurcation of SSS where the right limb is dominant and continuing as right transverse sinus and left limb which is smaller in caliber and is draining into left transverse sinus. A prominent and atypical cerebellar process was seen to be emerging from right hemisphere of cerebellum and was projecting between right transverse sinus and the venous channel connecting right

and left transverse sinuses. The cranial cavity of the same cadaver was explored after removing the cerebrum along with cerebellum and brain stem.

It was observed that in the region of posterior cranial fossa within the cranial cavity, internal occipital crest was present laterally more to left side and was heading towards the verian fossa and foramen magnum. This laterally placed internal occipital crest was separated from internal occipital protuberance by a ridge measuring 1.7 cm in length (Figure 2). Another small inconspicuous ridge was present to the right of midline at a distance of 3.7 cm from the commencement of internal occipital crest. A triangular fossa thus formed on the right side of IOC was occupied by the unusual prominent process emerging from the right cerebellar hemisphere with cerebellum in situ.



**Figure 2: Posterior cranial fossa showing laterally deviated internal occipital crest (IOC) separated from internal occipital protuberance (IOP) by a ridge. Another ridge present to the right bordering the triangular fossa thus formed.**

### DISCUSSION

Confluence of sinuses is a frequent site for variation in venous draining patterns investigated in the past to account for each type. In the present case, the SSS continued as right transverse sinus as usual but was also connected to the left transverse sinus. Ozen et al reported a bifurcation pattern of SSS on cranial venous magnetic resonance angiography (MRA) with dominant right limb.<sup>4</sup> In present case, however the caliber of connecting venous channel was very small as compared to the continuing channel as to call it a bifurcation. The variations in these patterns are attributed to the joining of venous connections between the two limbs of SSS during development.<sup>5</sup> Furthermore; the IOC was deviated to the left of the midline separated by IOP by a ridge. Also, there are some reports suggesting that non-alignment of IOC with IOP may be due to abnormality of cisterna magna.<sup>2</sup> It has even been hypothesized by Pozzati et al.<sup>6</sup> that brain pathologies like hydrocephalus may be a cause for anomalous IOC. In the present report, it is difficult to comment on this aspect because of absence of medical history. For initiating any surgery on brain, the reference

for midline is taken as the line joining the nasion and theinion on the surface of the skull.<sup>7</sup> This is the estimated position of the superior sagittal sinus. Inside the cranial cavity, it continues as internal occipital crest giving attachment to occipital sinus.

The position of IOC serves neurosurgical importance as burr holes are placed on either side of it in midline and paramedian incisions employed in suboccipital craniotomy/craniectomy for resecting tumours in posterior fossa.<sup>8</sup> In an event of deviated IOC as found in the present case, the attached occipital sinus may get injured accidentally and bleed which might have grave consequences. The underlying prominent atypical cerebellar process observed in this study also is prone to injury. The necessity of thorough knowledge to neurosurgeons, about the diverse patterns drainage at the confluence of sinuses does not need further emphasis. A complete assessment of dural venous sinuses is imperative before the surgery. The present case shall add on to spectrum of variations occurring at the region of confluence of sinuses and prevent any impairment during para-median and midline cranial approaches for surgical interventions especially when intra-operative image guidance is unavailable.

#### **Embryological basis**

During development of brain, the primary capillary plexus of head gets segregated in different layers; the deepest layer forms the venous plexus of dura mater. They differentiate into anterior, middle and posterior dural stems. A plexus of capillary veins, sagittal plexus is formed along the posterior margin of anterior and middle plexuses at the site of future falx cerebri which later approximate towards midline and form SSS from rostral end backwards.<sup>1</sup> The caudal part of SSS that arises from plexuses of veins can remain discrete and two limbs drain laterally to join the transverse sinus of each side or unite to form the confluence of sinuses. The vascular channels that connect the two limbs may produce the variations of confluence of sinuses after birth.<sup>5</sup> The two limbs usually unite in sixth fetal month.<sup>9,10</sup>

*Funding: No funding sources*

*Conflict of interest: None declared*

*Ethical approval: Not Required*

#### **REFERENCES**

- Dutta AK. Introduction to skull. In: Dutta AK, eds. Essentials of Human Anatomy Head and neck Part II. 3rd ed. Calcutta: Current Books International; 1999:1-69.
- Mwachaka PM, Hassanali J, Odula P. Sutural morphology of the pterion and asterion among adult Kenyans. Braz J Morphol Sci. 2009;26(1):4-7.
- Singh R. Incidence of sutural bones at asterion in adult Indian skulls. Int J Morphol. 2012;30(3):1182-6.
- Day JD, Kellog JX, Tschabitscher M, Fukushima T. Surface and superficial surgical anatomy of the posterolateral cranial base: significance for surgical planning and approach. Neurosurgery. 1996;38(6):1079-84.
- Uz A, Ugur HC, Tekdemir I. Is the asterion a reliable landmark for the lateral approach to posterior fossa?. J Clin Neurosci. 2001;8(2):146-7.
- Martinez F, Laxague A, Vida L, Prinzo H, Sgarbi N, Soria VR, et al. Anatomia topografica del asterion. Neurocirurgia. 2005;16(5):441-6.
- Leon SG, Rodriguez AN, Avalos RM, Theriot Giron M, Omana REE, Lopez SG. Morphometric characteristics of the asterion and the posterolateral surface of the skull: relationship with dural venous sinuses and neurosurgical importance. Cir Cir. 2013;81:251-5.
- Berry AC, Berry AJ. Epigenetic variation in the human cranium. J Anat. 1967;101(Pt 2):361-79.
- Kellock WL, Parson PA. A comparison of the incidence of minor nonmetrical cranial variants in Australian aborigines with those of Melanesia and Polynesia. Am J Phys Anthropol. 1970;33(2):235-40.
- Gumusburun E, Sevim A, Katkici U, Adiguzel E, Gulec E. A study of sutural bones in Anatolian Ottoman skulls. Int J Anthropol. 1997;12(2):43-8.
- Saheb HS, Mavishettar GF, Thomas ST, Prasanna LC, Muralidhar LC, Muralidhar P, Magi. A study of sutural morphology of the pterion and asterion among human adult Indian skulls. Biomed Res. 2011;22(10):73-5.
- Sudha R, Sridevi C, Ezhilarasi M. Anatomical variations in the formation of pterion and asterion in south Indian population. Int J Cur Res Rev. 2013;5(9):92-100.
- Ucerler H, Govsa F. Asterion as asurgical landmark for the lateral cranial base approaches. J Craniomaxillofac Surg. 2006;34(7):415-20.
- Xia Y, Li X, Han D, Zheng J, Long H, Shi J. Anatomic structural study of cerebellopontine angle via endoscope. Chin Med J. 2007;120(20):1836-9.
- Suazo GIC, Zavando MDA, Smith RI. Sex determination using mastoid process measurements in Brazilian skulls. Int J Morphol. 2008;26(4):941-4.
- Mwachaka PM, Hassanali J, Odula P. Anatomic position of the asterion in Kenyans for posterolateral surgical approaches to cranial cavity. Clin Anat. 2010;23(1):30-3.
- Selman MO. Metric study of the sigmoid sinus plate in relation to suprameatal (Macewan's) triangle. Iraqi J Med Sci. 2011;9(1):86-91.

**Cite this article as:** Khorwal G, Kalra S. A peculiar case of dural venous sinuses with resulting atypical bony markings in posterior cranial fossa. Int J Res Med Sci 2017;5:2830-2.