

Original Research Article

Diagnostic spectrum of CSF involvement by malignant cells: three-year experience of tertiary care hospital in CSF cytology

Vandana Rana*, Avnit Sidhu, Rajat Jagani, Giriraj Singh, Rajeshwar Singh, K. R. Rathi

Department of Pathology, Command Hospital (South Command), AFMC, Pune, Maharashtra, India

Received: 27 March 2017

Accepted: 27 April 2017

*Correspondence:

Dr. Vandana Rana,

E-mail: drvandanarana@gmail.com.

Copyright: © the author(s), publisher and licensee Medip Academy. This is an open-access article distributed under the terms of the Creative Commons Attribution Non-Commercial License, which permits unrestricted non-commercial use, distribution, and reproduction in any medium, provided the original work is properly cited.

ABSTRACT

Background: Cerebrospinal fluid (CSF) cytology is the diagnostic gold standard test for primary or metastatic involvement of central nervous system (CNS) by malignancy. It is a very important and routinely done test in the laboratory but its sensitivity is low due to many confounding factors and varies amongst type of malignancies. We did retrospective analysis of CSF cytology carried out at our center from January 2013 to December 2015 to find out about spectrum of malignancies being detected on CSF cytology.

Methods: From January 2013 to December 2015, three hundred and seventy-five CSF samples were received and processed for presence of malignant cells at our center. The cytospin preparations stained with LG and PAP stains of these CSF samples were analyzed along with any special stain that was available in the records. Clinical details of the patients with positive cytology were correlated from records.

Results: The diagnostic spectrum obtained through study of positive CSF cytology included cases of metastatic solid malignancies and hematolymphoid malignancies. Four cases out of ten were of Metastatic Adenocarcinoma with primary origin being Breast, Lung and Stomach. Out of six cases of hematolymphoid malignancies; five were known cases of lymphoma/leukemia and one was primarily diagnosed to have Non-Hodgkin's lymphoma (NHL) on CSF cytology.

Conclusions: Both Epithelial and Hematolymphoid malignancies can be diagnosed on CSF cytology and these are predominantly metastatic in origin; Hematolymphoid malignancies are more common in CSF than solid malignancies. Correlation with clinical details and Neuroimaging is a must.

Keywords: Adenocarcinoma, Cerebrospinal fluid cytology, CNS, Hematolymphoid malignancies, Metastatic

INTRODUCTION

Cerebrospinal fluid (CSF) analysis is the window to Central Nervous system (CNS). The spread of cancer in CNS leads to increased morbidity and rapid mortality. Improvement in systemic therapies for cancer and its failure to penetrate the blood- brain barrier has made CNS as common site for disease involvement and recurrence.^{1,2} Many newer techniques like IHC, Flow cytometry, PCR, Proteomic analysis etc. are proving to be useful adjunct to conventional cytology however, CSF cytology is still the diagnostic gold standard test for

primary or metastatic involvement of CNS by malignancy.³⁻⁵ We report our experience of CSF cytology and spectrum of diagnosed cases in our centre over last three years.

METHODS

The present study is a retrospective descriptive study. All the CSF samples received at our center between January 2013 to December 2015 for cytology were independently reviewed by two pathologists. The cytospin preparations stained with LG and PAP stains of these CSF samples

were analyzed along with any special stain that was available in the records. Biochemical tests of CSF samples and clinical details of the patients with positive cytology were correlated from records. The results of CSF analysis in follow-up cases of acute lymphoblastic leukemia (ALL) for evidence of CNS involvement are not included in this study.

RESULTS

The common indications for CSF cytology included meningitis, pyrexia of unknown origin, altered sensorium, headache, carcinomatous meningitis or metastatic solid malignancies, lymphoma/ leukemia and cases of immune surveillance. The details and distribution of CSF samples received in our center over three years are depicted in Table 1.

Table 1: Distribution of CSF samples received over three years.

Year	2013	2014	2015	Total
No. of CSF sample for malignant cell examination	116	135	124	375
CSF for blast in follow up cases of ALL	39	47	45	131
Remaining CSF Sample for Malignant cell	77	88	79	244
Sample positive for malignant cell	12	08	15	35
No. of new cases detected	04	02	04	10

Out of 375 samples of CSF, one hundred thirty-one were for presence of Blasts in follow up cases of ALL. Due to established regimen of CNS prophylaxis in cases of ALL, two cases on follow up showed presence of atypical cells. Out of remaining 244 CSF samples, thirty-five CSF samples were positive for malignant cells.

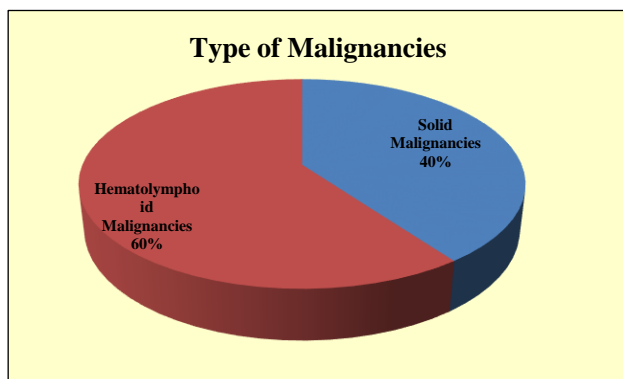


Figure1: Distribution of type of malignancies in positive CSF samples.

Repeat CSF samples of same patients were received twice or thrice, either for confirmation of involvement or for monitoring of the therapy. Total ten cases of malignancies with involvement of CSF were diagnosed over three years on cytology. Out of ten positive cases, four were of Metastatic Adenocarcinoma and six cases were of Hematolymphoid malignancies (Figure 1).

The clinicopathological features of cases positive for malignant cells on CSF cytology are summarized in Table 2. The youngest patient diagnosed in this series is 35 years old while the oldest being 79 years. Out of ten positive cases eight are of males. The biochemical analysis of these positive CSF samples revealed raised protein levels and reduced levels of sugar. Cases of Metastatic Adenocarcinoma had primaries in Breast, Lung and Stomach. The six cases of hematolymphoid malignancies comprise one case of Primary CNS Lymphoma (PCNSL) and rest five were known cases of lymphoma/leukemia.

Short clinical history of few representative cases is given underneath-

Solid malignancies

Case 1

46 years old male, a known case of metastatic lung Adenocarcinoma on follow since 2012 was found to be positive for malignant cells on CSF Cytology. MRI Brain revealed extensive leptomeningeal deposits (Figure 2a).

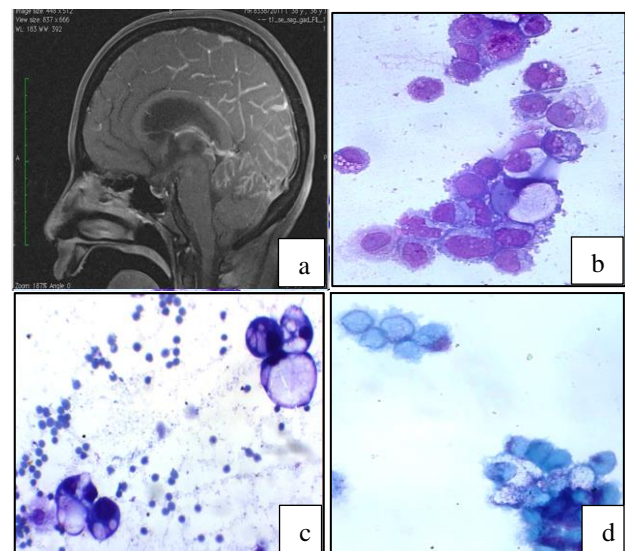


Figure 2: a) MRI image demonstrates leptomeningeal enhancement in relation to the cerebellum, surface of brainstem and parieto-occipital regions; suggestive of metastases; b) Dyscohesive clusters of atypical cells of adenocarcinoma seen; c) Adenocarcinoma cells with signet ring like morphology; d) Intracytoplasmic mucin demonstrated by mucicarmine stain.

Patient had initially presented with complaints of generalized headache not associated with nausea or vomiting. All systemic examination and basic investigations were within normal limits. MRI brain revealed altered marrow signal abnormality with expansion of clivus associated with isointense soft tissue on right side extending in cavernous sinus.

An initial suspicion of Clival chordoma was entertained. The patient underwent near total excision of the lesion in Oct 2012 which on histopathology was reported as Metastatic deposits of Adenocarcinoma.

Whole body PET scan revealed hyper metabolic soft tissue lesion in right lung along with multiple vertebral metastasis. Patient was put on chemotherapy cycles comprising of Inj Paclitaxel/Cisplatin/Zoledronic acid. Patient was on active follow up and had limited disease free period. CSF cytology was positive for malignant cells of Adenocarcinoma (Figure 2b).

Case 2

46 Years old male, a diagnosed case of Poorly differentiated Adenocarcinoma of stomach (PT2N2) since Dec 2014. On follow up he developed persistent headache few months after radical gastrectomy. MRI Brain was suggestive of carcinomatous meningitis. CSF cytology was positive for cells of Adenocarcinoma. Intracytoplasmic mucin positivity was demonstrated by Mucicarmin stain (Figure 2d).

Hematolymphoid malignancies

Case 1

79 Years old male, a known case of Chronic Myeloid Leukemia (CML) on follow-up since 2009, presented with complaints of headache and generalized weakness in 2014 with no neurological deficit. Patient was on treatment with Tablet Imatinib. Hemogram revealed TLC 800/ cumm and platelet 50,000/cumm with no blasts in peripheral blood. Lumbar puncture was done and CSF examination showed increased cellularity with predominant presence of Blasts of Lymphoid morphology (Figure 3a). The blasts were MPO negative. Bone marrow studies did not reveal increased blasts or immature cells. A diagnosis of CML with isolated CNS blast crisis was made and patient was treated with triple intrathecal chemotherapy and cranial radiotherapy (RT).

Case 2

45 years old male presented in 2013 with complaints of on and off headache and vomiting of 15-20 days' duration. There was no history of fever, loss of consciousness or trauma. On examination, he had signs of raised intracranial tension. All laboratory examination was within normal limits and patient was negative for HIV test. MRI brain revealed a homogeneous hyper

intense enhancing mass in the splenium of corpus callosum abutting the ventricular surface suggestive of PCNSL (Figure 3c). CSF examination revealed increased cellularity with altered biochemistry.

Atypical large lymphoid cells were seen scattered amongst reactive cells on cytology. Patient's workup for systemic lymphoma was negative. He underwent craniotomy and debulking of tumor. Histopathology and IHC confirmed the lesion to be high grade B-Cell Non-Hodgkin's Lymphoma (NHL). Patient was treated with high dose Methotrexate followed by radiotherapy.

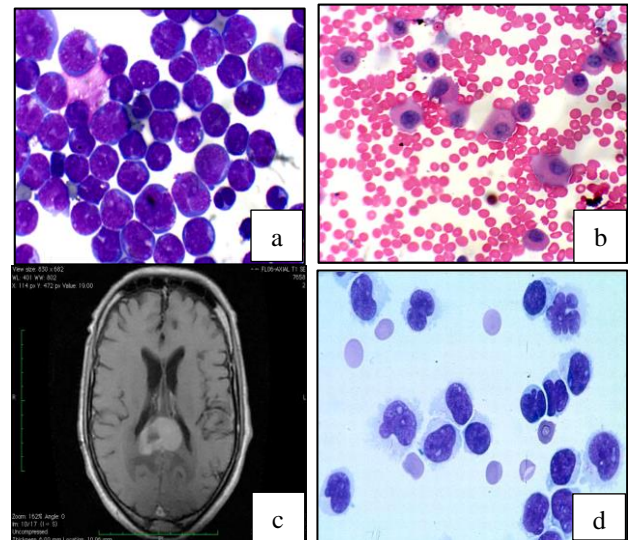


Figure 3: a) Population of blastic cells with nuclear indentations; b) Atypical and immature plasma cells. 3c) MRI image showing a homogeneous hyper intense enhancing mass in the splenium of corpus callosum abutting the ventricular surface, suggestive of primary CNS Lymphoma; 3d) Singly scattered atypical lymphoid cells with prominent nuclear indentations.

Case 3

35 years old female presented in Mar 15 with vague abdominal pain and was diagnosed to have a huge abdomino-pelvic mass on USG measuring approximately 11x9x5cms, probably ovarian in origin.

All the tumor markers including CA 125 were within normal limits. Histopathology of excised mass suggested a diagnosis of Burkitt Lymphoma.

However, the IHC studies confirmed it to be high grade B-Cell Grey Zone lymphoma with features intermediate between Diffuse Large B-Cell Lymphoma (DLBCL) and Burkitt Lymphoma (CD 20, Bcl2, Bcl6 positive; CD10, CD3 Negative; MIB index 70-75%).

The patient had extra nodal involvement and in few months patient also developed breast and CNS

involvement. CSF examination was positive for atypical, immature lymphoid cells (Figure 3d). Patient was given

intrathecal treatment along with 8 # R-CHOEP and presently is in complete remission.

Table 2: Clinicopathological features of cases positive for malignant cells on CSF cytology.

Sex	Age (year)	Diagnosis	Year of primary diagnosis	CNS metastasis	CNS symptoms	CSF cytology
M	46	Lung ca	2012	2013	Headache	Cells of adenocarcinoma
F	63	Ductal ca breast	2008	2013	Nil	Cells of adenocarcinoma
M	70	Lung ca	2013	2015	Diplopia, partial loss of sensation face	Cells of adenocarcinoma
M	46	Ca stomach	2013	2014	Headache	Cells of adenocarcinoma
M	79	CML	2009	2013	Headache, weakness	Lymphoblasts
M	52	Multiple myeloma	2012	2014	Headache, confusion	Plasmablasts and atypical plasma cells
M	46	Multiple myeloma	2013	2015	Diminution of vision, ophthalmoplegia	Plasmablasts and atypical plasma cells
M	65	NHL, Mantle cell	2014	2015	Headache, vomiting	Atypical, large lymphoid cells
M	45	PCNSL	2013	2013	Headache, vomiting	Atypical, large lymphoid cells
F	35	NHL extranodal	2015	2015	Nil	Atypical, large lymphoid cells

DISCUSSION

In present study of retrospective analysis of CSF cytology for malignant cells, the diagnostic spectrum obtained comprised predominantly of Metastatic malignancies (09/10). This is in concordance with all the larger CSF series published earlier by Mackenzie, Prayson and Fischer, Gupta and Chamberlain which established that the main tumor types diagnosed in CSF are metastases from solid malignancies or Lymphoma and Leukaemia.⁶⁻⁹ Lung and breast Adenocarcinoma and Melanoma were found to be the commonest solid tumors in above mentioned series. Leptomeningeal disease from other tumors, such as GIT, bladder, kidney, female genital tract and prostate can occur.

Leptomeningeal metastasis is seen in approximately 5% of patients with solid tumors and around 10% in hematology cases.¹⁰ In the present study out of ten cases, four were cases of metastatic Adenocarcinoma and remaining six cases showed involvement of CSF by lymphoma or leukemia. Adenocarcinoma is the most common cytology found in CSF in cases of metastatic solid malignancies.¹⁰ Usually single or small clusters of intact or degenerated atypical cells are seen on cytology. CSF smears positive for Adenocarcinoma in our study revealed dyscohesive atypical large cells with pleomorphic nuclei, coarse chromatin and prominent nucleoli. The cytoplasmic vacuolisation and intra cytoplasmic mucin was seen (Figure 2b and 2c). Many

cells had frilly or ruffled cytoplasmic borders.¹¹ Signet ring like morphology was also appreciated. Out of four Adenocarcinoma cases in our series, two were metastasis from lung carcinoma and other two were from stomach and breast. Special mucin stains like Mucicarmine was used to demonstrate intra cytoplasmic mucin in one of our cases (Figure 2d).

Cell yield in CSF is usually poor in cases of leptomeningeal carcinomatosis and may require repeated CSF examination in suspected cases for confirmation as found in many CSF studies and was also observed in present study. The diagnostic accuracy of CSF cytology increases with analysis of consecutive samples.¹² IHC and Cytogenetic techniques such as FISH can prove helpful in detection of metastatic malignant cells in CSF.¹³ Haematological malignancies such as Leukaemia and Lymphomas frequently involve the CNS, forming between 11% and 40% of all malignant CSFs.^{7,8,14} Meningeal leukaemia or lymphoma often arise in a patient as secondary involvement in a known case or rarely as PCNSL. The five positive cases of hematology malignancies in our study were known systemic cases and one case presented primarily with CNS involvement. Out of six cases, three were of high grade NHL, Two of Multiple myeloma and one of CML.

NHL involving the leptomeninges is usually high grade tumors; low grade lymphoma and Hodgkin's lymphoma are significantly less common.^{7,14-16} High grade tumors like DLBCL (Systemic or primary), Burkitt's lymphoma,

lymphoblastic lymphoma or Mantle cell lymphoma are more common causes of Lymphomatous meningitis.^{7,14,15} Atypical lymphoid cells with sharp nuclear notches, irregular cytoplasm and increased size are suggestive of lymphoma on cytology.¹⁷ Both our cases of systemic NHL with leptomeningeal involvement were high grade lymphomas and the CSF cytology revealed population of atypical large, immature lymphoid cells, with prominent nucleoli, abnormal chromatin and irregular nuclear contours (Figure 3d).

One of the cases of hematolymphoid malignancies turned out to be PCNSL in our study. PCNSL accounts for only 1-5% of all primary brain tumors and is mainly DLBCL; less commonly it could be Burkitt's lymphoma or T cell lymphoma.¹⁸ The malignant cells on CSF cytology can be seen only in about 24% of the patient of CNS lymphoma though sensitivity of CSF cytology varies from 2% to 32%.¹⁹ CSF cytology in our case revealed large, atypical lymphoid cells with few showing mitotic activity. The diagnosis of B cell PCNSL was later confirmed on histopathology and IHC. Our patient of PCNSL was immunocompetent though these cases are more common in immunocompromised patients.²⁰

The CSF cytology in the patient of CML who was in haematological remission corroborated with isolated CNS Blast crisis. (Figure 3a). The CNS acts as the sanctuary site for malignant cells in CML patients due to poor penetration of CNS by systemic therapy comprising of selective inhibitor of BCR-ABL tyrosine kinase.^{21,22} CNS as a site for extramedullary blast crisis is very rare in CML.²² In 20-30% cases of blast crisis in CML, the blast lineage is lymphoid as was confirmed on flow cytometry in our case.²³

CNS involvement in Multiple myeloma is considered very rare. The large series of MM patients studied by Schluterman et al found leptomeningeal involvement in just 1.1% of cases.²⁴ Detection of malignant plasma cells in the CSF is considered the hallmark of the diagnosis.²⁵ However, evidence from literature suggests that plasma cells may be absent in few cases of MM with CNS involvement and frequent CSF examinations are recommended.²⁴ In present study, CSF in both cases of MM revealed presence of many atypical and immature plasma cells (Figure 3b). Protein electrophoresis, Beta 2 microglobulin assay and flow cytometry of CSF can help in suspected case of CNS involvement with MM. CSF flow cytometry is a useful adjunct to cytological examination in detection of malignant hematopoietic cells particularly in CSFs with low cell counts.^{15,26} In present study, the youngest patient diagnosed was 35 years old and the oldest 79 years old. Usually patients of ALL belong to younger age group but that subset is excluded from our study; secondly CSF cytology is not frequently positive in primary CNS malignancies as also seen in present study. Most of the diagnosed cases are of Metastatic disease seen in middle to elderly age group. Out of ten positive cases in present study eight are of

males however, due to limited numbers it is not statistically significant.

CSF examination for tumor cells has moderate sensitivity and high specificity of approximately 97-98%.²⁷ Sensitivity depends on the type of tumor. CSF examination of the leukemic patient has highest sensitivity of about 70%, followed by metastatic carcinoma (20-60%) and primary CNS malignancies (30%).²⁷ In present series no case of primary CNS tumor was diagnosed or detected on CSF analysis. Primary CNS Tumors are known to form only 10-20% of positive CSF Specimens.¹¹

Most of the primary CNS tumor has propensity to infiltrate the brain parenchyma over Leptomeningeal spread. Some tumors such as Ependymomas, Embryonal tumors, germ cell tumors and pineal tumors have predilection to seed through the CSF. False positive result in CSF is very uncommon as compare to false negative.⁶ False negative rates can be reduced by quick processing of the CSF and the examination of larger volume of CSF.^{11,28} Correlation with clinical details and Neuroimaging is a must.

CONCLUSION

The main tumor types diagnosed on CSF cytology are metastatic malignancies. Hematolymphoid tumors more commonly involve CSF than metastatic solid malignancies. Amongst carcinomas, Metastatic Adenocarcinoma is more common. Clinical and Neuroimaging correlation is a must for a complete CSF analysis. CSF cytology should be given due importance and repeat examination should be performed wherever required. Modern techniques can act as useful adjunct and should be used if available.

Funding: No funding sources

Conflict of interest: None declared

Ethical approval: The study was approved by the Institutional Ethics Committee

REFERENCES

1. Drappatz J, Batchelor T. Leptomeningeal metastasis. American society of clinical oncology educational book. 2009;100- 5.
2. Leal T, Chang JE, Mehta M, Ian Robin H. Leptomeningeal metastasis; Challenges in Diagnosis and Treatment. *Curr Cancer Ther Rev.* 2011;7(4):319- 27.
3. Scott BJ, Douglas VC, Tihan T, Rubenstein JL, Josephson SA. A systematic approach to the diagnosis of suspected central nervous system lymphoma. *JAMA Neurol* 2013;70(3):311-19.
4. Chamberlain MC, Glantz M, Groves MD, Wilson WH. Diagnostic tools for neoplastic meningitis: Detecting disease, identifying patient risk and

- determining benefit of treatment *Semin Oncol.* 2009;36(4 Suppl 2):S35-45.
5. Brem SS, Bierman PJ, Brem H, Butowski N, Chamberlain MC, Chiocca EA, et al. National Comprehensive cancer Network, Central Nervous system. *J Natl Compr Canc Netw.* 2011;9(4):352-400.
 6. Mackenzie JM. Malignant meningitis: A rational approach to cerebrospinal fluid cytology. *J Clin Pathol* 1996 ;49(6):497-99.
 7. Prayson RA, Fischler DF. Cerebrospinal fluid cytology; an 11- year experience with 5951 specimens. *Arch Pathol Lab Med.* 1998;122(1):47-51.
 8. Gupta RK, Naran S, Lallu S, Fauck R. Cytodiagnosis of neoplasms of the central nervous system in cerebrospinal fluid samples with an application of selective immunostains in differentiation. *Cytopathology.* 2004;15(1):38-43.
 9. Chamberlain MC. Neoplastic meningitis. *Neurologist* 2006;12(4):179- 87.
 10. Joshi A, Ghosh J, Noronha V, Parikh PM, Prabhaskar K. Leptomeningeal metastasis in solid tumors with a special focus on lung cancer. *Indian J Cancer* 2014; 51(4):410- 13.
 11. Galloway M, Thom M. Brain and cerebrospinal fluid. In Gray W, Kocjan G. *Diagnostic Cytopathology.* 3rd ed. Churchill Livingstone Elsevier. 2010:845-53.
 12. Bae YS, Cheong JW, Chang WS, Kim S, Oh EJ, Kim SH. Diagnostic accuracy of cerebrospinal fluid(CSF) cytology in metastatic tumors: An analysis of consecutive CSF samples. *Korean J Pathol.* 2013;47(6):563-68.
 13. Van Oostenbrugge RJ, Hopman AH, Lenders MH, Van Heerde P, Arends JW, Ramaekers FC, et al. Detection of malignant cells in cerebrospinal fluid using fluorescence in situ hybridization. *J Neuropathol Exp Neurol* 1997;56(6):743-48.
 14. Bigner SH. Cerebrospinal fluid cytology: Current status and diagnostic applications. *J Neuropathol Exp Neurol* 1992;51(3):235-45.
 15. Roma AA, Garcia A, Avangnina A, Rescia C, Elser B. Lymphoid and myeloid neoplasms involving cerebrospinal fluid: comparison of morphologic examination and immunophenotyping by flowcytometry. *Diagn Cytopathol.* 2002;27(5):271-75.
 16. Walts AE. Cerebrospinal fluid cytology: Selected issues. *Diagn Cytopathol.* 1992;8(4):394.
 17. Perske C, Nagel I, Nagel H, Strik H. CSF cytology- the ongoing dilemma to distinguish neoplastic and inflammatory lymphocytes. *Diagnostic Cytopathol* 2011;39(8):621-26.
 18. Gerstner RE, Batchelor TT. Primary central nervous system lymphoma: Neurological Review. *Arch Neurol.* 2010;67(3):291-97.
 19. Yoshida S, Morii K, Watanabe M, Saito T. Characteristic features of malignant lymphoma with central nervous system involvement. *Surg Neurol.* 2000;53(2):163-67.
 20. Kasamon YL, Ambinder RF. AIDS-related primary central nervous system lymphoma. *Hematol Oncol Clin North Am* 2005;19(4):665-87.
 21. Kim HJ, Jung CW, Kim K, Ahn JH, Kim WS, Park K, et al. Isolated blast crisis in CNS in a patient with chronic myelogenous leukemia maintaining major cytogenetic response after Imatinib. *J Clin Oncol.* 2006;24(24):4028-29.
 22. Narayan R, Mishra M, Mohanty R, Baisakh RM, Mishra DK. Central Nervous System blast crisis in chronic myeloid leukemia on Imatinib Mesylate therapy: Report of two cases. *Indian J Hematol Blood Transfus.* 2011;27(1):51-4.
 23. Vardiman JW, Melo JV, Baccarani M, Thiele J. Chronic myelogenous leukemia, BCR-ABL1 positive. In: Swerdlow SH, Campo E, Harris NL, Jaffe ES, Pileri SA, Stein H, et al editors. *WHO Classification of tumours of hematopoietic and lymphoid tissues* 4th ed. 2008:32-37.
 24. Schalterman KO, Fassas ABT, Van Hemert RL, Harik SI. Multiple myeloma invasion of the central nervous system. *Arch Neurol.* 2004;61(9):1423-29.
 25. Grossman SA, Krabak MJ. Leptomeningeal carcinomatosis. *Cancer treatment reviews.*1999;13: 259-61.
 26. Bromberg JE, Breems DA, Kraan J, Bikker G, van der Holt B, Smitt PS, et al. CSF flow cytometry greatly improves diagnostic accuracy in CNS hematologic malignancies. *Neurology.* 2007;68(20): 1674-79.
 27. Kinght JA, Kjeldsberg CR. Cerebrospinal, Synovial and serous body fluids. In: Macpherson RA, Pincus MR, editors. *Henry's clinical Diagnosis and management by laboratory methods.* 21st ed. Saunders. 2007:426-36.
 28. Glantz MJ, Cole BF, Glantz LK, Cobb J, Mills P, Lekos A, et al. Cerebrospinal fluid cytology in patients with cancer: Minimizing false-negative results. *Cancer.* 1998;82(4):733-39.

Cite this article as: Rana V, Sidhu A, Jagani R, Singh G, Singh R, Rathi KR. Diagnostic spectrum of CSF involvement by malignant cells: three-year experience of tertiary care hospital in CSF cytology. *Int J Res Med Sci* 2017;5:2575-80.